

SEPTIC PULMONARY EMBOLI FOLLOWING INFECTION OF PERIPHERAL INTRAVENOUS CANNULA

*Fatma Fidan¹, Murat Acar², Mehmet Unlu¹, Zafer Cetinkaya³, Alpay Haktanir²
Murat Sezer¹*

Afyon Kocatepe University Faculty of Medicine, Department of Pulmonary Medicine¹,
Radiology² and Microbiology³, Afyon, Turkey

A 54 year-old male admitted to our hospital with sudden onset shortness of breath, chest and back pain, weakness, and fever. Chest radiography and CT examination revealed consolidations and nodular densities 1-2 cm sized in both lungs. Swelling and redness were noticed in the dorsal aspect of patients' right hand where intravenous route had been done. We, therefore, diagnosed septic pulmonary embolism secondary to peripheral intravenous cannula. The patient's status was significantly improved after the antibiotic treatment

Key words: Septic pulmonary emboli, CT, radiography, intravenous cannula

Eur J Gen Med 2006; 3(3):132-135

INTRODUCTION

Septic pulmonary emboli are rare but important complications in patients with septicemia due to bacterial endocarditis, infected central venous catheters, odontogenic infections, septic thrombophlebitis, and prosthetic vascular devices (1-4). Typically, patients present with fever, cough, and hemoptysis (5). Septic pulmonary embolus resulting from peripheral intravenous cannula is an extremely rare condition which, to our knowledge, was reported only in one case previously (6). We present a case with septic embolus originated from a peripheral intravenous cannula.

CASE

A 54 years-old builder admitted to our hospital with sudden onset of shortness of breath, chest and back pain, weakness, and fever. He had been hospitalized for 2 weeks in another hospital for hypertension. He suffered from cough and was not able to expectorate. He has been smoking 30 packs per year and never used alcohol. In physical examination, blood pressure was 200/140 mmHg, pulse rate was 120/min, number of breaths was 28/min, and body temperature was 38.5°C. He seemed

dyspneic and tachypneic. Decreased breath sounds and dull percussion were detected in the base of the right lung. Other system examinations were normal. Laboratory findings were as follows: Hemoglobin: 11.2 g/dl, Hematocrit: 33.6%, white blood cell: 33.900/mm³, platelet: 367.000/mm³, Lactate Dehydrogenase: 722 U/L, and other biochemical parameters were normal. Erythrocyte sedimentation rate was 83 mm/hour. A broad pleural-based consolidated area in the mid-zone of right lung, linear densities consistent with subsegmental atelectasis, and right pleural effusion were detected in plain chest radiography. Besides, an obscure, peripherally located consolidated area was seen in the upper zone of left lung (Figure 1a). In thoracic computed tomographic (CT) examination, well demarcated consolidations were detected in the posterior segment of right upper lobe and in the apicoposterior segment of left upper lobe (Figure 3 a,b). In addition, a few 1-2 cm sized nodular densities were determined in both lungs. Swelling and redness were noticed in the dorsal aspect of patients' right hand where an intravenous route had been inserted (Figure 2). It was learned from the patient's history that this lesion was bigger when he was in hospital for

Correspondence: Fatma Fidan
Hattat Karahisar Mah. 4. Sokak Kaya Apt D:7
Afyonkarahisar, Turkey
Tel: 902722143355-158, Fax: 902722144996
E-mail : drffidan@yahoo.com

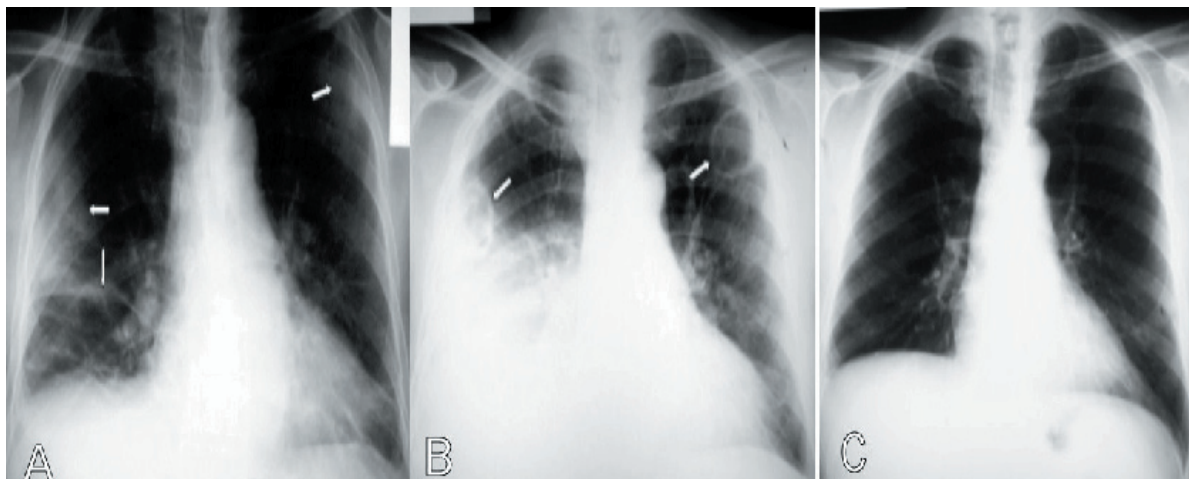


Figure 1. A. Bilateral pleural-based consolidated areas in the mid-zone of the right and upper zone of the left lung (thick arrows), linear densities consistent with subsegmental atelecthesis (thin arrow), and right pleural effusion are seen in plain chest radiography. B. Distinct cavities and increased pleural effusion on chest radiography taken at the fifth day of treatment (arrow). C. Cavitory lesions or consolidations and right pleural effusion was completely disappeared at control radiography of second month.

hypertension and decreased in size with oral antibiotic treatment. These findings suggested septic pulmonary embolus and intravenous 4x1.5 gr of Sulbactam-ampicillin was initiated. Blood culture was taken. No vegetation was observed in echocardiography. The patient's status was significantly improved after the antibiotic treatment; however fever persisted at the fourth day of antibiotic treatment. At the fifth day of treatment, cavities were more distinctly visible and the pleural effusion was increased on chest radiography (Figure 1b). Bilateral, pleural based, relatively thick walled, two cavitory lesions of 3 centimeters in diameter and pleural effusion - massive in

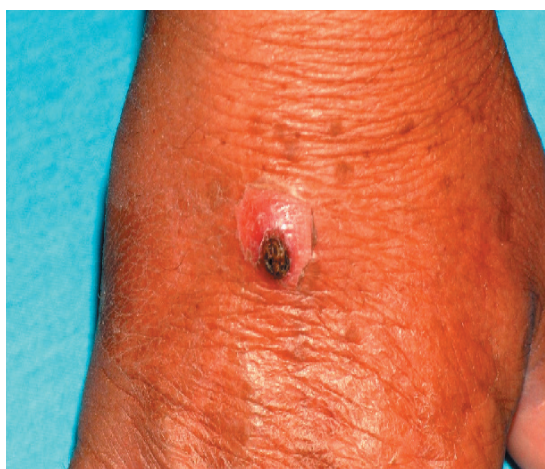

Figure 2. Swelling and redness in the dorsal aspect of patients' right hand where intravenous route had been done.

the right and minimal in the left - were seen on thorax CT (Figure 3 c,d). Thoracentesis was performed because of persistent fever and increasing right pleural effusion. Biochemical and microbiologic examinations of pleural fluid were not suggestive of empyema. After the sixth day fever was ceased. No reproduction was detected in blood and pleural fluid cultures. Antibiotic treatment was administered for 6 weeks. At the control radiography and CT of second month, no cavity or consolidation was detected, and right pleural effusion was completely disappeared (Figure 1c and Figure 3 e,f).

DISCUSSION

Bacterial endocarditis of the right heart, septic thrombophlebitis, central catheter and periodontal diseases are common sources of emboli (1-4). However, as far as we know, only one case of septic pulmonary embolus following peripheral intravenous cannula thrombosis which had fatal course was reported in the English language literature (6). Contrary to that case our patient showed complete recovery. Early diagnosis and prompt antibiotic therapy are very important in patients with septic pulmonary emboli. However, septic pulmonary emboli are often difficult to diagnose in the absence of a heart murmur or a positive blood culture (7). In our case, blood culture was negative and this was considered to be related with previous antibiotic treatment administered before the patient admitted to our hospital.

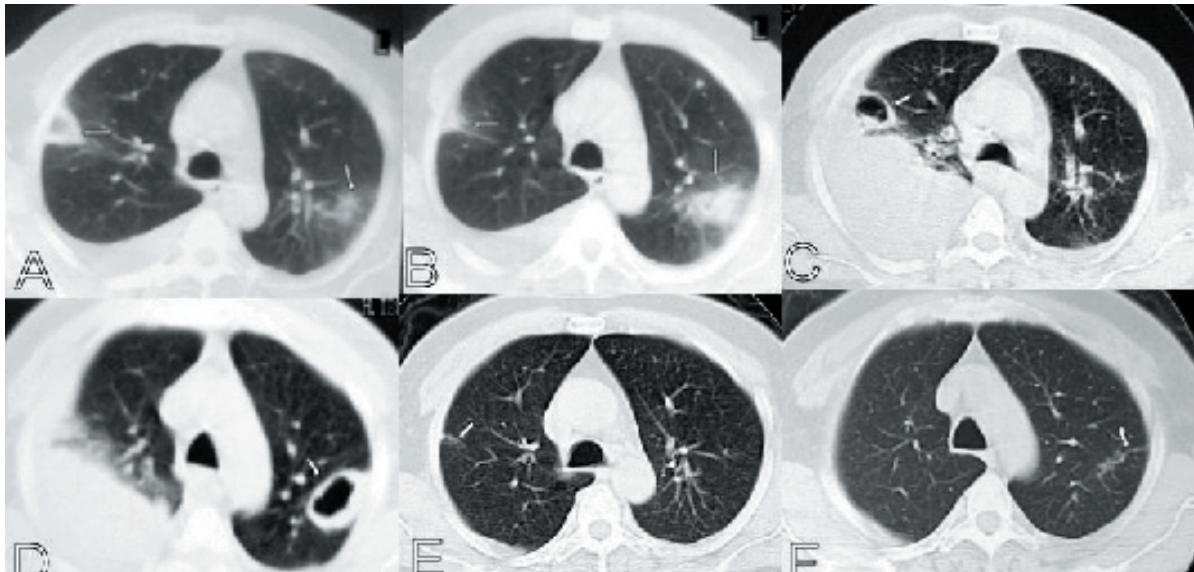


Figure 3. A, B. In thorax CT examination, well demarcated consolidations are seen in the posterior segment of right upper lobe and in the apicoposterior segment of left upper lobe. C, D. Two cavitary lesions and massive pleural effusion in the right and minimal in the left were detected at the fifth day of treatment. E, F. At the control CT of second month, no cavity or consolidation was detected, and right pleural effusion was completely disappeared. Only bilateral sequel changes can be seen.

Although chest radiographic characteristics of septic pulmonary emboli have been well documented, most findings are nonspecific or equivocal. Chest radiographs reveal peripheral bilateral poorly marginated lung nodules that have a tendency to form cavities with moderately thick irregular walls. Nodules generally range in size from 1 to 3 cm and may increase in number or change in appearance (size or degree of cavitation) from day to day (8). CT findings in septic pulmonary emboli have been described in several articles: Multiple peripheral nodules are found 83-100%, a feeding vessel sign in 50-71%, wedge-shaped peripheral lesions abutting the pleura in 50-90%, cavity formation in 50-100%, and pleural effusion in 39-50% of patients (8-10). All these findings were present in our case and dramatic clinical and radiologic improvements were achieved by the treatment.

It is highly likely that CT is more sensitive than chest radiography early in the course of infection, when septic pulmonary emboli appear as small nodules. When chest radiographic findings are negative or equivocal, chest CT can play an important role in detecting the presence of septic pulmonary emboli (10). As septic pulmonary embolism due to peripheral intravenous cannula is a very rare entity, we decided to present our case.

REFERENCES

1. Hanibuchi M, Shimada R, Nishioka Y, Shinohara T, Sone S. A case of septic pulmonary embolism accompanied with tricuspid valve endocarditis and pyogenic spondylitis. *Nihon Kokyuki Gakkai Zasshi* 2003;41:365-9
2. Shiba E, Kambayashi J, Sakon M, et al. Septic pulmonary emboli after prolonged use of central venous catheter for parenteral nutrition. Case report. *Eur J Surg* 1992;158:59-61
3. Shiota Y, Arikita H, Horita N, et al. Septic pulmonary embolism associated with periodontal disease: reports of two cases and review of the literature. *Chest* 2002;121:652-654
4. Leroy B, Charre S, Tai RB, Barbieux H, Wattrisse G. Post-partum suppurating thrombophlebitis of the ovarian vein presenting with pleuropulmonary manifestations. *Ann Fr Anesth Reanim* 1999;18:783-6
5. Osei C, Berger HW, Nicolas P. Septic pulmonary infarction: clinical and radiographic manifestations in 11 patients. *Mt Sinai J Med* 1979;46:145-8
6. Freiberg DB, Barnes DJ. Fatal sepsis following peripheral intravenous cannula embolus. *Chest* 1992;101:865-66
7. Panidis IP, Kotler MN, Mintz GS, Ross J, Weber J. Clinical and echocardiographic

- correlations in right heart endocarditis. *Int J Cardiol* 1984;6:17–34
8. Huang RM, Naidich DP, Lubat E, Schinella R, Garay SM, McCauley DI. Septic pulmonary emboli: CT-radiographic correlation. *Am J Roentgenol* 1989;153:41–5
 9. Kuhlman JE, Fishman EK, Teigen C. Pulmonary septic emboli: diagnosis with CT. *Radiology* 1990;174:211–3
 10. Iwasaki Y, Nagata K, Nakanishi M, et al. Spiral CT findings in septic pulmonary emboli. *Eur J Radiol* 2001;37:190–4