







A Case of Sebaceous Carcinoma Detected on the Eyelid of a Horse

Aydın GÜREL¹ , Damla HAKTANIR¹ , İbrahim KURBAN² , Sevde İSLAMOĞLU³, Serhat ÖZSOY⁴ 

¹Department of Pathology, Istanbul University, Faculty of Veterinary Medicine, Istanbul, Turkey

²Equin and Training Programme, Vocational School of Veterinary Faculty, Istanbul University, Istanbul, Turkey

³Veterinary Faculty of Istanbul University, 3rd Year Student, Istanbul, Turkey

⁴Department of Surgery, Istanbul University, Faculty of Veterinary Medicine, Istanbul, Turkey

Cite this article as: Gürel, A., Haktanir, D., Kurban, I., Islamoğlu, S., Özsoy, S., 2018. A Case of Sebaceous Carcinoma Detected on the Eyelid of a Horse. Acta Vet Eurasia 44: 101-104.

ORCID IDs of the authors: ORCID IDs of the authors: A.G. 0000-0002-0268-7716; D.H. 0000-0001-5171-1927; İ.K. 0000-0002-8391-905X; S.Ö. 0000-0003-0988-7691

Abstract

This article describes a case of sebaceous carcinoma located on the right lower eyelid of an 11-year-old female Haflinger horse and its surgical, clinical, and histopathological aspects. The Haflinger horse was referred to the clinics of the Department of Surgery with a complaint of a swelling on the right lower eyelid, which had been present for 1 year and began to grow during the past few months. A clinical inspection revealed a soft, multinodular tumoral mass, with the dimensions of 4x5 cm, located in the inferior region of the right lower eyelid and protruding outward. The surgical removal of the mass was decided after the clinical inspection. The excised tumoral mass was submitted to the department of pathology for his-

topathological evaluation, which revealed well-circumscribed multilobular structures comprising foci of round-to-ovoid and polygonal pleomorphic neoplastic epithelial cells with prominent nuclei and eosinophilic cytoplasm separated by bands of the fibrous tissue of varying thickness. There was prominent cellular pleomorphism; some cells contained cytoplasmic vacuoles of various sizes, whereas some exhibited sebaceous differentiation. Based on these histopathological findings, sebaceous carcinoma of the sebocyte type was diagnosed.

Keywords: Equine, eyelid, histopathology, sebaceous carcinoma

Introduction

The most commonly encountered neoplastic lesions in horses are located in the skin, eye and genital system (Baptiste and Graham, 2000; Knottenbelt, 2011; Montgomery, 2014). Ocular and periocular tumors of the horses are categorized according to their anatomical locations which are 1) Orbit, 2) Eyelid, adnexa/palpebral conjunctiva, membrana nictitans, 3) Cornea/sclera/bulbar conjunctiva and 4) Intraorbital regions (Lavach and Severin, 1977; Montgomery, 2014).

Tumors that are originated from the eyelid and conjunctiva are the most frequent ocular neoplasms in horses and most common ones are squamous cell carcinoma and sarcoids (Arkan et al., 1997; Knottenbelt, 2011; Rooney and Robert-

son, 1996). Papilloma, melanoma and lymphoma though not as frequent as the above mentioned tumors also occur in these regions. Adenoma, adenocarcinoma, Meibomian epithelioma, angioma, basal cell carcinoma, fibroma, fibrosarcoma and mast cell tumors were also reported despite their rarity (Baker and Leyland, 1975; Baptiste and Graham, 2000; Brooks, 1999; Choi et al., 2013; Cotchin, 1977; Giulino, 2011; Knottenbelt, 2011). While the majority of these tumors are primary tumors, secondary tumors such as lymphomas may be encountered in the eyelid or the orbita by metastases (Knottenbelt, 2011; Lavach and Severin, 1977; Montgomery, 2014; Rooney and Robertson, 1996). Ocular neoplasms may be grossly confused with infectious or non-infectious lesions such as foreign body reactions, conjunctival infections, trauma, and cystic glandular changes of the eyelid. Determina-

Address for Correspondence: Aydın GÜREL • E-mail: Agurel@istanbul.edu.tr

Received Date: 7 September 2017 • Accepted Date: 7 December 2017 • DOI: 10.26650/actavet.2018.2808

© Copyright 2018 by Official Acta Veterinaria Eurasia. Available online at actavet Eurasia@istanbul.edu.tr



This work is licensed under a Creative Commons Attribution-NonCommercial 4.0 International License.

tion of the prognosis and accurate and rapid treatment of these lesions depends on the definitive histopathological diagnosis (Knottenbelt, 2011; Montgomery, 2014).

A case of sebaceous carcinoma located on the right lower eyelid of a Haflinger horse was described with its surgical, clinical and histopathological aspects.

Case Report

An 11-year-old female Haflinger horse was referred to the clinics of the Department of Surgery with the complaint of a swelling on the right lower eyelid (Figure 1a). The swelling occurred for a year and started to grow during the last few months. Clinical inspection revealed a soft, multinodular tumoral mass with the dimensions of 4x5 cm, located in the inferior region of the right lower eyelid protruding outwards. The mass was restricted to the conjunctiva and the lesioned area was covered with a thick purulent exudate (Figure 1b). Surgical removal of the mass was decided after the clinical inspection. A wide excision was done to remove the total mass under local anesthesia (Figure 1c) Post-operatively, the conjunctiva and the affected area were treated topically with sterile serum physiologic solution and antibiotic pomade for 7 days. The patient was discharged on the 10th post-operative day (Figure 1d). The owner reported that there was

no recurrence approximately 1 year after the treatment but the horse was tested positive for glanders and euthanized.

The excised tumoral mass was submitted to the Department of Pathology for histopathological evaluation. The specimen was fixed in 10% buffered formalin, routinely processed, embedded in paraffin and cut at about 4-5 μ m thickness and then stained with Hematoxylin and eosin (HE) to be evaluated by light microscopy.

Histopathology revealed well circumscribed multilobular structures composed of foci of round to ovoid and polygonal pleomorphic neoplastic epithelial cells with prominent nuclei and eosinophilic cytoplasm. The tumoral mass was separated into lobular structures by bands of fibrous tissue of varying thickness. There was prominent cellular pleomorphism and some cells contained cytoplasmic vacuoles of various sizes and some showed sebaceous differentiation (Figure 2a-d). Some lobules showed wide central caseification necrosis (Figure 2b) and some contained inflammatory cell infiltrations including neutrophil leukocytes and mononuclear cells extending from the center to the interlobular areas (Figure 2a). These neoplastic epithelial cells were larger than basaloid reserve cells and euchromatic (Figure 2c). Moreover, foci of neoplastic cells showed squamous differentiation and metaplasia in some areas with the formation of keratin pearls. There was an average of 2-4 mitotic figures in the different foci of atypical

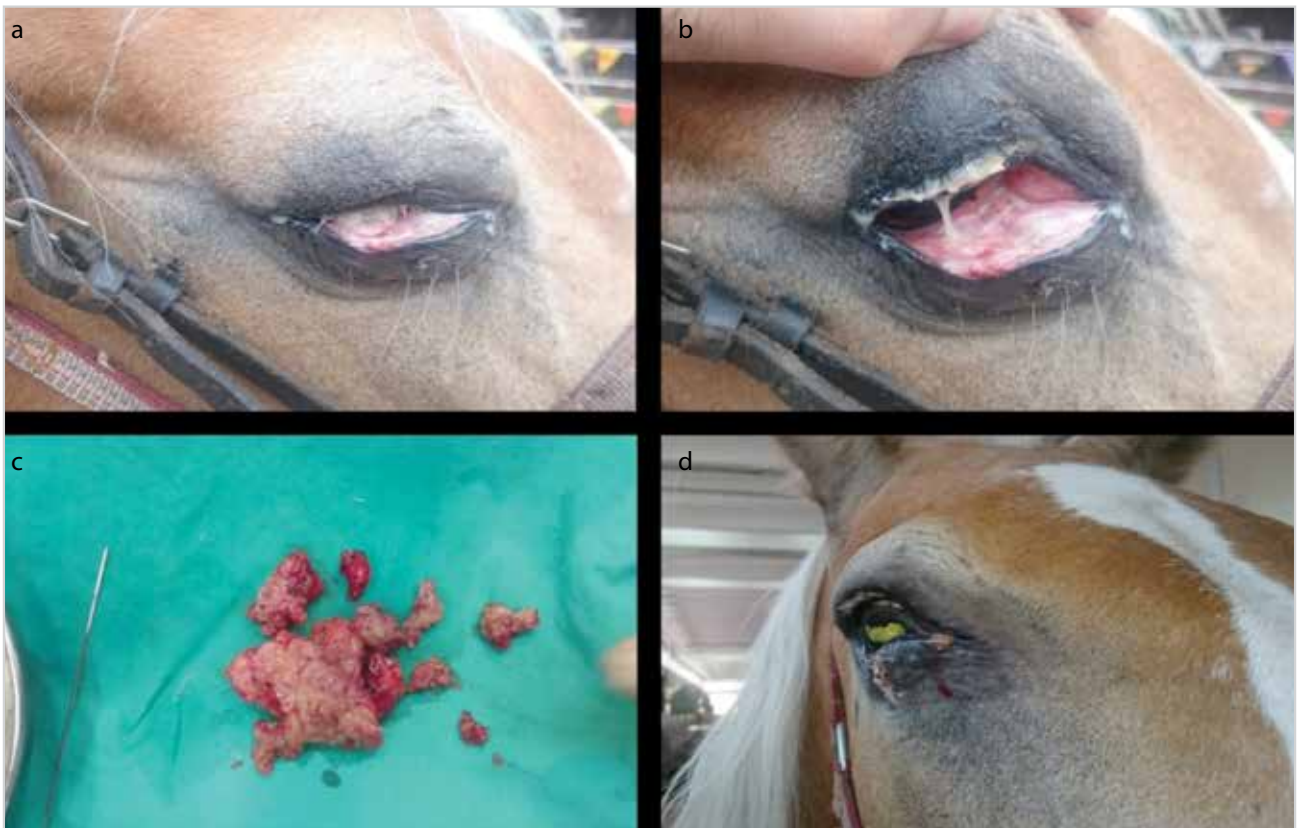

Figure 1. a-d. (a) Swelling on the right lower eyelid. (b) Prominent accumulation of purulent exudate in the lesioned area. (c) Multinodular structure of the surgically removed mass. (d) Postoperative appearance of the operation site

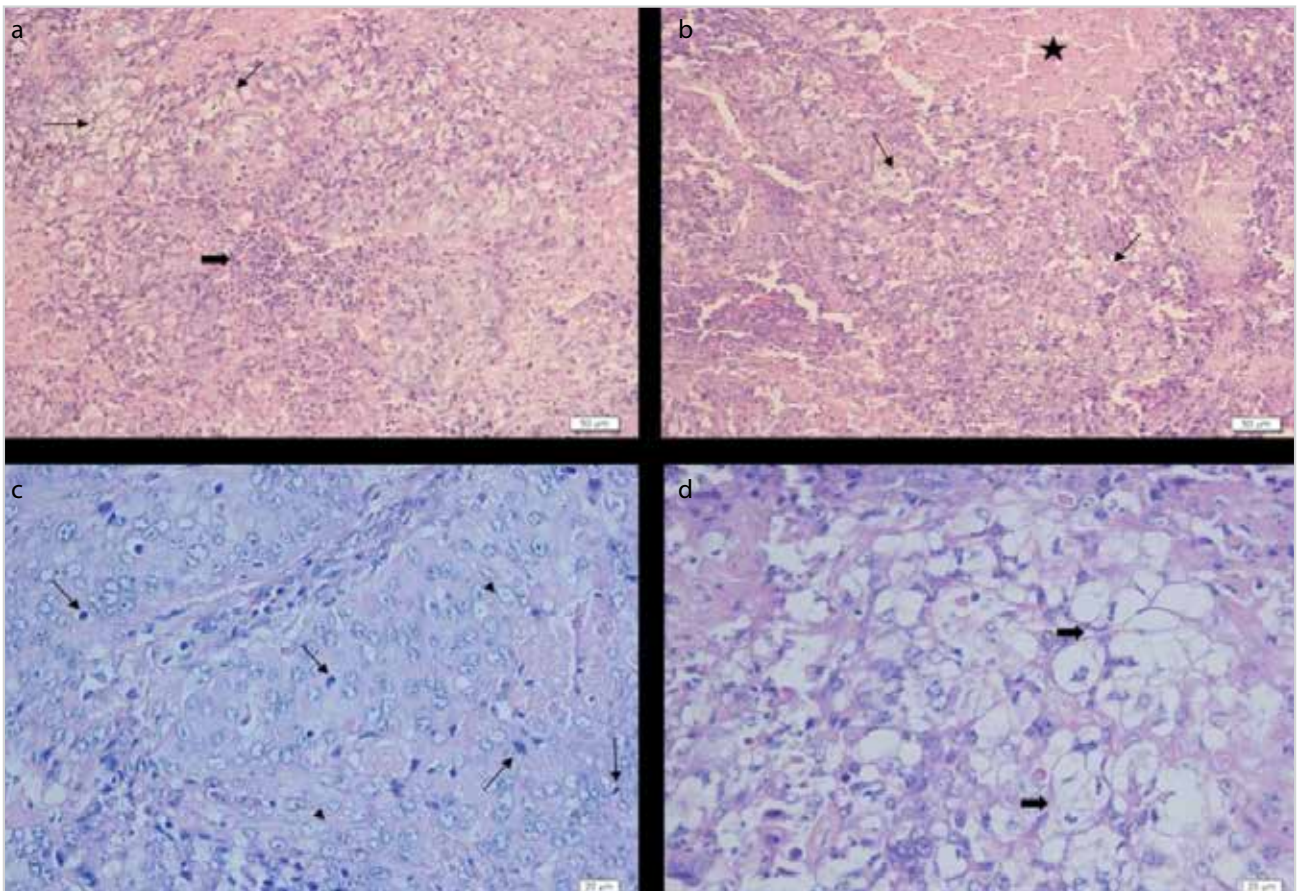


Figure 2. a-d. (a) Epithelial cells showing sebaceous differentiation (thin arrows), inflammatory reaction -lymphocyte and neutrophil leukocyte infiltration (thick arrow)-within the tumoral mass. H.E. Bar=50µm. (b) Epithelial cells showing sebaceous differentiation (thin arrows), tumor necrosis (star). H.E. Bar=50µm. (c) Basaloid cells with euchromatic nuclei of varying sizes (arrow heads), numerous mitotic figures (thin arrows). H.E. Bar=20 µm. (d) Different atypical cells showing sebaceous differentiation (thick arrows). H.E. Bar=20 µm

epithelial cells per high power field (40x) (Figure 2c). On the basis of histopathological features a diagnosis of sebaceous carcinoma of sebocytic type was rendered.

Discussion

Neoplastic lesions constitute 1-3% of all surgical cases in horses. (Arıkan et al., 1997; Cotchin, 1977). Ocular and periocular tumors account for approximately 10% of all equine tumors and around 80% show characteristics of malignancy (Baker and Leyland, 1975; Lavach and Severin, 1977; Montgomery, 2014). The most frequently seen tumors in this region are squamous cell carcinoma and sarcoids and although other types of tumors were occasionally reported (Baker and Leyland, 1975; Choi et al., 2013; Montgomery, 2014; Rachel et al., 2011; Rooney and Robertson, 1996), there is no data available with respect to the occurrence of sebaceous carcinoma originating from the conjunctiva of the horses. Therefore, this report was designed to be a contribution to the literature and described with its clinical and morphological features. To our knowledge this case was

the first reported case of conjunctival sebaceous carcinoma in a horse in Turkey and even in Europe.

Sebaceous carcinoma which has been reported in cats and dogs and rarely encountered in other species is a malignant tumor originating from the sebaceous cells (namely meibomian cells) in the eyelid and is also referred to as meibomian carcinoma (Goldschmidt and Goldschmidt, 2017; Gross et al., 2015). Only one case of meibomian epithelioma has been previously reported in the eyelid of a horse (Choi et al., 2013). Since there is no report available regarding equine sebaceous carcinoma, the relevant case was comparatively evaluated based on the features of equine meibomian epithelioma and canine and feline sebaceous carcinomas of the eyelid.

Sebaceous carcinomas in dogs and cats are known to be originating from the sebaceous cells in the eyelid. In our case, we consider that epithelial cells of the tarsal gland in the eyelid (Meibomian gland) were the cellular origin of sebaceous carcinoma (Banks, 1986). The incidence of sebaceous carcinoma

among feline and canine skin tumors was reported to be approximately 0.7%. These tumors are usually solitary ulcerated nodular lesions that can reach up to 7-8 cm in diameter (Goldschmidt and Goldschmidt, 2017; Gross et al., 2015). Our case was a diffusely ulcerated multinodular mass with the dimensions of 4x6. While canine and feline sebaceous carcinomas were reported to have developed usually on the head and the eyelids (Goldschmidt and Goldschmidt, 2017; Gross et al., 2015), the most frequently affected site was reported to be the eyelids in their human counterparts (Gross et al., 2015). This type of tumors was reported to be locally invasive and aggressive entities with rare incidences of distant metastasis in cats and dogs. Local metastasis and lymph node involvement were also noted (Goldschmidt and Goldschmidt, 2017; Gross et al., 2015). On the contrary, sebaceous carcinomas usually recur in humans (Gross et al., 2015). Our case was a locally invasive tumor but there was no evidence of recurrence after one year follow-up. However the horse was euthanized due to glanders. The microscopic findings detected in our case were consistent with those of canine sebaceous carcinomas and partly included some of the histomorphological features of meibomian epithelioma reported in a horse (Choi et al., 2013; Goldschmidt and Goldschmidt, 2017; Gross et al., 2015). Sebaceous epithelioma, which is another type of tumor arising from sebaceous glands, may be confused with sebaceous carcinomas due to their mild malignant changes. Therefore, an accurate histopathological evaluation is of great importance ((Choi et al., 2013; Goldschmidt and Goldschmidt, 2017; Gross et al., 2015). In our case, severe cellular pleomorphic changes such as prominent anisocytosis and anisonucleosis in numerous basal cells, sebocytic differentiations in fewer cells and presence of mitotic figures led us to the diagnosis of sebaceous carcinoma. Sebaceous carcinomas are divided into two groups as sebocytic sebaceous carcinomas and epitheliomatous sebaceous carcinomas according to their histomorphological features. (Gross et al., 2015). Our case was a sebocytic type sebaceous carcinoma. The distinct histomorphological features of the tumor and its consistency with canine and feline sebaceous carcinomas (Goldschmidt and Goldschmidt, 2017; Gross et al., 2015) excluded the necessity of immunohistochemistry. While primary neoplasms on the eyelid are usually unilateral, secondary neoplasms show bilateral involvement (Konnetbelt, 2011). We consider that our case was a primary sebaceous carcinoma originating from the tarsal gland (sebaceous gland) of the eyelid (Banks, 1986).

Surgical excision, laser therapy, radiotherapy, cryotherapy and chemotherapy are the most commonly preferred and most efficient therapeutic approaches of the tumors of the eyelid and periocular region in horses (Arıkan et al., 1997; Brooks, 1999). In this case, our treatment of choice was the total surgical removal of the mass due to the well circumscribed nature of the tumor within the conjunctiva, the owner's refusal of chemotherapy, inconvenience of cryotherapy and the lack of possibility of laser therapy and radiotherapy.

Peer-review: Externally peer-reviewed.

Author Contributions: Concept - A.G., D.H.; Design - A.G.; Supervision - A.G.; Resources - A.G., D.H.; Materials - İ.K., S.İ., S.Ö.; Data Collection and/or Processing - A.G., D.H.; Analysis and/or Interpretation - A.G.; Literature Search - A.G., D.H., İ.K., S.İ.; Writing Manuscript - A.G., D.H.; Critical Review - İ.K., S.Ö.; Other - A.G., D.H., İ.K., S.İ., S.Ö.

Conflict of Interest: The authors have no conflicts of interest to declare.

Financial Disclosure: The authors declared that this study has received no financial support.

References

- Arıkan N., Özer, K., Gürel, A., Gülanber, E.G., Yeşildere T., 1997.** İki Atta karşılaşılan Konjunktival Tümör Olgusu. *Veteriner Cerrahi Dergisi* 3(2), 5658.
- Banks, W.J., 1986.** Comparative Organology In Applied Veterinary Histology, Second Edition; pp.543 - 544, Williams and Wilkins, Baltimore, London.
- Baker, J.R., Leyland, A., 1975.** Histolojik survey of tumours of the horse, with particular reference to those of the skin. *Veterinary Record* 96, 419-422. [CrossRef]
- Baptiste, K.E., Grahan, B.H., 2000.** Equin orbital neoplasia; a review of 10 cases (1983- 1998). *Canadian Veterinary Journal* 41, 291-295.
- Brooks, D.E., 1999.** Equin Ophthalmology In *Veterinary Ophthalmology* (Gelatt K.N. ed.) 3rd Ed. pp.1053-1116.
- Choi, S.K., Park, J.K., Jeon, W.B., Lee, K.H., Cho, G.J., 2013.** Meibomian Epithelioma of The Lower Eyelid in a Thoroughbred Horse. *Pakistan Veterinary Journal* 2(33), 244-247.
- Cotchin, E., 1977.** A general Survey of Tumours in the Horse. *Equin Veterinary Journal* Vol: 9No; 1, 16-21.
- Giulino, E.A., 2011.** Equin Adnexal and nasolacrimal disease In ; *Equin Ophtalmology* pp. 133-180, Ed. B.C. Gilger, Elsevier Saunders, Maryland, Heights. [CrossRef]
- Goldschmidt, M.H., Goldschmidt, K.H., 2017.** Epithelial and Melanocytic Tumors of the Skin. In *Tumors in Domestic Animals* (Meuten D.J. ed.) Fifty Edi. pp. 108-111. Wiley Black well.
- Gross T.L., Iherke, P.J., Walder, E.J. Affolter, V.K., 2015.** Skin diseases of the dog and cat, clinical and histopathologic diagnosis, second editions, pp. 650-654. BlackWell Publishing Company. Oxford, London.
- Knottenbelt, D.C., 2011.** Ocular, Orbital and Periorbital Neoplastic Conditions of the Horse. Available from: <http://www.equineophtho.org/uploads/documents/KnottenbeltNotes2.pdf>.
- Lavach, J.D., Severin G.A., 1977.** Tumours of the equin eyes, adnexa and orbit; a review 68 cases. *Journal of the American Veterinary Medical Associations* 170, 202-206.
- Montgomery, K.M., 2014.** Equin Ocular neoplasia. A review, *Equin Veterinary Educations* 26(7), 372-380. [CrossRef]
- Rachel, L.M., Karen Paige, C., John, P., Philip, A.M., 2011.** Primary Lacrimal gland adenocarcinoma of the third eyelid in a horse. *Veterinary Ophthalmology* 14(1), 48-54.
- Rooney, J.R., Robertson J.L., 1996.** Ocular and Adnexal Neoplasia In; *Equin Ophthalmology*, pp. 130-131. Iowa State University Press, Ames-Iowa.