

Correlation of CD44 expression with prognostic factors in oral squamous carcinoma

ÖZER E., KUYUCUOĞLU F.

Department of Pathology, School of Medicine, Dokuz Eylül University, İzmir

Objective A retrospective study of 20 patients with squamous cell carcinoma of the oral cavity was undertaken to investigate the role of CD44 expression on the prognosis of oral cavity cancers.

Method CD44 expression was evaluated by immunohistochemistry, scored with intensity and distribution of immunostaining, and correlated with established prognostic markers such as nodal status, tumor stage, tumor site, and tumor thickness (depth of invasion).

Results 12 cases (60%) showed strong CD44 immunopositivity. Bivariate correlation analysis

revealed a significant Spearman correlation coefficient (r) for CD44 expression with nodal status and tumor thickness ($r=0.47$, $p=0.036$ and $r=0.57$, $p=0.008$, respectively). However, no correlation was found between CD44 expression and tumor stage or tumor site.

Conclusion We have concluded that CD44 expression in oral cavity cancers might play a significant role on predicting nodal metastasis and depth of invasion, thus might be a predictor of prognosis.

Key words CD44, oral cavity cancer, prognosis

Introduction

The structures within the anatomic confines of the oral cavity include lips, buccal mucosa (includes all membranes lining of the interior surface of the cheeks and the lips), alveolar ridges (upper and lower), retromolar trigone, floor of mouth, anterior two thirds of the tongue, the hard palate, gingiva (gums), and teeth.

Oral carcinomas represent approximately 4 % of all malignant tumors in man. Squamous cell carcinoma (SCC) is the most common malignant tumor of the oral cavity, accounting for over 90 % of the malignant neoplasms of this area. The order of most frequent sites of SCC in the oral cavity is lower lip (40%), tongue (25%) and floor of mouth (20%) (1-3). Nearly 60% of the patients present with an advanced stage of disease. The overall adjusted five year survival for all patients is approximately 50%. Prognosis is influenced by a variety of factors, the most important being tumor stage, tumor site, tumor thickness (depth of invasion) and nodal status (3-5).

CD44 is the major human cell surface receptor for hyaluronate and functions in a diverse range of physiological processes. CD44 may play a role in stimulating in vivo aggressiveness of tumors through hyaluronate-rich stroma (6). Expression of CD44 has been described to correlate with metastasis formation in various tumors, although evidence in oral cavity cancers is inconclusive. The purpose of the present study was to examine CD44 expression in oral cavity cancers and to investigate its correlation with a number of established prognostic parameters such as site, stage, depth of invasion and nodal status.

Material and Method

Twenty cases of oral SCC who had undergone neck dissection at the Dokuz Eylül University Hospital from 1991 to 1996 were reviewed. Medical records of each case were examined for primary site, TNM staging, and growth pattern.

Immunohistochemistry

Paraffin blocks of all tumors were obtained from the archives of Department of Pathology and sectioned onto polylysine-coated slides. The avidin-biotin-peroxidase method was performed using the primary monoclonal antibodies against CD44H, standard isoform (1:60, DAKO Corp). Briefly, the sections were deparaffinized and washed in phosphate-buffered saline (PBS). Endogenous peroxidase activity was blocked using a 0.3% solution of hydrogen peroxidase at room temperature for five minutes. After microwave treatment for antigen retrieval, primary antibodies were applied for 30 minutes at room temperature and washed in PBS. Linking antibody and streptavidin-peroxidase complex (DAKO LSAB kit) were added consecutively for 10 minutes at room temperature and washed in PBS. The peroxidase activity was visualized with diaminobenzidine (Sigma Chemical Co), applied for five minutes. Positive controls were also stained with the primary antibody.

Evaluation of Immunohistochemical Staining

The most representative tumor areas were selected for scoring the immunostaining pattern. The degree of positive staining for CD44 antibody was evaluated by a well-established semiquantitative scoring on a scale of 1 to 4 for intensity (I) such as none, mild, moderate and strong, and for distribution (D) such as none, focal, patchy and diffuse (7). Tissues with I x D less than or equal to four were considered weakly positive and those with I x D greater than four were designated strongly positive. Statistical analysis was

by bivariate correlation analysis using computer software (SPSS). Reproducibility of the immunohistochemical evaluation was tested by comparison of data obtained consecutively without knowing the first assessment, and the intraobserver reproducibility was 0.85 (Kappa correlation coefficient).

Assessment of Tumor Thickness

Tumor thickness or depth of invasion was assessed objectively using Breslow-type measurement with a micrometer placed in the ocular of the microscope. Measurements excluded layers of surface keratin and parakeratin. As described by Shingaki et al (8) according to the depth of invasion, the cases were separated into three groups: tumors with depth of invasion equal or less than 4 mm, tumors with depth of invasion greater than 4 mm but

less than 8 mm, and tumors with depth of invasion greater than 8 mm.

Results

The clinicopathological data are summarized in Table I. The most frequent tumor sites were tongue (40%), lips (25%), and gingiva (20%). Regarding the tumor stage, either T2 or T4 tumors comprised 35% of the overall cases, while 20% of the cases were T1. 15 cases (75%) had nodal metastasis. Among these, the nodal status of 11 cases (55%) was N2b. The measurement of tumor thickness revealed that 11 cases (55%) had a depth of invasion greater than 8 mm, and six cases (30%) had a depth of less than 8mm and greater than 4 mm. The majority of cases (90%) showed a tumor pattern of cords of tumor cells..

Table I. Clinicopathological data obtained from the present study.

No	Site	Stage	Nodal status	Thickness	CD44 immunopositivity
1	tongue	T1	N2b	4-8mm	Strong
2	lip	T2	N2b	>8mm	Strong
3	gingiva	T4	N1	>8mm	Strong
4	tongue	T4	N1	4-8mm	Weak
5	tongue	T4	N2b	>8mm	Strong
6	tongue	T4	N2b	>8mm	Strong
7	tongue	T2	N1	4-8mm	Weak
8	lip	T4	N2b	>8mm	Strong
9	gingiva	T3	N2b	>8mm	Strong
10	gingiva	T4	N2b	>8mm	Strong
11	gingiva	T2	N2b	>8mm	Strong
12	buccal mucosa	T2	N2b	4-8mm	Weak
13	lip	T4	N2c	>8mm	Weak
14	tongue	T1	N2b	>8mm	Strong
15	tongue	T2	N2b	>8mm	Strong
16	lip	T3	No	4-8mm	Weak
17	floor of mouth	T2	No	4-8mm	Strong
18	lip	T1	No	<4mm	Weak
19	tongue	T1	No	<4mm	Weak
20	lip	T2	No	<4mm	Strong

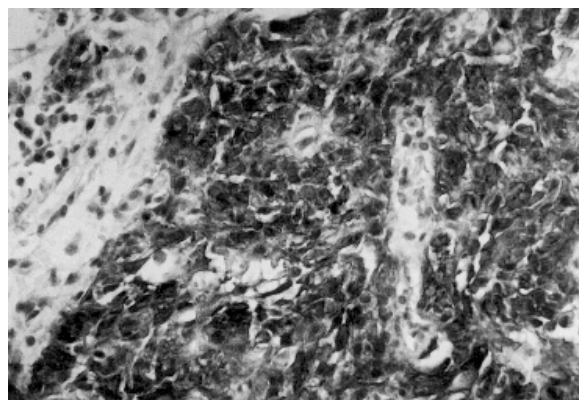


Figure 1. CD44 immunostaining shows strongly positivity in a cancer arising from gingiva. Immunoperoxidase staining, 200 X.

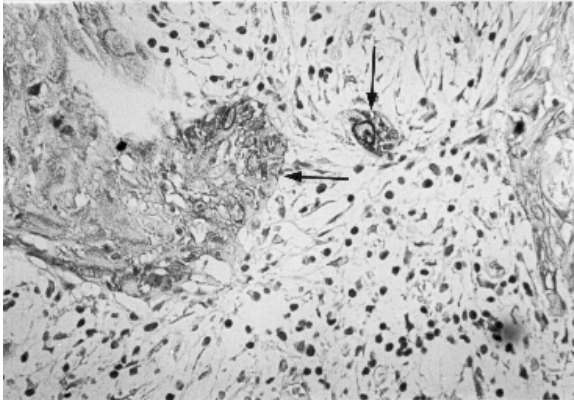


Figure 2. CD44 staining of oral carcinoma shows weakly CD44-positive tumor cells (black arrow). Immunoperoxidase staining, 100 X.

Table II. Bivariate correlation analysis of CD44 expression with prognostic factors

	r *	p value
CD44 expression vs. stage	0.11	0.61
CD44 expression vs. site	0.19	0.93
CD44 expression vs. nodal status	0.47	0.03
CD44 expression vs. thickness	0.57	0.008

*r=Spearman correlation coefficient

Discussion

CD44 is a transmembrane glycoprotein that binds hyaluronan, extracellular matrix proteins and growth factors. Alternative splicing of a single gene generates a family of splice variants (CD44v1-10) in addition to the standard isoform, CD44H. Expression of the variable exons has been correlated with tumor progression and metastasis in a range of cell types. However, multiple CD44 isoforms are expressed by normal stratified squamous epithelia, such as the epidermis and the lining of the oral cavity (6).

Numerous studies of histopathologic features of tumor and host response parameters in oral SCC have shown variable prognostic significance. The main prognostic determinate in carcinomas of the oral cavity is stage of the disease. The TNM classification of cancers arising in oral cavity, based upon extent and size of primary tumor, and absence / presence and extent of regional lymph node metastasis, is a generally useful and widely applied method for estimating prognosis and planning therapy (3, 8).

Our results indicate a significant correlation between CD44 expression and nodal status. This might be explained by the possible role of CD44 expression of tumor cells on metastatic behaviour. However, CD44 expression did not correlate with tumor stage. This might not be contradictory to our hypothesis concerning the prognostic value of CD44 expression because of the suggestion that tumor size does not correlate closely with clinical outcome, except for small tumors (9). Additionally, our results did not reveal any correlation with site of the tumor. This might be explained with limited number of cases in the study. Although some studies have found tumor grade to be predictive of regional lymph node metastasis, assessments of tumor grade encompassing traditional histologic and cytologic features of differentiation are often contradictory (10, 11). Therefore, we did not study tumor grade because of its limited clinical value.

The pattern and the thickness of tumor and the presence of lymphatic-vascular invasion are important indicators in prediction of cervical lymph node metastasis (12-14). The pattern of invasion characterized by infiltrative single cells is associated

with a higher frequency of regional lymph node metastasis than the pattern composed of invasive cords of tumor. The majority of tumors (90%) included in the present study showed the latter pattern. Shingaki et al (14) reported that tumors with depth of invasion less than 4 mm had a metastatic rate of 8.3%, while tumors greater than 8 cm had 83%. Other assessments such as host inflammatory and desmoplastic response have added no consistent or discriminating information (14). Our results indicated a significant correlation for CD44 expression with tumor thickness.

To conclude, the present study has demonstrated that CD44 expression by tumor cells in oral cavity carcinomas is statistically correlated with two main prognostic determinates, nodal metastasis and tumor thickness. Thus, we think that CD44 might be a good candidate as a predictor of prognosis in this group of cancers. However, a larger series with clinical follow-up and study of other biological markers of tumor progression is needed to determine whether it is an independent prognostic factor or not.

References

- Borges AM, Shrikhande SS, Ganesh B.: Surgical pathology of squamous carcinoma of the oral cavity: its impact on management. *Semin Surg Oncol* 5: 310-317, 1989.
- Cummings BJ, Clark RM.: Squamous cell carcinoma of the oral cavity. *J Otolaryngol* 11: 359-364, 1982.
- Wenig B.: Atlas of head and neck pathology, W B Saunders: Philadelphia 1993, pp: 715-718.
- Tytor M, Olofsson J.: Prognostic factors in oral cavity carcinomas. *Acta Otolaryngol Suppl* 492: 75-78, 1992.
- Wildt J, Bjerrum P, Elbrand O.: Squamous cell carcinoma of the oral cavity: a retrospective analysis of treatment and prognosis. *Clin Otolaryngol* 14: 107-113, 1989.
- Hudson DL, Speight PM, Watt FM.: Altered expression of CD44 isoforms in squamous-cell carcinomas and cell lines derived from them. *Int J Cancer* 66: 457-463, 1996.
- Gilcrease MZ, Truong L, and Brown RW.: Correlation of very late activation integrin and CD44 expression with extrarenal invasion and metastases of renal cell carcinoma. *Hum Pathol* 27: 1355-1360, 1996.
- Maddox WA, Urist MM.: Histopathological prognostic factors of certain primary oral cavity cancers. *Oncology* 4: 39-42, 1990.
- Moore C, Flynn MB, Greenberg RA.: Evaluation of size in prognosis of oral cancer. *Cancer* 58: 158-162, 1986.
- Yamamoto E, Miyakawa A, Kohama G.: Mode of invasion and lymph node metastasis in squamous cell carcinoma of the oral cavity. *Head Neck Surg* 6: 938-947, 1984.
- Umeda M, Yokoo S, Take Y, Omori A, Nakanishi K, Shimada K.: Lymph node metastasis in squamous cell carcinoma of the oral cavity: correlation between histologic features and the prevalence of metastasis. *Head Neck* 14: 263-272, 1992.
- Martínez-Gimeno C, Rodríguez EM, Vila CN, Varela CL.: Squamous cell carcinoma of the oral cavity: a clinicopathologic scoring system for evaluating risk of cervical lymph node metastasis. *Laryngoscope* 105: 728-733, 1995.

13. Rasgon BM, Cruz RM, Hilsinger RL Jr, Sawicki JE.: Relation of lymph-node metastasis to histopathologic appearance in oral cavity and oropharyngeal carcinoma: a case series and literature review. Laryngoscope 99: 1103-1110, 1989.
14. Shingaki S, Suzuki I, Nakajima T, Kawasaki T.: Evaluation of histopathologic parameters in predicting cervical lymph node metastasis of oral and oropharyngeal carcinomas Oral Surg Oral Med Oral Pathol 66: 683-688, 1988.

Correspondance to:

Dr. Erdener Özer

Dokuz Eylül Üniversitesi Tıp Fakültesi

Patoloji ABD, 35340 Söke

İZMİR / TÜRKİYE