

Case Report

Disseminated form of childhood lichen planusSanjaya PR^a, Kaveri Hallikeri^{b*}, Punnya V Angadi^c^aDepartment of Oral Pathology, Darshan Dental College, Udaipur, Rajstan. India^bDepartment of Oral Pathology, SDM College of Dental Sciences and Hospital, Dharwad-580009, Karnataka India^cDepartment of Oral Pathology, KLE VK Institute of Dental Sciences and Hospital, Belgaum-590010, Karnataka India

Abstract. Lichen planus is a common mucocutaneous disease in adults. Childhood lichen planus is an extremely rare entity which is characterized by violaceous, scaly flat topped polygonal papules with the oral involvement being extremely uncommon. Early and correct diagnosis is very important to avoid further complications. We report a nine year old boy with disseminated lichen planus involving the flexor aspect of the wrists and legs as well as, oral and genital mucosal involvement which regressed after treatment. This is to add another case of lichen planus in a child and to emphasize its consideration in the differential diagnosis of oral mucosal white patches in children.

Key words: Childhood, lichen planus, disseminated, oral, skin

1. Introduction

Lichen planus is an unique inflammatory disorder that affects the skin, mucous membranes, nails and hair was first described and named by Erasmus Wilson in 1869 (1).

Lichen planus peaks between the ages of 30 to 60 years, while children comprise only 2 to 3% of reported cases. The majority of cases were in females in the age group of 8 to 14 yrs with; the youngest child being three years old. The etiology of this condition remains obscure, but it appears to be complex and multifactorial (2). The clinical presentation of lichen planus is diverse. The skin lesions present as purple, polygonal, pruritic, flat topped, papules. Wickham's striae are evident on the surface of papules as a reticulate network of fine white lines. Oral mucosal involvement in adults itself accounts for only 0.5 % to 19% while in children, it is much more uncommon. Oral lesions classically present as a bilaterally symmetrical white network found on the buccal mucosa, tongue, lips and hard palate, although occasionally they can present as erosive areas, ulcerations and very rarely in the form of white plaques (3,4).

Here, we report a case of lichen planus occurring in a young boy of 9 years to emphasize the importance of considering lichen planus in the differential diagnosis of white patches affecting the oral mucosa in childhood.

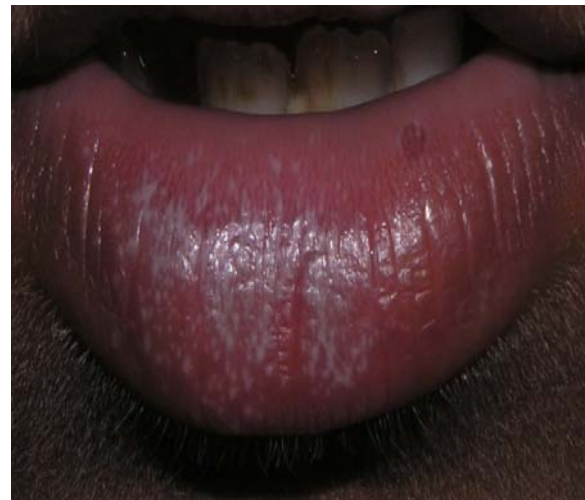

Fig. 1. Diffuse keratotic lesion on lower lip.

2. Case report

A 9 year old boy was referred to our institution for evaluation of white lesions; who also gave history of burning sensation on taking spicy food since 15 days. On intraoral examination, the lesions appeared as white lacy reticulate pattern on the buccal mucosa bilaterally and on the tongue, hard palate and lips (Fig. 1 and 2). Further, examination of skin revealed purplish, polygonal papules symmetrically distributed over

*Correspondence: Dr. Kaveri Hallikeri

Department of Oral Pathology,
SDM College of Dental Sciences and Hospital,
Dharwad-580009, Karnataka INDIA
E-mail: drcauveri2005@gmail.com

Received: 01.03.2010

Accepted: 05.07.2010

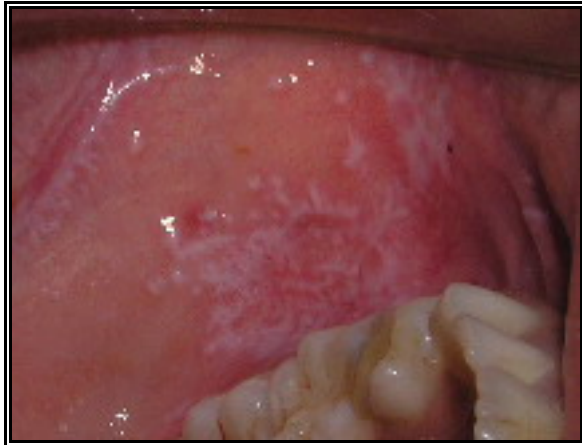

Fig. 2. Intraorally, the lesions appeared as white lacy reticulate pattern on the buccal mucosa.

the body including the limbs, lower back, chest, peritibial areas, genitalia, face and scalp (Fig 3 and 4). There was appearance of new lesions along the line of trauma (Koebner's phenomenon positive). The patient gave history of moderate itching for 4 months. The nails appeared to be normal. There was neither relevant medical history, drug history nor any family history.

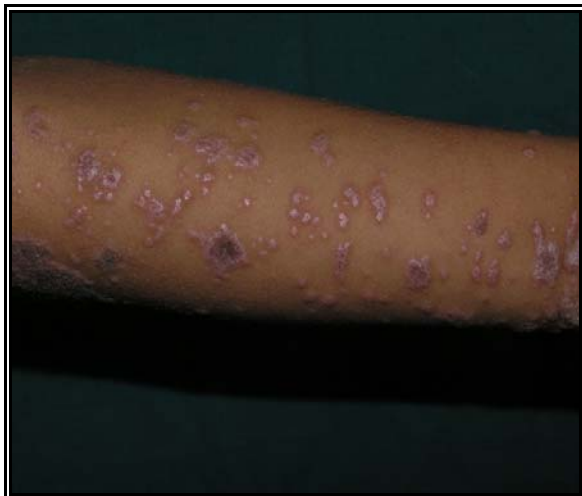

Fig. 3. Papules over the skin with shiny surface and healing the center of the lesion.

Initially, it was thought as an allergic reaction when it first appeared on the chest. He was put on antiallergic drugs ie Cetirizine (1 tab/day for 14 days) and Allegra (Fexophenadina) (120 mg/ day for 10 days). However, there was no resolution of lesion. Instead, the lesions gradually spread to other parts of the body. Finally, it was diagnosed clinically as lichen planus and the patient was treated with oral prednisolone (5mg/day) for 3 months and significant improvement was seen in 30 days. The dosage was tapered down

progressively and was continued at 2mg/ day for 3 months.

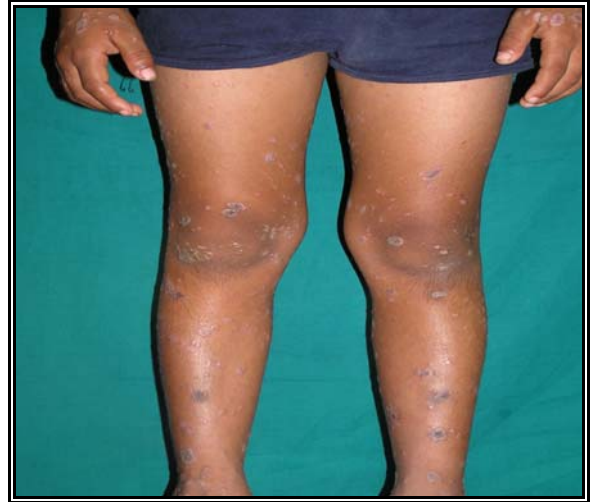

Fig. 4. Papules and plaques were seen symmetrically distributed all over the body like limbs.

The incisional biopsy of skin of the leg and buccal mucosa was done to confirm the clinical diagnosis. The skin biopsy showed papillomatosis of epidermis with hyperkeratosis and marked acanthosis with formation of bulbous rete ridges. Vacuolar degeneration of basal cells and lymphocytic infiltration in the lamina propria was noted. A few apoptotic bodies were also evident at the site of vacuolar degeneration. The mucosal biopsy showed mild keratosis and acanthosis with elongated rete ridges. Basal cell degeneration with apoptotic bodies was noted. The sub-mucosa showed lymphocyte infiltration (Fig.5). The histopathological features were consistent with hypertrophic form of lichen planus.

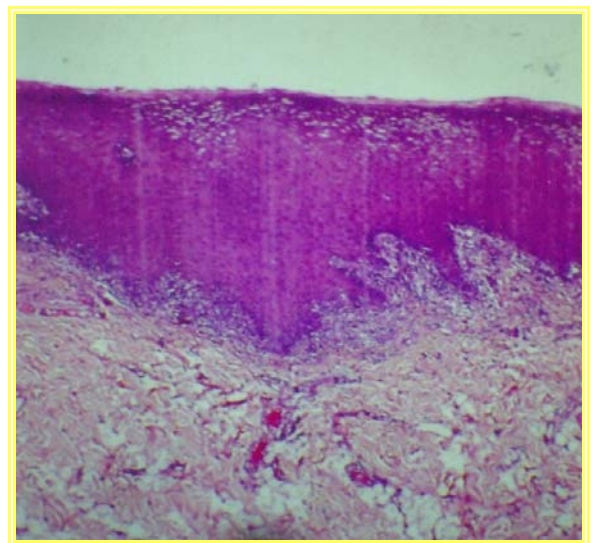


Fig. 5. Microphotographic features shows acanthosis with elongated rete ridges and lymphocytic cell infiltration in the subepithelial region (H & E.100X).

The lesions responded well to treatment and the skin lesions healed with pigmentation whereas oral lesions did not reveal any pigmentation. Marked clinical improvement was followed after six months and patient is free from recurrence after a follow up of two years.

3. Discussion

Oral lichen planus has been described in children as early as the 1920's but has been reported as an exceptionally rare occurrence (<2-3%). Most reports have been in patient living in the tropics mainly from India, with some from the United Kingdom (Milligan), Italy, Mexico, African America and Kuwait. The explanation for this condition is unknown. Probably genetic and environmental factors are considered as a risk factor. The reasons for the rarity is not known but could be attributed to the relative rarity of the factors known to play an important role in the pathogenesis of LP like drugs, vaccinations and viral infections. This role of infection and vaccination in triggering LP has been repeatedly suggested over the years, in particular chronic active hepatitis C infection and immunization against hepatitis B virus. Familial lichen planus has also been reported as being an uncommon causative factor (10). A study reported that 12% of his patients with familial LP presented before the age of 10 years (11). However, no obvious precipitating factors and familial history could be elicited in our patient.

Most studies on childhood LP have shown equal sex predilection; however few studies demonstrated a male preponderance (7, 10). Our case too occurred in a 9 year old male child.

Skin, oral and genital mucosa and scalp involvement was noted in our patient and there were no nail and palmoplantar lesions seen. Previous studies have reported mainly skin involvement; very rarely oral mucosa is affected and has been reported from India (17%) and more so from Kuwait (39%) (7). Other sites affected were nail (2-3%), scalp and palmoplantar areas (11,12).

The common morphology of childhood lichen planus is the classical pattern however other clinical presentations are linear, annular, bullous, follicular, erosive and hypertrophic (5,8). Our patient presented with a hypertrophic and erosive type of LP and lesions were densely pruritic. This finding is consistent with those of other authors who reported pruritis with a high frequency of 96% (6), 87% (9) and 100% (10). Therefore; it can be considered a common symptom in children.

Essential histopathological features include superficial band like infiltrate of T lymphocytes, basal cell liquefaction degeneration and normal epithelial maturation pattern. Additional features are jagged spindly rete ridges, civatte bodies and separation of epithelium from lamina propria (4,5). Immunofluorescence of peri-lesional mucosa will show fibrin and shaggy fibrinogen in a linear pattern at the basement membrane zone and cytoids in the absence of deposition of fibrinogen (6). Our case showed pappillomatosis and hyperkeratosis with bulbous rete ridges suggestive of a hypertrophic variant.

Differential diagnosis for the childhood lichen planus should include lichenoid drug reaction, lichen striatus, lichen nitidus, papillar acrodermatitis of childhood, pityriasis rosea and psoriasis (1,5,7) while; in the oral cavity could encompass candidiasis, lichenoid reaction and drug reaction.

The risk of malignancy in oral lichen planus is fairly low, with an incidence of 0.2% of patients with oral lichen planus developing squamous cell carcinoma (7). The scarcity of literature in children does not allow for objective data regarding the malignant transformation rate in childhood lichen planus.

To date, due to a lack of controlled clinical trials, no consensus exists regarding standardized therapy regimens for generalized LP in childhood. Still, effective treatment of this highly pruritic skin condition is mandatory to effectively suppress pruritus and to quickly restore quality of life. A short course of systemic steroids has been used in children to control eruptive, widespread disease. If there is clinical improvement, the dose is tapered gradually and replaced by Dapsone. Triamcelone acetone is used in patients with symptomatic oral lesions. Recently Ultraviolet B phototherapy was also found to be safe and effective especially in patients with eruptive and widespread disease (7,12).

Most pediatric patients respond to treatment with full clearance over one to six months. Erosive or disseminated lichen planus can be very resistant to the treatment. Oral lichen planus has many clinical presentations, with some lesion requiring no treatment and others needing management for decades. The lack of long term follow-up in most of the reported studies makes it difficult to draw any conclusion regarding the effective treatment regimen and prognosis of childhood lichen planus (7,12).

To conclude, lichen planus is not a life threatening disease but is an intensely pruritic disorder that can cause lowering of the quality of life. Early diagnosis and correct treatment are

very important especially in children to avoid such complications. Lichen planus should be considered in the differential diagnosis in children presenting with white lesions of the oral mucosa.

References

1. Pinar Oztas, Meltem Onder, Nilsel Ilter, Murat Orhan Oztas. Childhood lichen planus with nail involvement: a case. *Turkish J Pediatrics* 2003; 45: 251-253.
2. Sugarman PB, Savage NW, Walsh LJ, et al. The pathogenesis of oral lichen planus. *Crit Rev Oral Biol Med* 2002; 13: 350-365.
3. Eisen D, Carrozzo M, Bagan Sebastian J-V, Thongprasom K. Oral lichen planus: clinical features and management. *Oral Diseases* 2005; 11: 338-349.
4. Luis-Montoya P, Dominguez-Soto L, Vega-Memije E. Lichen planus in 24 children with review of the literature. *Pediatric Dermatol* 2005; 22: 295-298.
5. Alam F, Hamburger J. Oral mucosal lichen planus in children. *Int J Paediatric Dent* 2001; 11: 209-214.
6. Kumar V, Garg BR, Baruah MC, Vasireddi SS. Childhood lichen planus. *J Dermatol* 1993; 20: 175-177.
7. Kanwar AJ, De D. Lichen planus in childhood: a report of 100 cases. *Clin Exp Dermatol* 2009; 35: 257-262.
8. Handa S, Sahoo B. Childhood lichen planus: a study of 87 cases. *Int J Dermatol* 2002; 41: 423-427.
9. Nanda A, Al-Ajmi HS, Al-Sabah H, Al-Hasawi F, Alsaleh QA. Childhood lichen planus: a report of 23 cases. *Pediatr Dermatol* 2001; 18: 1-4.
10. Sharma R, Maheshwari V. Childhood lichen planus: a report of 50 cases. *Pediatr Dermatol* 1999; 16: 345-348.
11. Mahood JM. Familial lichen planus. A report of nine cases from families with a brief review on the literature. *Arch Dermatol* 1983; 119: 292-294.
12. Sugeran PB, Savage NW. Oral lichen planus: Causes, diagnosis and management. *Australian Dent J* 2002; 47: 290-297.