

Non-Reactive Tuberculosis Mimicking Histopathological Features of Kikuchi's Disease: A Case Report

Köse M.¹, Karakök M.², Özbay B.³, Özen S.¹

Department of the Pathology¹, School of Medicine, Yüzüncü Yıl University, Van, Turkey

Department of the Pathology², School of Medicine, Gaziantep University, Gaziantep, Turkey

Department of Pulmonary Diseases³, School of Medicine, Yüzüncü Yıl, University, Van, Turkey

Key words: Kikuchi's disease, non-reactive tuberculosis

Tuberculosis is a worldwide, chronic, communicable disease caused by the *Mycobacterium tuberculosis*, which usually affects the lungs but may cause lesions in any organ or tissue of the human body. It evokes focal granulomatous inflammatory reactions that typically undergo central caseous necrosis. These "caseating granulomas" are the histologic hallmarks of tuberculosis, but in non-reactive tuberculosis there is little or no granuloma formation, giant cells and at times even macrophages are absent. The latter circumstance may confuse with other necrotizing diseases (1).

Kikuchi's disease (histiocytic necrotizing lymphadenitis) was first reported independently by Kikuchi and Fujimoto et al in 1972 (2). The disease has characteristically clinical findings of localized lymphadenopathy, leukopenia, fever, occasional skin rashes and spontaneous healing within several months. The classical histological picture is characterized by zonated paracortical karyorrhectic (necrotizing) nodules with immunoblastic and histiocytic proliferation (3)

In this report we present a case of non-reactive tuberculosis mimicking histopathological features of Kikuchi's disease.

Case report

A 45-years-old female was admitted to the hospital with two painful enlarged nodes in her left axillary region. The patient reported that these nodes had been present for more than one month.

The nodes were removed and sent to our laboratory fixed in formalin. Of these, one was measured 2.5x2x2 cm in size and the other had a diameter of 2 cm. Samples contained four pieces taken from the both nodes, two from each. Sections were prepared and stained with haematoxylin and eosin, Giemsa, periodic acid Schiff (PAS), silver impregnation (Gomori) and then Ziehl-Neelsen.

In gross examination, lymph nodes with capsule was observed. The cut surface of the lymph nodes were yellow-white in color and had solid appearance. In microscopic examination at low magnifications, lymph nodes appeared mottled because of coagulative necrosis in paracortex (Figure 1). High magnification showed karyorrhectic debris and phagocytic histiocytes in the central regions of the necrotic areas. Intermediate zone showed an admixture of immunoblasts, plasmacytoid monocytes, histiocytes, and small lymphocytes (Figure 2) and outermost zone was predominated by lymphocytes mixed with immunoblast and histiocytes, while neutrophils were absent. The

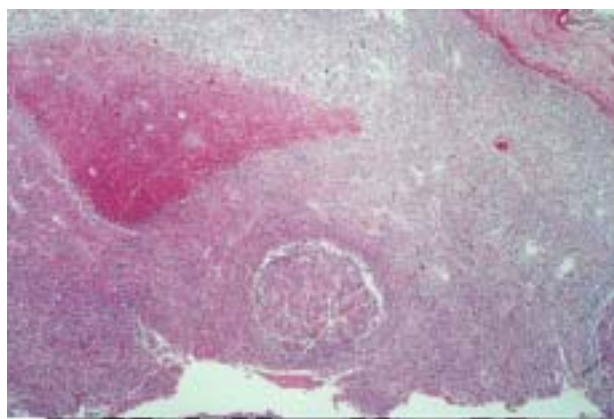


Figure 1. Patchy coagulative necrosis areas in paracortex (HE X 50).

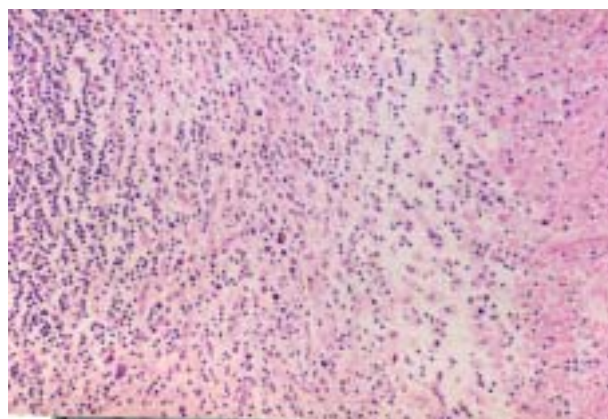


Figure 2. The intermediate zone showing an admixture of immunoblasts, plasmacytoid monocytes, histiocytes, and small lymphocytes (HE X 125).

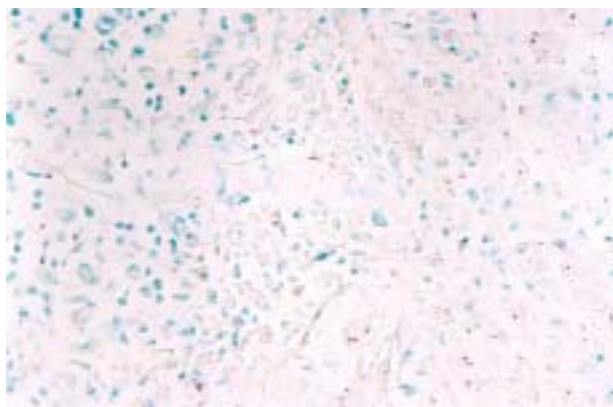


Figure 3. Acid-fast bacilli scattered within macrophages (Ziehl-Neelsen X 500)

paracortex adjacent to the karyorrhectic foci was hyperplastic.

Granulomas relevant to tuberculosis were not seen, and the case reported being histiocytic necrotizing lymphadenitis (Kikuchi’s disease). But further investigation of past medical history revealed tuberculosis a few years ago. Accordingly the specimens were stained with Ziehl Nielsen and the bacilli were detected. (Figure 3.) The final diagnosis was confirmed as non-reactive tuberculosis.

Discussion

Kikuchi’s disease is a form of benign necrotizing lymphadenitis which usually affects cervical lymph nodes of young women. The classical histological picture is characterized by zonated paracortical karyorrhectic (necrotizing) nodules with immunoblastic and histiocytic proliferation. A majority of the patients in the reported series are young women. Although the histogenesis and pathogenesis of the lesion are unknown, some protozoa or microorganisms were suspected to be the causative agents (3-4).

Lymph nodes involved by tuberculosis may become adherent to each other and form a large multinodular mass that can be confused clinically with metastatic carcinoma. The most common location of clinically apparent lymphadenopathy is the cervical region, where a draining sinus may form that communicates with the skin(5-6).

The lymph nodes were in axillary region in our case.

Microscopically, the appearance ranges from multiple small epithelioid granulomas reminiscent of sarcoidosis to huge caseous masses surrounded by Langhans’ giant cells, epithelioid cells, and lymphocytes (7). Also in non-reactive tuberculosis, histologically large areas of necrosis, not typical of caseation but often containing fibrin and red cells as well as nuclear debris, merge with a poorly defined surrounding zone macrophages. There is a little or no granuloma formation, giant cells and at times even macrophages are absent, in which case the term ‘non-reactive’ is indeed correctly applied. In any lymph node

biopsies showing unexplained areas of necrosis with little or no cellular reaction, urgent examination for *M. tuberculosis* is mandatory (8).

In our case, due to patchy pattern of coagulation necrosis in paracortex, with absence of granulomatous reaction or typical caseous necrosis and the location of the lesion, tuberculosis was not taken into consideration initially. Because of coincidence of the histopathologic findings, the case was diagnosed as Kikuchi lymphadenitis. In follow-up a history of tuberculosis was obtained and the specimens were stained with Ziehl-Nielsen. The diagnosis was changed to non-reactive tuberculosis upon observation of the bacilli in Ziehl-Nielsen staining.

In conclusion we suggest that in countries where tuberculosis is endemic like Turkey, necrotising lymphadenitis should always necessitate investigation for tuberculosis even if the characteristic features of the disease is missing. In contrast to granulomatous lesions, the bacilli are more readily demonstrable in nonreactive tuberculosis, making the diagnosis easier once considered.

References

1. Cotran RS, Kumar V, Robbins SL: Robbins Pathologic Basis of Disease W.B. Saunders Company, Philadelphia, 1989, pp: 374-380.
2. Dorfman RF: Histiocytic necrotizing lymphadenitis of Kikuchi and Fujimoto. Arch Pathol Lab Med 1987;111: 1026-1029.
3. Tsang WYW, Chan JKC. Kikuchi’s lymphadenitis: A morphologic analysis of 75 cases with special reference to unusual features. Am J Surg Pathol 18: 219-231, 1994.
4. Bhat NA, Hock YL, Turner NO, Das Gupta AR: Kikuchi’s disease of the neck (histiocytic necrotizing lymphadenitis). J Laryngol Otol 112: 898-900, 1998.
5. Jayaraj SM, Lloyd J, Frosh AC, Patel KS: Kikuchi – Fujimoto syndrome masquerading as tuberculosis. J Laryngol Otol 113: 82-84, 1998.
6. Seth V, Kabra SK, Jain Y, Semwal OP, Mukhopadhyaya S, Jensen RL: Tubercular lymphadenitis: clinical manifestations. Indian J Pediatr 62: 565-70, 1995.
7. Buchi M, Grossenbacher R: Cervical tuberculous lymphadenitis—an up-to-date guideline for management. Schweiz Med Wochenschr Suppl 125: 44-47, 2000.
8. Stansfeld AG, d’Ardenne AJ: Lymph Node Biopsy Churchill Livingstone medical Division of Longman Group UK Limited, London, 1992, pp: 75-79.

Correspondence:

Dr. Mustafa KÖSEM
 Yüzüncü Yıl Üniversitesi Tıp Fakültesi
 Araştırma Hastanesi Patoloji ABD
 65200, Van, TURKEY
 e-mail: mustafakosem65@hotmail.com
 Telephone number: +90 432 215 85 73
 Telefax number: +90 432 216 74 62