

Two patients with subarachnoid hemorrhage in pregnancy

Hayriye Gonullu^{a,*}, Sevdegul Karadas^a, Mehmet Resit Oncu^b, Mehmet Tasdemir^c

^aDepartment of Emergency Medicine, Yuzuncu Yil University Faculty of Medicine, Van, Turkey

^bVan Training and Research Hospital, Emergency Medicine, Van, Turkey

^cDepartment of Internal Medicine, Yuzuncu Yil University Faculty of Medicine, Van, Turkey

Abstract. It has been reported that headache in 50-60% of subarachnoid hemorrhage cases has an abrupt onset and is severe with the cause in the 75-80% of events being intracranial aneurysm rupture. This condition, which is also known as sentinel headache and particularly observed days before the rupture of an aneurysm, is of great importance to clinicians. Subarachnoid hemorrhage is rarely seen in pregnancy; on the other hand, it has a high mortality rate for both mother and fetus. This paper presents the case studies of two pregnant women who were admitted to the hospital with a sentinel headache, abrupt-onset and variable headache complaints, they were consequently diagnosed with subarachnoid hemorrhage.

Key words: Subarachnoid hemorrhage, pregnancy, sentinel headache

1. Introduction

Headache is a commonly observed complaint in gestation and is usually associated with benign conditions such as hormonal changes, increased blood volume in the body and excess weight. It has been reported that headache usually develops less frequently during pregnancy in women who have migraine and tension headache (1,2). Therefore, if the headache in pregnancy has an abrupt onset and there is a change in the nature of the headache, life-threatening conditions such as subarachnoid hemorrhage (SAH), cerebral venous sinus thrombosis, cerebral vasoconstriction syndrome, carotid or secondary factors such as vertebral artery dissection, pituitary apoplexy and intraparenchymal hemorrhage should be suspected. In order to exclude these conditions and establish a final diagnosis, neuroimaging methods should be used and cerebrospinal fluid (CSF) tests should be conducted (3).

Cerebrovascular disorders have a rapid progress due to conditions such as; preeclampsia, eclampsia, hypertensive attack, arteriovenous malformations, family history of cardiovascular diseases, being a mother over the age of 35, hypertension and hormonal changes (4).

Headache seen in 50-60 % of SAH cases is usually of abrupt-onset and acute, and 75-80 % of all SAH cases are caused by intracranial aneurysmal rupture (5). SAH is a rarely seen condition; however, it has a high mortality rate for both mother and fetus (6). This paper presents case studies of two pregnant women with the primary focus being on headache in pregnant women.

2. Cases

2.1. Case

A 17-week pregnant woman (gravida 6, parity 5 and abortus 1) presented to the emergency department (ED) of the hospital with a moderate frontal headache that had started 5-6 hours earlier. Upon admission, her tension arterial (TA) was 130/70 mm Hg, pulse was 88/min and fever was 36°C. Her Glasgow Coma Score (GCS) was 15 (Eyes: 4, Motor: 6 and Verbal: 5), meningeal irritation evidence (MIE) was positive and eye ground evaluation and laboratory parameters were within normal levels. The case with newly emerged headache and MIE (+) was administered lumbar puncture (LP) with central nervous system infection and SAH pre-diagnosis. SAH

*Correspondence: Hayriye Gonullu, MD

Adress: Yuzuncu Yil Universitesi, Tip Fakultesi, Prof. Dursun Odabaş Tıp Merkezi, Acil Tip A.D. Van, Turkey

Tel: 00.90.505.7672477

Fax:00.90.432.2168352

E-mail: drhayriyegonullu@windowslive.com

Received: 07.03.2011

Accepted: 17.10.2011

was considered when CSF appeared with xanthochromic attribute, its color was not lightened and no cell was observed. To support the diagnosis, magnetic resonance imaging (MRI) was carried out (Fig. 1). Following SAH evidence, the patient was transferred to the neurosurgery department. The case was closely followed up and when aneurysm was detected in the brain MR angiography of the patient in the course of the follow-up period, the case was referred to another health center for surgical intervention. However, it was later found out that the patient and her relatives did not accept surgical intervention in the pregnancy period.

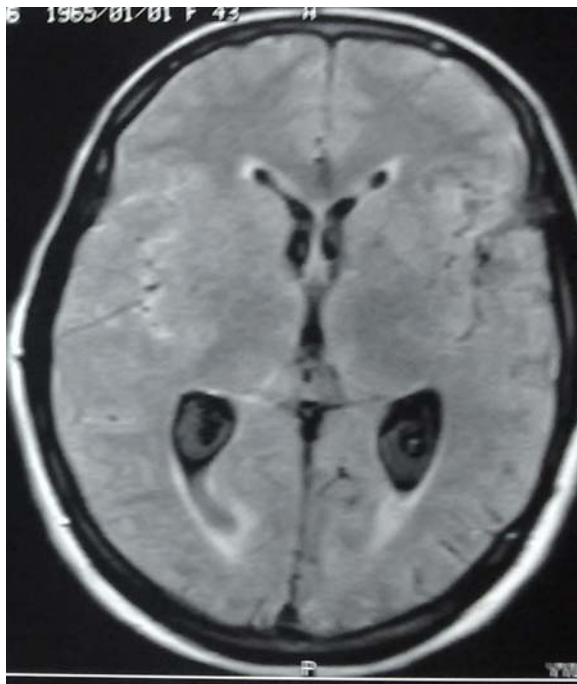


Fig. 1. A sulcal signal increase was observed both in the right parietal lobe which was more evident and in the bilateral cerebral hemisphere. Cerebral sulcus and fissures were not visible on the right side and were reduced on the left side.

The patient was discharged from the other center with the recommendation to attend to the hospital for a follow-up after the delivery. The same patient came back to the ED with a headache similar to the previous one at 28 weeks of gestation. Patient examination showed that her vitals were stable, GCS was 15, MIE was positive, and the findings of other system examinations and laboratory evidence were normal. Since computerized brain tomography (CBT) performed by protecting the abdomen (Fig. 2) supported the diagnosis of SAH, the patient was transferred to a more advanced medical center. The patient was taken under close follow-

up for aneurysm treatment until delivery. However, due to the premature rupture of membranes at 36 weeks of gestation, a male infant weighing 2800 gr. was delivered by elective cesarean section. The patient was discharged from the hospital and referred to a neurosurgery polyclinic.

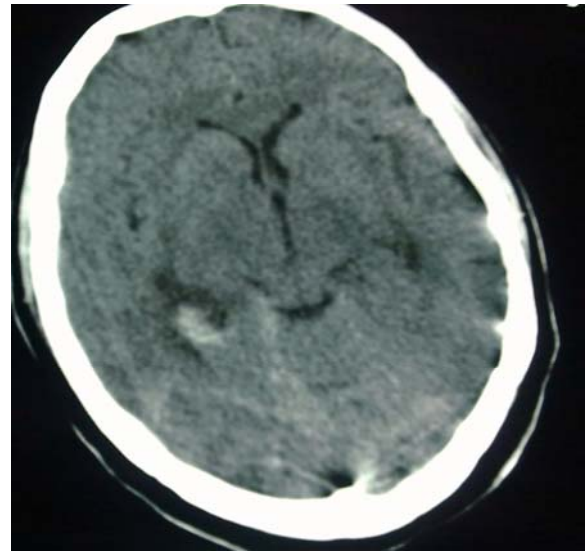


Fig. 2. On the right side at the level of the basal cistern, linear gyral structures and hyperdense opening to the right lateral ventricle occipital horn can be seen; this is compatible with SAH.

2. 2. Case

A 28-week pregnant woman aged 25 (gravida 1) was brought to the ED with the complaints of having a headache for 2 days, whole-body contractions for the last 4 hours and altered level of consciousness. The general medical condition of the case was not good and her GCS was 6 (Eyes: 4, Motor: 6, and Verbal: 5). Pupillary was isochoric and mid-dilated. There was no facial asymmetry or MIE. The plantar response, bilateral flexor and deep tendon reflexes of the patient were normal. Her TA was 150/90, pulse was 110/min, respiratory rate was 30/min and O₂ saturation was 85%. Pulmonary sounds identified through auscultation were bilaterally balanced, and a common rale was audible till the upper zones. Pretibial edema was not detected. No pathology was found in other system examinations. The patient whose GCS was 6 was intubated by sedation. When laboratory values were examined, leukocyte was 37.5 (4-11) mm³, glucose was 252 (70-110) mg/dl, alanine aminotransferase was 43 (0-41) U/L, aspartate aminotransferase was 77 (0-31) U/L, pH was 7.21, pCO₂ was 15 mmHg, pO₂ was 59 mmHg, and HCO₃ was 5.3 mmol/L. Proteinuria was 100

mg/dl in the complete urine analysis. Fetal heartbeats were not observed on the obstetric ultrasonography. CBT findings were compatible with SAH (Fig. 3). Dead fetus was delivered through induction by commencing anti-edema, nimodipine, antiepileptic and MgSO₄ intravenous treatment. The patient was then taken to the intensive care unit and treated with spontaneous intermittent mandatory ventilation using a mechanical ventilator. She died on the fifth day of her hospitalization.

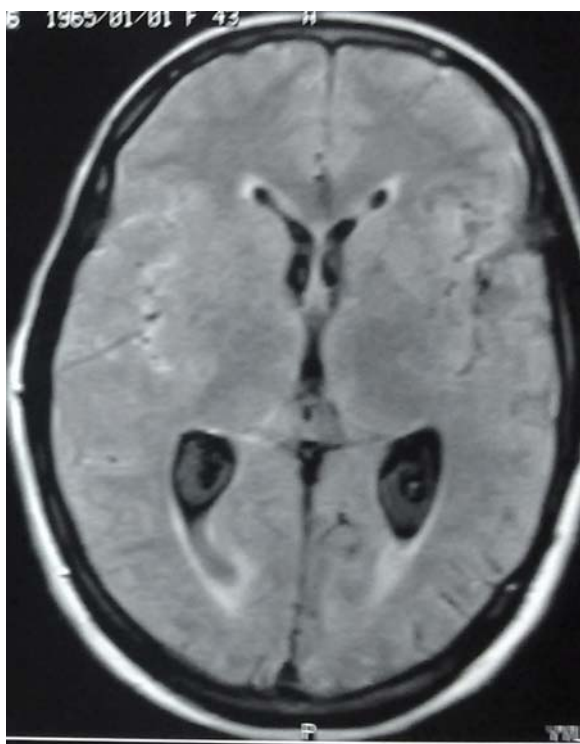


Fig. 3. The appearance compatible with SAH, noticeable in the right temporal lobe in the vicinity of sylvian fissure and in the right gyral structures. Please see the hyperdensity in the left gyral structures. The shift effect is also seen.

3. Discussion

It has been reported that cerebrovascular diseases contribute to 12% of deaths related to gestation and intracerebral hemorrhage is observed in 6.1-7.1% of every 100,000 cases (7, 8).

The annual incidence of SAH varies between 8/100,000 and 22-24/100,000 in normal population (9). There is an increasing risk in hemorrhagic cerebrovascular incidents in pregnancy (10). Sharshar et al., (11) reported 4.4 brain hemorrhagic cerebrovascular incidents per 100,000 deliveries.

Patients admitted to the ED of hospitals with a headache constitute 4% of all patients and 12% of

these patients make up SAH cases possessing immediate and severe onset headache with normal examination findings (12, 13). SAH cases usually present with an intractable headache, vomiting and an altered level of consciousness (14). Sentinel headache is seen in 6-40% of patients with SAH, which is characterized by abrupt and severe headache emerging days before aneurysm rupture (5). Jeng et al., (15) found that 4.7 % of 402 pregnant patients had intracerebral bleeding and 15.8% developed SAH. Eclampsia and arteriovenous malformations were found to be the most frequent cause in etiology in the same study. While Simolke et al., (16) reported in their study that chronic hypertension and pre-eclampsia were the major causes of intracerebral hemorrhage, Mousseuttas et al., (17) suggested that intracerebral hemorrhage was primarily caused by severe hypertension and aneurysm rupture. Jung et al., (18) reported that SAH was more frequently observed in women who had a baby for two or three times compared with those who had never given birth or who had given birth once. In the current study, the first case had a less severe headache; on the other hand, both cases had headache complaints. The second case did not apply to the hospital even though she had a headache for two days and she was brought to the hospital by her close contacts after her medical condition deteriorated and she suffered a seizure. It was considered that the cause of SAH was aneurysm rupture for the first patient, who was pregnant for the sixth time and hypertension and eclampsia for the second patient, who was pregnant for the first time.

It has been reported that intracranial bleeding occurs more frequently in pregnant women than non-pregnant women. When the mortality and morbidity rate related to cerebral aneurysm are taken into account, all patients having acute neurological deterioration must be carefully evaluated and the presence of headache in late-term pregnancy must be a warning sign for fatal conditions (19, 20).

Patients taken to the ED after having an abrupt-onset and severe headache or a headache of a different nature must receive a CBT, and even if their CBT turns out to be normal, LP and CSF must be assessed and other imaging techniques must be used (5).

Imaging techniques have been found to be adequate for identifying the causes of CBT's secondary reasons, and as opposed to the common belief, it has a negligible detrimental effect on the fetus (2). The average amount of radiation that a pregnant woman is exposed to in the course of a brain CT is less than 0.01 Gy. The

acceptable upper limit for exposure to ionized radiation as determined by the National Council on Radiation Protection and Measurements is 0.05 Gy for all CT scans (21). SAH is diagnosed through CT and LP as well as cerebral angiography (22). The onset complaints of the first case were acute and intracranial mass was considered. Intracranial pressure symptom was not detected in the evaluation of eye ground. On account of possible negative effects of radiation on the fetus, CBT was not approved by the patient and her relatives and thus, LP was arranged for the patient. Even though the CSF analysis indicated that the case was xanthochromic, it was interpreted to be as a result of being traumatized. Patient's diagnosis was confirmed by a brain MR and follow-up was continued. Approximately 10 weeks after the first diagnosis of aneurysm rupture, the patient applied to the ED of the hospital with ongoing neurological complaints and SAH associated with aneurysm rupture was taken into consideration at first and the diagnosis was confirmed by a CBT. Since the second case was stable and her consciousness was at coma level, SAH diagnosis was confirmed by a CBT. As the patient's condition was not stable during intensive care follow-ups, MR angiography could not be carried out.

Approaches to SAH cases related to the rupture of an aneurysm during pregnancy are antiepileptic therapy, nimodipine, antiedema, antihypertensive treatment in conjunction with aneurysmal clipping by surgical intervention as in non-pregnant patients (22,23). This study covered two cases who received medical treatment. The first patient was referred to an advanced center for surgical intervention. The second patient, however, died during the follow-up period.

Sentinel headache should be suspected in patients who develop a headache days before an aneurysm rupture and this state must be a warning sign for the physicians to make a diagnosis of SAH. As SAH has a high mortality and morbidity rate for both mother and infant in pregnant women, further observation is needed for the diagnosis of suspected cases.

References

- De Luca GC, Bartleson JD. When and how to investigate the patient with headache. *Semin Neurol* 2010; 30: 131-144.
- Contag SA, Mertz HL, Bushnell CD. Migraine during pregnancy: is it more than a headache? *Nat Rev Neurol* 2009; 5: 449-456.
- Menon R, Bushnell CD. Headache and pregnancy. *Neurologist* 2008; 14: 108-119.
- Özücelik DN, Kunt MM, Karaca MA, Çobanoğlu M. Intracerebral Hemorrhage During Pregnancy: Case Report. *Journal of Academic Emergency Medicine Case Reports* 2010; 2: 40-43.
- Kabak S, Aygün D, İyigün Ö, Nargis C. The importance of sentinel headache in patients with intracranial aneurism. *Turkish Journal of Emergency Medicine* 2005; 5: 199-201.
- Darbhamulla SV, Reddy R. Subarachnoid hemorrhage in pregnancy. *J Obstet Gynaecol* 2007; 27: 80-81.
- Witlin AG, Friedman SA, Egerman RS, Frangieh AY, Sibai BM. Cerebrovascular disorders complicating pregnancy-Beyond eclampsia. *Am J Obstet Gynecol* 1997; 176: 1139-1148.
- Bateman BT, Schumacher HC, Bushnell CD, et al. Intracerebral hemorrhage in pregnancy frequency, risk factors, and outcome. *Neurology* 2006; 67: 424-429.
- Yılmaz DM. Spontan Subaraknoid Kanama ve Sonrası Gelişen Vazospazm ve Geç İskemik Defisitte Serum ve Beyin Omurilik Sıvısında Sitokin Düzeylerinin Araştırılması. *Uzmanlık tezi Adana* 2005.
- Tate J, Bushnell C. Pregnancy and stroke risk in women. *Womens Health (Lond Engl)* 2011; 7: 363-374.
- Sharshar T, Lamy C, Mas JL. Incidence and causes of strokes associated with pregnancy and puerperium. A study in public hospitals of Ile de France. *Stroke in Pregnancy Study Group. Stroke* 1995; 26: 930-936.
- Denny CJ, Schull MJ. Headache and Facial Pain. In: Tintinalli JE, Kelen GD, Stapczynski JS, eds. *Emergency Medicine: A Comprehensive Study Guide*. 6th ed. New York: McGraw-Hill; 2004. pp. 1375-1382.
- Edlow JA, Caplan LR. Avoiding pitfalls in the diagnosis of subarachnoid hemorrhage. *New Engl J Med* 2000; 342: 29-36.
- Scott PA, Timmerman CA. Stroke, Transient Ischemic Attack, And Other Central Focal Conditions In: Tintinalli JE, Kelen GD, Stapczynski JS, eds. *Emergency Medicine: A Comprehensive Study Guide*. 6th ed. New York: McGraw-Hill; 2004. pp.1382-1390.
- Jeng JS, Tang SC, Yip PK. Incidence and etiologies of stroke during pregnancy and puerperium as evidenced in Taiwanese Women. *Cerebrovasc Dis* 2004; 18: 290-295.
- Simolke GA, Cox SM, Cunningham FG. Cerebrovascular accidents complicating pregnancy and the puerperium. *Obstet Gynecol* 1991; 78: 37-42.
- Moussouttas M, Abubakr A, Grewal RP, Papamitsakis N. Eclamptic subarachnoid haemorrhage without hypertension. *J Clin Neurosci* 2006; 13: 474-476.
- Jung SY, Bae HJ, Park BJ, Yoon BW. Acute Brain Bleeding Analysis Study Group. Parity and risk of hemorrhagic strokes. *Neurology* 2010; 74: 1424-1429.
- Kanani N, Goldszmidt E. Postpartum rupture of an intracranial aneurysm. *Obstet Gynecol* 2007; 109: 572-574.
- Matsubara S, Kuwata T, Ohkawara Y, Makino S. Headache in late pregnancy: a symptom for Vogt-Koyanagi-Harada disease. *Arch Gynecol Obstet* 2011; 283: 1423-1425.

21. Gorson R. O. report No. 054-Medical radiation exposure of pregnant and potentially pregnant women (National Council on radiation Protection and Measurements), Bethesda, MD, 1977.
22. Mosiewicz A, Jakiel G, Janusz W, Markiewicz P. Treatment of intracranial aneurysms during pregnancy. *Ginekol Pol* 2001; 72: 86-92.
23. Greenberg MS. *Neurosurgery of Handbook. SAH and Aneurysms* (3 rd ed). Florida: Greenberg Graphics, 1994.