

Case Report

Ileo-colic intussusception following oral polio vaccination: A mere coincidence or morbid consequence

Chandan Kumar Shaw^{a,*}, Prachi Shaw^b, Tejesh Malla^c, Kalpana K Malla^c, Jalaj Baxi^d

^aDepartment of Pediatrics, Sri Manakula Vinayaga Medical College and Hospital, Pondicherry, India

^bDepartment of Microbiology, Sri Manakula Vinayaga Medical College and Hospital, Pondicherry, India

^cDepartment of Pediatrics, Manipal College of Medical Sciences (MCOMS), Pokhara, Nepal

^dDepartment of Surgery, Manipal College of Medical Sciences, Pokhara, Nepal

Abstract. The National polio surveillance programme is one of the prime health projects in Nepal and its neighboring countries. A huge amount of effort and money is being pumped into polio surveillance in these areas. Vaccine associated Paralytic polio is one of the prime concerns as far as the side effects are considered. In the past there has been concern over the relationship of Oral Polio Vaccine (OPV) with intussusception as with rotavirus vaccine. We report a case of ileo-colic intussusception which occurred within 24 hours of oral polio vaccination during the pulse polio immunisation. We also discuss the facts available to us regarding the association of OPV with intussusception.

Key words: Oral polio vaccine, intussusception

1. Introduction

The proposed aim of eradicating of polio by 2005 was not achieved by some nations which were endemic to polio. As long as even a single case of polio is detected the threat of an epidemic looms large and hence the concerted efforts by all health authorities in the concerned areas are primarily focused on mass vaccination coverage through routine vaccination round the year along with pulse polio on predetermined national immunisation days. A huge amount of effort and money is being pumped into polio surveillance in these areas. However the poor awareness, poverty, negative attitude of the people to both routine and pulse polio immunisation are the deterrent factors to attain the desired goal not to mention, the difficult terrain making access to health services far more difficult. Under these

circumstances adverse reaction to oral polio vaccination gives negative publicity and backward thrust to the eradication efforts. Nevertheless the occurrence of intussusception after oral vaccination makes us wary of the possibility of a causal relationship with the latter. We report a case of ileo-colic intussusception which occurred within 24 hours of oral polio vaccination during the pulse polio immunisation.

2. Case report

A seven month old male baby was admitted to the Pediatric ward in the Manipal Teaching Hospital on 24th December, 2008 with complaints of repeated vomiting after about 4 hours of ingestion of oral polio vaccination administered at a local health post in Pokhara, Nepal on the same day. The child was apparently asymptomatic before the onset of vomiting and there were no associated symptoms of diarrhea, blood in stools, persistent crying or drawing-up of lower limbs to the abdomen, which would be suggestive of colic. The child was kept nil orally and given injection ondansetron and intravenous fluids as maintenance. The haemogram and electrolyte levels were within normal limits. The child remained asymptomatic after admission but 24 hours after admission the child was noted to pass red currant jelly stools which was not

*Correspondence: Dr. Chandan Shaw
Assoc. Professor, Dept. of Pediatrics,
Sri Manakula Vinayaga Medical College and Hospital.
(SMVMCH), India
Tel: +918870722212.
E-mail: chandan.1974@gmail.com
Received: 09.12.2011
Accepted: 13.04.2012

accompanied by any distention of the abdomen and normal bowel sounds were heard. A barium enema was suggestive of intussusception and the baby was operated due to failure to resolve with the (barium) enema. The intraoperative findings were that of ileo-colic intussusception (Figure 1) along with hypertrophy of Peyer's patches. (Figure 2) A right hemicolectomy with ileo-colic anastomosis was performed. The postoperative period was uneventful and the child started tolerating full feeds by the 5th postoperative day and was discharged on the 9th post operative day after suture removal.

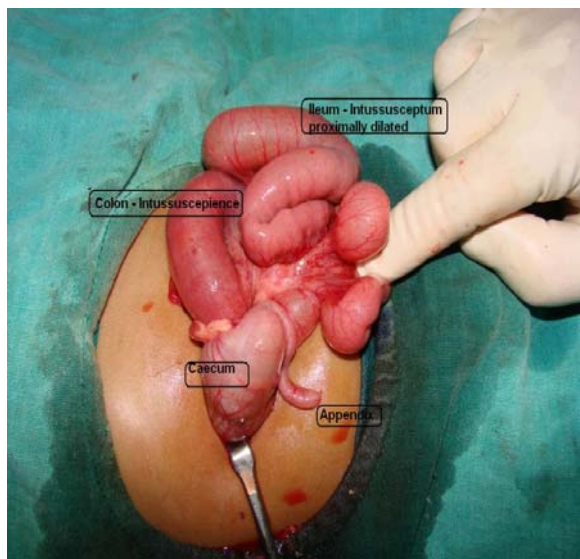


Fig. 1. Intraoperative findings in the case of ileo-colic intussusception.

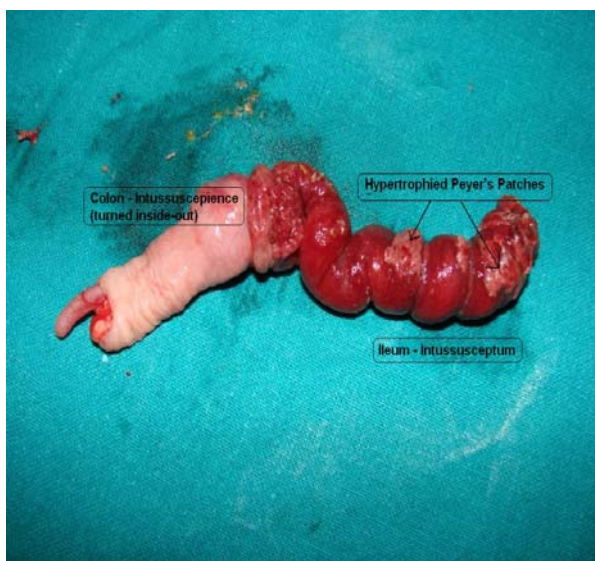


Fig. 2. Hypertrophied Peyer's patches in the pathological specimen – post resection.

3. Discussion

Oral polio vaccine (OPV) has been under the scanner for more than one reason. Serious adverse reactions to OPV include vaccine associated paralytic polio (VAPP). The risk of Circulating Vaccine Derived Polio Virus (cVDPV) and Circulating Vaccine Derived Polio Virus in the immunocompromised (iVDPV) being imported to the countries declared free of polio virus is gaining importance as more countries inch their way to polio eradication. Intussusception has been linked to many oral vaccines like the Rotavirus (1, 2) vaccine and the OPV (3). The fact that these live attenuate vaccines first generate an enteric infection wherein the Peyer's patches are the first site of localisation of the infection, makes it a likely explanation for intussusception. The hypertrophied Peyer's patches form the lead points of intussusception as was observed in our case too. However this is not the only factor responsible for intussusception. Other factors like malrotation, polyps, arteroivenous malformations and mesenteric adenitis may also be associated with intussusception as is the strong association with the period of weaning. In the reported case the child was started on weaning feeds by the four months age. It would thus be preposterous to point out the causal relationship with OPV with one single observation. Various studies have proven a strong positive association of intussusception with oral Rotavirus vaccine (1, 2) following which it has been withdrawn from the market. In a case control study of 113 cases on proven intussusception within 42 days of OPV ingestion, with carefully matched controls (515 cases of intussusception with remote (>42days) history of OPV vaccination), the relative risk estimates for intussusception ranged from 0.7 (95% CI 0.2, 2.1) for babies whose last oral polio vaccine was given 29-35 days before their index date to 1.0 (95% CI 0.4, 2.3) for those whose last oral polio vaccine was given 15-21 days before their index date compared to the controls (4).

Another study carried out in the United Kingdom comparing an exploratory group, hospital admissions data and the General Practice Research Database (GPRD) observed that the only period with some evidence of an increased risk was the 14-27-day period after the third dose (relative incidence (RI) = 1.97, $p = 0.011$). The second hospital admissions study and the GPRD study showed no evidence of an increased relative incidence in any putative risk period and did not confirm the increased risk in the 14-27-day period after dose 3 with a combined RI of

1.03. (5) The increased RI in the first study might be explained as a chance finding due to the number of risk periods examined and highlights the need for caution when looking at many risk periods without an a priori hypothesis. A study performed in the United States concluded that there was no significantly elevated risk of intussusception associated with receipt of OPV (6). A case-series study performed in Cuba, where OPV is administered twice yearly (February and April) in mass vaccination campaigns, found no association between OPV and intussusception (7).

In particular, the authors found no increased relative incidence of intussusception 22–28 days following the first OPV dose (relative incidence = 0.77, 95 percent CI: 0.29, 2.04) or the second OPV dose (relative incidence = 1.20, 95 percent CI: 0.44, 3.28), after controlling for age and season. They also found no association between OPV vaccination and intussusception at specific ages. A case-control study performed in India found no association between intussusception and OPV received during the prior month (odds ratio = 0.9, 95 percent CI: 0.5, 1.3) (8). In another recent analysis carried out on a Scottish population had similar conclusions (9).

It thus holds to reason that the hypothesis linking intussusception to OPV is probably a matter of conjecture. However it is also pertinent to point out that all the studies carried out till date, vary in methodologies and statistical analyses. Probably a meta-analysis of all the studies by Cochrane review is warranted.

4. Conclusion

The occurrence of any adverse reaction to any medication is worth notifying to the adverse reaction surveillance programme. However one must exercise certain amount of discretion in reporting such findings, lest it provokes a furor amongst proponents of the therapy and false fears and negative attitudes amongst the beneficiaries of the therapy. Already there is objection to the usage OPV in the endemic regions by developed countries where polio has been eradicated in view of VAPP, cVDPV, iVDPV (10). OPV is one of the strongest armamentarium in our pharmacopia

for the combat against poliomyelitis—a crippling disease known to mankind from time immemorial. Sadly, the battle is presently being fought by countries with other compelling needs such as hunger and poverty with some aid from the more “well-offs”. Controversies aside, each one of us, as practitioners in this region which is still plagued by sporadic cases of polio, must realise our responsibilities, do our best to get rid of this malady.

Acknowledgement

We sincerely wish to thank Department of Radiodiagnosis, MCOMS, POKHARA for their valuable aid in diagnosis of the case.

References

1. Intussusception among recipients of rotavirus vaccine-United States, 1998-1999. *MMWR Morb Mortal Wkly Rep* 1999; 48: 577-581.
2. Withdrawal of rotavirus vaccine recommendation. *MMWR Morb Mortal Wkly Rep* 1999; 48: 1007.
3. Oral poliovirus vaccine (OPV) and intussusception. *Wkly Epidemiol Rec* 2000; 75: 345-347.
4. Jick H, Vasilakis-Scaramozza C, Jick SS. Live attenuated polio vaccine and the risk of intussusception. *Br J Clin Pharmacol* 2001; 52: 451-453.
5. Andrews N, Miller E, Waight P, et al. Does oral polio vaccine cause intussusception in infants? Evidence from a sequence of three self-controlled cases series studies in the United Kingdom. *Eur J Epidemiol* 2001; 17: 701-706.
6. Li ST, Davis RL, Weiss NS. Intussusception and oral poliovirus vaccination: is there an association? *Am J Epidemiol* 2004; 160: 576-581.
7. Sardiñas MA, Cárdenas AZ, Marie GC, et al. Lack of association between intussusception and oral polio vaccine in Cuban children. *Eur J Epidemiol* 2001; 17: 783-787.
8. Raman T, Mukhopadhyaya A, Eapen CE, et al. Intussusception in southern Indian children: lack of association with diarrheal disease and oral polio vaccine immunization. *Indian J Gastroenterol* 2003; 22: 82-84.
9. J. Claire Cameron, David Walsh, Alan R. Finlayson, James H. Boyd. Oral Polio Vaccine and Intussusception: A Data Linkage Study using Records for Vaccination and Hospitalization. *Am J Epidemiol* 2006; 163: 528-533.
10. Paul Y. OPV may be discontinued but for a different reason. *Ind Ped* 2006; 43: 1005-1006.