

Thyroglossal Duct Cysts – A ten years retrospective review

Eyzawiah hassan^{a,*}, Goh Bee See^b, Dayang Anita Aziz^c

^a*Faculty of Medicine and Health Sciences, Otorhinolaryngology and Head and Neck Surgery Unit, Universiti Sains Islam Malaysia (USIM)*

^b*Department of Otorhinolaryngology Head & Neck Surgery, Faculty of Medicine, Universiti Kebangsaan Malaysia, Kuala Lumpur, Malaysia*

^c*Department of Surgery, Faculty of Medicine, Universiti Kebangsaan Malaysia, Kuala Lumpur, Malaysia*

Abstract. Thyroglossal duct cyst (TDC) is the most common congenital midline anterior neck mass which may present at any age particularly in the pediatric age group.

To review the pre-operative evaluation and the subsequent management in patients diagnosed with TDC.

Medical records of all the patients diagnosed with TDCs from January 2001 till December 2010 were retrospectively reviewed. The patients' clinical presentations, types of radiological investigation performed, the surgery and the outcome were documented.

There were 23 records of patients identified, but only 12 records were included due to incomplete data. They were 7 female and 5 male. The age ranged from 2 to 58 years. Mean age of presentation was 11.8 years. Eighty three percent of patients were in the pediatric age group. Ten cases (83%) presented as a painless neck swelling and a case with discharging cyst (8.3%) and infected cyst (8.3%). The site of the cyst was infrahyoid in seven cases (59%), suprahyoid in three cases (25%), one over the hyoid bone (8%) and another one case situated at the base of tongue (8%). Neck ultrasound was the most common radiological investigation performed prior to surgery. All patients underwent Sistrunk operation. The histopathological examination of the excised specimens was confirmed as thyroglossal duct cyst; in one patient papillary carcinoma was identified. There were no post-operative complications or recurrence.

TDCs may manifest at any age but most commonly in pediatric age group. Diagnosis is usually be made clinically. Ultrasound of the thyroid gland and the neck structures is an adequate tool of investigation; however other adjunct investigations may be required. Sistrunk operation is the surgery of choice at our centre with no recurrence documented.

Key words: Thyroglossal duct cysts, ultrasound, Sistrunk, neck

1. Introduction

Thyroglossal duct cyst (TDC) is the most common congenital midline neck mass which may present at any age. The exact incidence of TDC is unclear, but its incidence appears to be equal in both genders and is higher in children than adults (1).

Classically, TDCs present as a mobile, painless midline cystic neck swelling that moves with deglutition and protrusion of the tongue. While it typically presents at midline close to the hyoid bone, 10% - 24% of the cysts are located laterally, usually on the left (4). Occasionally TDCs can present with sign and symptoms of infection or with a discharging cyst. A rapid increase in duct growth should raise suspicious of malignancy which there is an estimated 1% chance of malignant transformation in TDCs (5). Failure to identify the possibility of TDCs may result in recurrence as a consequence of inadequate surgical procedure such as incisional biopsy or enucleation (5). The gold standard management for TDCs is the Sistrunk procedure as evidenced by low recurrence rates (7).

*Correspondence: Dr. Nor Eyzawiah Binti Hassan
Department of Otorhinolaryngology- Head & Neck Surgery
Faculty of Medicine, Universiti Kebangsaan Malaysia,
Jalan Yaacob Latif, 56000 Cheras, Kuala Lumpur, Malaysia
Tel: 603 91456045
Fax: 603 91456675
E-mail: noreyzawiah@yahoo.com
Received: 22.08.2013
Accepted: 03.12.2013

We performed a 10 year retrospective review of patients diagnosed with TDCs managed in our centre. We documented the patients’ clinical presentations, types of radiological investigations performed, the surgery of choice and the outcomes.

2. Materials and methods

A series of patients with TDCs were retrospectively reviewed from January 2001 to December 2010 in Universiti Kebangsaan Malaysia Medical Centre (UKMMC). All patients were treated by various surgeons from Department of Otorhinolaryngology, Head and Neck and Department of Paediatric Surgery. There were 23 patients identified with TDCs, which only 12 medical records were available as most of the patients were discharged well and their medical records have been discarded. The medical records were analysed for demographic data, clinical presentations, mode of investigations, surgical managements and its outcome. The needs of certain advance investigations were highlighted. Operative data and postoperative histopathological results were analysed.

3. Results

Twelve patients (seven female and five male) with postoperative diagnosis of TDCs were included in this study. Most of the patients were from the pediatric age group (83%) which ranging from two to 15 years old. The mean age

at presentation was 11.8 years with the age range of two to 58 (see Table 1). Out of the 12 patients, six were Malay, four were Chinese and two were Indian.

In 10 patients (83%), the clinical presentation was classical of a painless anterior midline neck mass, whereas one of the patients presented with painful infected submental swelling and the other patient presented with a discharging midline neck cyst. All the swelling showed the typical nature of the mass that move with deglutition and protrusion of the tongue. The mean duration of the symptoms was 11 months, with the range of duration from one month to 10 years. The site of the cyst was infrahyoid in seven cases (59%), suprahyoid in three cases (25%), one over the hyoid bone (8%) and another one case situated at the base of tongue (8%).The clinical size of the cysts varied from 1.5 to 4.0 cm in diameter.

Preoperative ultrasound (US) of the neck was performed in nine cases. Out of the nine cases, eight US showed the typical well defined hypochoic cystic lesions that are separate from the thyroid gland, which is a classic hallmark of TDC. In another case, it showed a solid nodule lesion at midline of neck with normal appearance of the thyroid gland. The measurement of the size of the cyst did not vary more than 15% from our clinical assessment. All these nine cases showed normal thyroid gland. CT scan of neck was performed in two adult patients, which the mitotic lesion was suspected. In addition, radioisotope thyroid scanning (with Technetium –

Table 1. Clinical presentation and assessment of TDCs

Age & Sex	Presentation	TFT	US	CT	RTS	FNC	TF
1. 2/F	Suprahyoid mass		+				
2. 3/M	Infected suprahyoid mass	+	+		+		
3. 4/F	Infrahyoid mass			+			
4. 6/F	Infrahyoid mass			+			
5. 6/F	Intralingual mass	+					
6. 6/M	Infrahyoid mass			+			
7. 6/M	Infected infrahyoid mass and cutaneous fistula		+				+
8. 7/M	Suprahyoid mass		+				
9. 9/M	Infrahyoid mass					+	
10. 15/F	Mass at the level of hyoid bone				+		
11. 20/F	Infrahyoid mass		+	+		+	
12. 58/M	Infrahyoid mass				+	+	+

US = Ultrasonography

CT = Computed Tomography

RTS = Radioisotope Thyroid Scanning

FNC = Fine Needle Aspiration Cytology

TFT = Thyroid Function Test

TF = Thyroglossal Fistulography

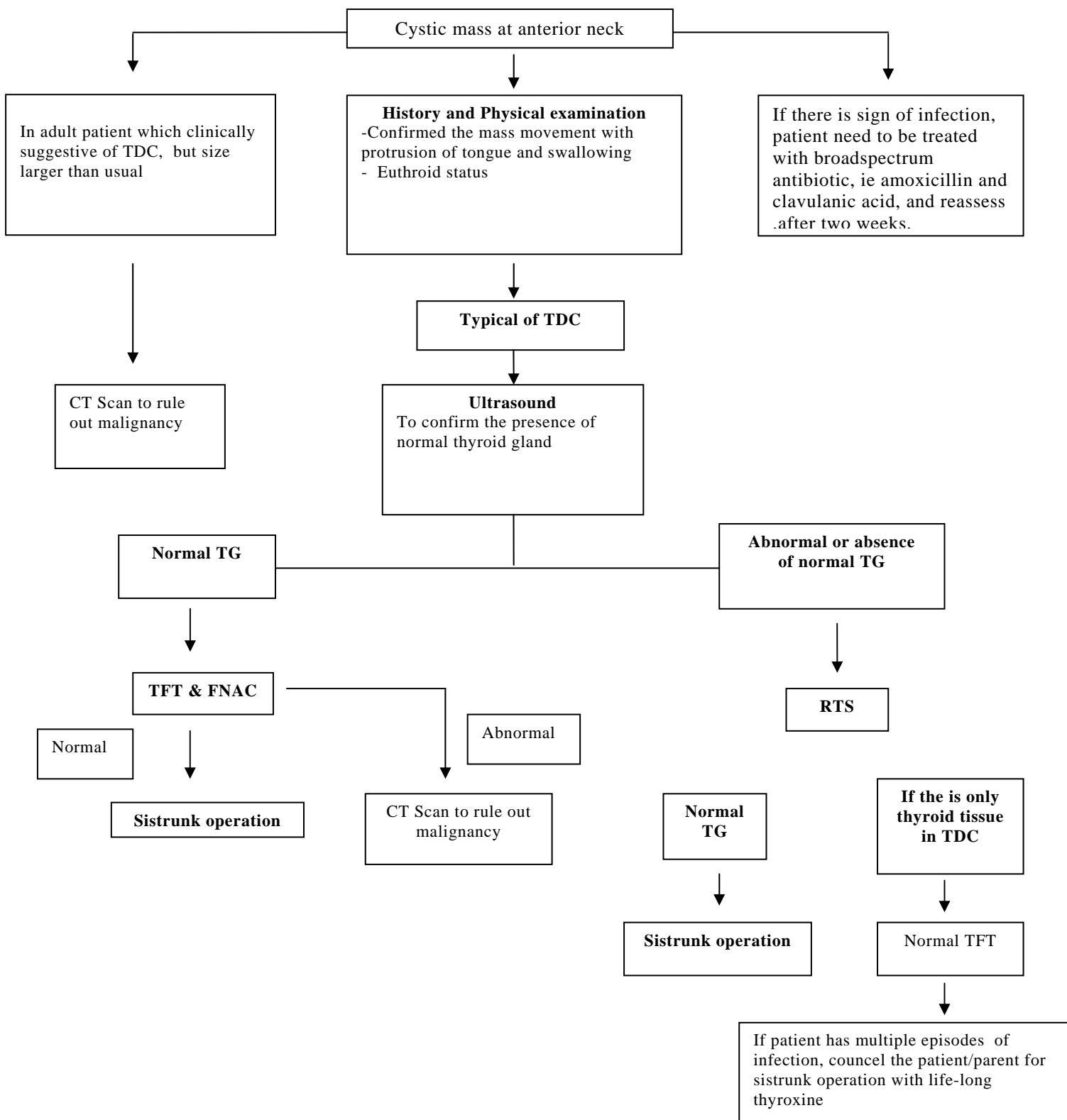


Fig. 1. Algorithm for evaluation of a cystic anterior neck mass. TDC, thyroglossal duct cyst;TG, thyroid gland; US, ultrasound; FNAC, fine needle aspiration cytology; TFT, thyroid function test; RTS, radio-isotope thyroid scan

99m) were performed in 4 patients (age ranging from nine to 43 years old; which no extra thyroidal activity showed in all 4 cases. Thyroglossal fistulography was performed in one case which presented with a cutaneous fistula, in which a short blind sinus was demonstrated. The other preoperative assessment performed was a serum thyroid function test. It was evaluated in 3 cases and all results were within normal limit. On the other hand, 2 cases which fine-needle aspiration cytology (FNAC) was performed, only one case was reported as TDC after second attempt, where as in the other case, it was reported as inconclusive even though after attempted multiple samples.

The standard surgical approach is a Sistrunk procedure. This procedure involves the resection of the whole length of the duct and cyst in continuity with the body of the hyoid bone. An island of skin was removed together with the track in cases with cutaneous fistula. Intra-operatively, 2 cases had poor defined margin around the cyst with adherence to the surrounding strap muscle. Out of the 12 cases, a suction drains were inserted in 4 patients post-operatively and removed after 24 hours. Only three cases received post-operative antibiotic therapy, when intra-operative adhesions, post infected cyst and post-operative hematoma were encountered.

All the surgical specimens were sent for histopathological examination. The preoperative diagnosis of TDC was histopathologically confirmed in 11 cases (92%), one case reported as papillary carcinoma arising from thyroglossal duct cyst reported in a 15 year old Indian female. This patient subsequently underwent total thyroidectomy and subsequent radioablation iodine. She was well with yearly follow up and no recurrence was noted after 5 years.

Post-operative hospital stay was short in all patients, they were discharged on day one postoperatively. Patients with surgical drains, was discharged after two days. Follow up ranged from one month to 64 months. During the follow-up period, one patient was complicated with mucoid discharge from previous drain site on day 14 postoperatively. Patient was successfully treated with a week course of oral amoxicillin with clavulanic acid. Haematoma occurred in one patient in the early postoperative days, due to poor functioning vacuum drain and resolved with antibiotic therapy.

4. Discussion

The term 'thyroglossal duct cyst' is a common term used in many literature to describe a mass arising from remnant of thyroglossal tract, which

does not undergo complete involution, during the embryological development of the thyroid gland. It can be located anywhere from the foramen caecum in the base of tongue up to suprasternal region. Many other different terms have been used in the literature with regards to this pathology such as 'thyroglossal cyst', 'thyroglossal tract cyst', 'thyroglossal duct remnant' and 'thyroglossal tract remnant'(8).

A wide range of differential diagnosis can be made for neck masses. Among them, TDC is the most common cause of congenital anterior midline cyst in the neck (9,10). In the series of autopsy specimens studied by Sprinzel et al. in 2000 (11), revealed TDC or ectopic thyroid tissue in 41.3% of 58 specimens. In other large series by Hsieh et al. in 2003 (10), TDC accounted for 54.6% of 331 paediatric patients with congenital cervical cysts. Although TDCs can present at any age, most literature reported that the peak incidence is in the 1-10 year age group. However, more recent literature show its more prevalence in adult population than previously believed (12-16). These findings may be influenced by local demographic data. Thereby, a meta-analysis by Allard in 1982 (1), concluded that age of presentation for TDCs appeared to be a bimodal distribution with a peak at 6 and 45 years of age. In our series, age ranged from 2 to 58 years old with mean of 11.8 years. Of 12 patients, ten patients (83%) were below 18 years old and almost equal distribution among female 58% and male 42%

TDC commonly presents with mobile midline anterior neck mass which moves with deglutition and protrusion of the tongue, usually in proximity to the hyoid bone. A study by Josephson and Spenser in 1998 (17), found that 65.7% of their patient presented with mass or recurrent mass. It may also occasionally presents as a secondary infection or a cutaneous fistula. The study with 1534 cases by Allard (1) reported 32.6% presented with fistula. In the other study by Ostlie et al. (18), he revealed similar prevalence (33%) of cases presented with cellulitis or abscess. The possible pathogenesis of fistulisation to skin or to foramen caecum may follow episodes of infection, trauma, post surgery or even can occur spontaneously. The fistulous discharge is usually more pronounced during mastication or deglutition (19).

The typical movement of the cystic lesion in the neck with deglutition and protrusion of tongue is often cited as a reliable diagnostic sign. However this sign may be difficult to elicit in the pediatric group as it may misleading to a wrong diagnosis such as dermoid cyst, lymphadenopathy

and cystic hygroma as it presented proximity to hyoid bone (19). As in the literature review, our study also showed typical presentation of a neck mass (83%) and presentation as infection and cutaneous fistula accounted for 8.3% each. The atypical symptoms reported in the literature include dysphagia, cough, airway obstruction and pain. In a study by Brousseau et al. (12), adults commonly present with atypical symptoms.

The reported average size of TDC is ranging from 2-4cm in the widest diameter as similar finding in this study measured about 1.5-4cm (19). As regards to the sites of TDC, we noted similar finding with a study by Allard (1). He reported the following locations; infrahyoid 60.9%, suprahyoid 24.1%, lingual 2.1% and suprasternal 12.9%. However in this study, no suprasternal cyst was reported. In the case with large lingual TDCs at base of tongue, it might cause mass effect which can lead to airway obstruction as patient might present with stridor, dyspnea, periodic cyanosis and as severe as can cause sudden infant death (20). While TDCs classically present in midline, few reports in literature describes laterally placed TDCs, anterior to sternocleidomastoid muscle which can be a differential diagnosis of branchial cyst (21).

As in most cases of TDCs presented with typical signs and symptoms, a meticulous clinical assessment is usually sufficient to make a correct preoperative diagnosis of TDC (22). However preoperative imaging plays an important role to support the diagnosis. Usually, such decision making relies on clinicians' experience with different years of experience managing the TDCs. No clear consensus in literature regarding preoperative imaging in patient with TDCs. There is a well accepted agreement that ultrasound is the preoperative investigation of choice for TDC. Ultrasound is done to ensure that patients have a normal thyroid gland (23). It is beneficial particularly in children as this investigation is free from ionizing radiation, sedation, less costly and is readily available (23,24).

In this series, six variation of diagnostic study were performed, which includes US, CT, radioisotope thyroid scanning, thyroglossal fistulography, FNAC and serum thyroid function test. Nine out of 12 cases had an US performed which 8 cases had clearly showed typical hypoechoic cystic lesions that consistent with TDC and identification of normal thyroid gland tissue. The reported features of TDCs may be varied on US imaging; hypoechoic and well circumscribes in simple TDCs; a heterogenous pattern with internal echoes in cases of previous infection or hemorrhage; and a pseudosolid

appearance reflecting proteinaceous contents (mucus, thyroglobulin), cholesterol crystals and keratin (15) as showed in one of our cases with infected suprahyoid TDC. Two cases in our series had CT performed as investigation of choice to more accurately delineate the anatomy of large cysts. This is a preferable mode of assessment in our adult patients. Any solid component or enhancing nodule detected within TDC on CT or MRI, a malignancy should be rule out (26).

In our series, radioisotopes thyroid scanning was performed in 4 cases. This assessment was used to rule out any possibility of only functioning ectopic thyroid tissue if the normal thyroid gland is not seen in the US, without any benefit in confirmation of disease. Excision of this only functioning ectopic thyroid tissue could lead to permanent hypothyroidism. The reported incidence of preoperative misdiagnosed as TDC which postoperatively was ectopic thyroid tissue is about 1-2% (26). Furthermore, in the present of normal thyroid gland, ectopic thyroid tissue maybe found within the wall of a TDC in small cases, about 5% of cases (27). Therefore, even though advocated by other centres [3, 25], the need of routine preoperative radioisotopes thyroid scanning to rule out an only functioning ectopic thyroid tissue should be avoided (28).

FNAC is a simple and reliable test which is useful in making diagnosis of neck masses in the distinction of benign from malignant lesion (9). According to study by Shahins et al in 2005, FNAC is only moderately accurate in the preoperative evaluation of TDCs, although skilled personnel and routine audit should improve the diagnostic accuracy (29). However in our series, FNAC could not delineate a correct diagnosis on the first sample and required multiple samples in which still cannot offer a diagnosis. Furthermore, FNAC does not give added information in pediatric patients with normal thyroid glands visualized on US. Serum thyroid function test may be performed to confirm euthyroid status of patients preoperatively, in supplementary to radiological thyroid gland assessment.

The Sistrunk procedure is the mainstay of surgical approach for TDC. Historically, before 1893, TDCs were treated via simple incision and drainage, but recurrence was very high about 50% (30). The recurrence was remarkably reduced (approximately 20%) by removal of midportion of the hyoid bone in continuity with TDC. This procedure was first described by Schlange in 1893 (31), which the further complete removal of the TDC including its attachment to hyoid bone and foramen caecum by Sistrunk in 1920 (32). This is based on an embryological study by

Wengloski in 1912 (33). Horisawa et al reported that the recurrence rate with similar to Sistrunk operation was significantly lower than for the Schlange operation (34). In our series, all the cases underwent Sistrunk procedure as the surgical methods of choice and no recurrence was encountered.

All the surgical specimens sent for histopathological study is crucial to rule out malignancy particularly in elderly patients. Usually TDCs contain mucoid or gelatinous material. The presence of mucopurulent material is indicative of an infection. The epithelial lining the cyst is vary, typically pseudostratified ciliated columnar and/or squamous epithelium with thyroglossal track or thyroid follicles in the surrounding stroma. The unusual presence of lymphoid nodules is found in 15-20% of cases (35), transitional epithelium (36), gastric epithelium (37), and small intestinal type of epithelium (1) had been reported. In this study, all patients were confirmed as TDC, except in 15 year-old female patient who had histologically reported as papillary carcinoma arising from TDC. The incidence of TDC malignancy is 1%. Controversy was raised regarding its appropriate management, and whether thyroidectomy is crucial. However in recent literature concluded that in most patients with normal thyroid gland, the Sistrunk operation is adequate as a surgical treatment (38-40). Furthermore, a total thyroidectomy is only advocated in the presence of suspicious clinical or radiological synchronous neoplastic lesion in the thyroid gland (7,41).

The Sistrunk procedure is generally safe and major postoperative complications are rare. Maddalozzo et al (42) had reported 29% incidence of complications in patients younger than 18 years old and other author reported as 12% in adult (17). The major complications include recurrence, abscess or haematoma requiring surgical drainage, inadvertent entry into the airway during intraoperatively, tracheostomy, recurrent laryngeal nerve paralysis, hypothyroidism and even death (43). Furthermore, the reported minor complications include seroma, local wound infection, stich abscess and wound dehiscence (42). Similarly, in our 2 cases (17%) had a minor complication of mucoid discharge from previous drain site in an adult patient and a mild wound hematoma. The need of postoperative drain is controversial, which we advocate no drain required in Sistrunk procedure. The previous literature reported that the recurrence rate after the Sistrunk procedure is 3-6% (12). Misdiagnosis and mismanagement of TDC resulting in incomplete surgical removal of

TDCs and lead to risk of recurrence (18, 44). In our series, neither residual nor recurrence was encountered during the follow up.

As a conclusion, TDCs may manifest at any age and more prevalence in the pediatric age group and they are equal in males and females. Most of TDCs presented in classical way and diagnosis is clinical. US of neck was the common routine preoperative test and found to be adequate as well as for evaluation of the thyroid gland, whereas CT may have a role in adult patient to rule out malignancy. Additional imaging or investigation studies may be helpful in selected cases. The Sistrunk operation is considered the treatment of choice with minimal morbidity and recurrence.

References

1. Allard R.H.B. The thyroglossal cyst. *Head Neck Surg.* 1982; 5: 143–146.
2. Ellis PD, van Nostrand AW. The applied anatomy of thyroglossal tract remnants. *Laryngoscope* 1977; 87: 765-770.
3. Mondin V, Ferlito A, Muzzi E, et al. Thyroglossal duct cyst: personal experience and literature review. *Auris Nasus Larynx* 2008; 35: 11-25.
4. Pollock WF, Stevenson EO. Cysts and sinuses of the thyroglossal duct. *Am J Surg* 1966; 112: 225-232.
5. Ducic Y, Chou S, Drkulec J, Ouellette H, Lamothe A. Recurrent thyroglossal duct cysts: a clinical and pathologic analysis. *Int J Pediatr Otorhinolaryngol* 1998; 44: 47-50.
6. Ghaneim A, Atkins P. The management of thyroglossal duct cysts. *Int J Clin Pract* 1997; 51: 512–513.
7. Kennedy TL, Whitaker M, Wadiah G. Thyroglossal duct carcinoma: a rational approach to management. *Laryngoscope* 1998; 108: 1154-1158.
8. Waddell A, Saleh H, Robertson N, Khalil HS, Bridger MW. Thyroglossal duct remnants. *J Laryngol Otol* 2000; 114: 128-129.
9. Dedititis RA, Camargo DL, Peixoto GL, Weissman L, Guimarães AV. Thyroglossal duct: a review of 55 cases. *J Am Coll Surg* 2002; 194: 274-277.
10. Hsieh YY, Hsueh S, Hsueh C, et al. Pathological analysis of congenital cervical cysts in children: 20 years of experience at Chang Gung Memorial Hospital. *Chang Gung Med J* 2003; 26: 107-113.
11. Sprinzl GM, Koebke J, Wimmers-Klick J, Eckel HE, Thumfart WF. Morphology of the human thyroglossal tract: a histologic and macroscopic study in infants and children. *Ann Otol Rhinol Laryngol* 2000; 109: 1135-1139.
12. Brousseau VJ, Solares CA, Xu M, Krakovitz P, Koltai PJ. Thyroglossal duct cysts: presentation and management in children versus adults. *Int J Pediatr Otorhinolaryngol* 2003; 67: 1285-1290.
13. Clute HM, Cattell RB. THYROGLOSSAL CYSTS AND SINUSES. *Ann Surg* 1930; 92: 57-66.
14. McCLINTOCK JC, MAHAFFEY DE. Thyroglossal tract lesions. *J Clin Endocrinol Metab* 1950; 10: 1108-1117.
15. DALGAARD JB, WETTELAND P. Aberrant thyroid tissue. II. Thyroglossal anomalies; a follow-up study of 58 cases. *Acta Chir Scand* 1956; 111: 444-455.

16. BROWN PM, JUDD ES. Thyroglossal duct cysts and sinuses: results of radical (Sistrunk) operation. *Am J Surg* 1961; 102: 494-501.
17. Josephson GD, Spencer WR, Josephson JS. Thyroglossal duct cyst: the New York Eye and Ear Infirmary experience and a literature review. *Ear Nose Throat J* 1998; 77: 642-651.
18. Ostlie DJ, Burjonrappa SC, Snyder CL, et al. Thyroglossal duct infections and surgical outcomes. *J Pediatr Surg* 2004; 39: 396-399.
19. Mondin V, Ferlito A, Muzzi E, et al. Thyroglossal duct cyst: personal experience and literature review. *Auris Nasus Larynx* 2008; 35: 11-25.
20. Kanawaku Y, Funayama M, Sakai J, Nata M, Kanetake J. Sudden infant death: lingual thyroglossal duct cyst versus environmental factors. *Forensic Sci Int* 2006; 156: 158-160.
21. Hossam Thabet, Alaa Gaafar, Yasser Nour. Thyroglossal duct cyst Variable presentations. *Egyptian Journal of Ear, Nose, Throat and Allied Sciences*. 2011; 12: 13-20.
22. Davenport M. ABC of general surgery in children. Lumps and swellings of the head and neck. *BMJ* 1996; 312: 368-371.
23. Ahuja AT, King AD, Metreweli C. Sonographic evaluation of thyroglossal duct cysts in children. *Clin Radiol* 2000; 55: 770-774.
24. Sherman NH, Rosenberg HK, Heyman S, Templeton J. Ultrasound evaluation of neck masses in children. *J Ultrasound Med* 1985; 4: 127-134.
25. Ahuja AT, Wong KT, King AD, Yuen EH. Imaging for thyroglossal duct cyst: the bare essentials. *Clin Radiol* 2005; 60: 141-148.
26. Radkowski D, Arnold J, Healy GB, et al. Thyroglossal duct remnants. Preoperative evaluation and management. *Arch Otolaryngol Head Neck Surg* 1991; 117: 1378-1381.
27. Noyek AM, Friedberg J. Thyroglossal duct and ectopic thyroid disorders. *Otolaryngol Clin North Am* 1981; 14: 187-201.
28. Lim-Dunham JE, Feinstein KA, Yousefzadeh DK, Ben-Ami T. Sonographic demonstration of a normal thyroid gland excludes ectopic thyroid in patients with thyroglossal duct cyst. *AJR Am J Roentgenol* 1995; 164: 1489-1491.
29. Shahin A, Burroughs FH, Kirby JP, Ali SZ. Thyroglossal duct cyst: a cytopathologic study of 26 cases. *Diagn Cytopathol* 2005; 33: 365-369.
30. Wagner G, Medina JE. Excision of thyroglossal duct cyst: the Sistrunk procedure. *Oper Tech Otolaryngol* 2004; 15: 220-223.
31. Schlange H. Ueber die Fistula Colli Congenita. *Arch Klin Chir* 1893; 46: 390-392.
32. Sistrunk WE. THE SURGICAL TREATMENT OF CYSTS OF THE THYROGLOSSAL TRACT. *Ann Surg* 1920; 71: 121-124.
33. Wenglowski R. Ueber die Halsfisteln and Zysten. *Arch. Klin. Chir* 1912; 98: 151-208.
34. Horisawa M, Niinomi N, Nishimoto K, et al. Clinical results of the shallow core-out procedure in thyroglossal duct cyst operation. *J Pediatr Surg* 1999; 34: 1589-1592.
35. Luna MA, Pineda-Daboin K. Cysts and unknown primary and secondary tumours of the neck, and neck dissection. In: Cardesa A, Slootweg PJ, editors. *Pathology of the Head and Neck*. Berlin: Springer; 2006; 263-282.
36. Burnell I, Tomkinson A, Hourihan M, Robinson M, Douglas-Jones A. Mucin-secreting papillary adenocarcinoma of the hyoid bone: a unique case. *J Laryngol Otol* 2005; 119: 498-502.
37. Chandrasoma P, Janssen M. A thyroglossal cyst lined by gastric epithelium. *JAMA* 1982; 247: 1406.
38. Patel SG, Escrig M, Shaha AR, Singh B, Shah JP. Management of well-differentiated thyroid carcinoma presenting within a thyroglossal duct cyst. *J Surg Oncol* 2002; 79: 134-139.
39. Doshi SV, Cruz RM, Hilsinger RL Jr. Thyroglossal duct carcinoma: a large case series. *Ann Otol Rhinol Laryngol* 2001; 110: 734-738.
40. Hanna E. Squamous cell carcinoma in a thyroglossal duct cyst (TGDC): clinical presentation, diagnosis, and management. *Am J Otolaryngol* 1996; 17: 353-357.
41. Lehnerdt KH, Mehlhorn J, Nürnbergger H, Deitmer T. [Simultaneous papillary carcinoma in a thyroglossal duct remnant and the thyroid gland]. [Article in German] *Laryngorhinotologie* 2006; 85: 909-912.
42. Maddalozzo J, Venkatesan TK, Gupta P. Complications associated with the Sistrunk procedure. *Laryngoscope* 2001; 111: 119-123.
43. Patel NN, Hartley BE, Howard DJ. Management of thyroglossal tract disease after failed Sistrunk's procedure. *J Laryngol Otol* 2003; 117: 710-712.
44. Kaselas Ch, Tsikopoulos G, Chortis Ch, Kaselas B. Thyroglossal duct cyst's inflammation. When do we operate? *Pediatr Surg Int* 2005; 21: 991-993.