

Dieulafoy's lesion treated with argon plasma coagulation and injection sclerotherapy: A rare case report

Dieulofaloy lezyonunun kombine tedavisi: Olgu sunumu

Şehmus ÖLMEZ¹, Bünyamin SARITAŞ², Mehmet ASLAN³, Ahmet Cumhuri DÜLGER¹, Ibrahim AYDIN³

Departments of ¹Gastroenterology, and ³Internal Medicine, Yüzüncü Yıl University Medical Faculty, Van

²Department of Gastroenterology, Muş Public Hospital, Muş

Dieulafoy's lesion is an uncommon, but important, cause of upper gastrointestinal bleeding. Dieulafoy's lesion is usually seen in the stomach, but sometimes can be seen in the small or large bowel. Typically, it is located within 6 cm of the esophagogastric junction, generally along the lesser curvature of the stomach. Various methods with endoscopy are used to control the hemostasis due to these lesions, but the most suitable endoscopic treatment method for treating bleeding Dieulafoy's lesion is not yet well established. Argon plasma coagulation has been used successfully in upper gastrointestinal bleeding; however, the experience using argon plasma coagulation to treat Dieulafoy's lesion is quite limited. Herein, we report a case with a bleeding gastric Dieulafoy's lesion that was treated using a combined endoscopic approach with injection therapy and argon plasma coagulation.

Key words: Dieulafoy lesion, gastrointestinal bleeding, argon plasma coagulation, treatment

INTRODUCTION

Dieulafoy's lesion (DL) is a caliber-persistent submucosal artery associated with a minute mucosal defect (1). DL is a rare cause of gastrointestinal bleeding, which can be life-threatening or recurrent if left untreated, and it has an incidence of 0.3–6.7% (2). Endoscopic treatment has replaced surgery as

Dieulafoy lezyonu nadir görülen ancak önemli bir üst gastrointestinal kanama nedenidir. Sıklıkla midede görülmekle birlikte ince ve kalın bağırsaklarda da görülebilir. Tipik olarak gastroözofageal bileşkedeki sonraki 6 cm içinde, küçük kurvatur yönünde yerleşir. Bu lezyonlara bağlı kanamada, hemostazi sağlamak için değişik endoskopik yöntemler kullanılır ve kanayan Dieulafoy lezyonu tedavisi için en uygun endoskopik tedavi yöntemi henüz iyi tanımlanmamıştır. Argon plazma koagülasyonu üst gastrointestinal kanamada başarılı bir şekilde kullanılmasına rağmen Dieulafoy lezyonuna bağlı kanamalarda kullanımı sınırlıdır. Burada enjeksiyon tedavisi ve argon plazma koagülasyonu ile kombine olarak tedavi edilen, kanayan gastrik Dieulafoy lezyonu olan olguyu sunacağız.

Key words: Dieulafoy lezyonu, gastrointestinal kanama, argon plazma koagülasyonu, tedavi

the standard diagnostic and therapeutic method for bleeding DLs (3). Endoscopic interventions, such as band ligation, thermocoagulation with heater probe, bipolar electrocoagulation, photocoagulation, injection therapy, and endoscopic hemoclip application, are among the first choices in the ther-

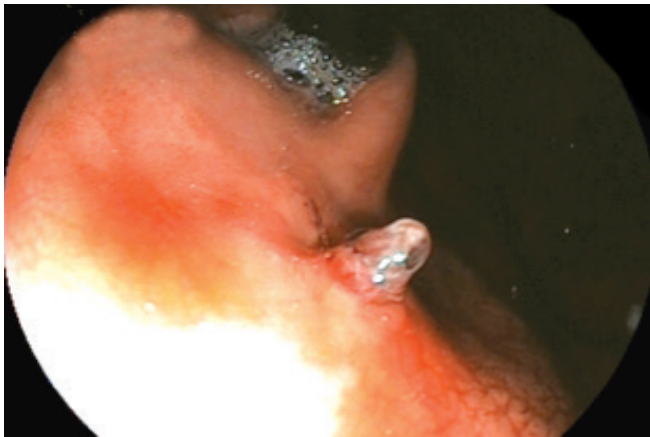

Figure 1. Dieulafoy's lesion on the lesser curvature near the cardia.

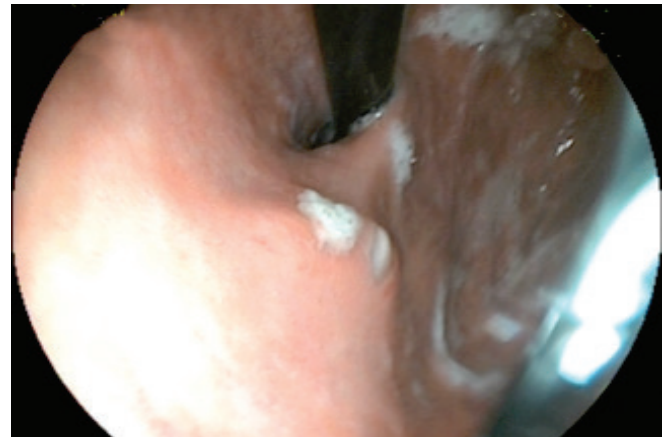


Figure 2. Millimetric ulcers with white exudate three days after treatment.

Ölmez Ş, Sarıtaş B, Aslan M, et al. Dieulafoy's lesion treated with argon plasma coagulation and injection sclerotherapy: A rare case report. *Endoscopy Gastrointestinal* 2014; 22: 18-20

Corresponding Author: Şehmus ÖLMEZ
 Yüzüncü Yıl University, Medical Faculty, Department of Gastroenterology
 Van, Türkiye • Phone: +90 432 216 7325 Fax: +90 432 2167325
 E-mail: drsehmosulmez@gmail.com
 Geliş Tarihi: 05.11.2013 Kabul Tarihi: 15.03.2014

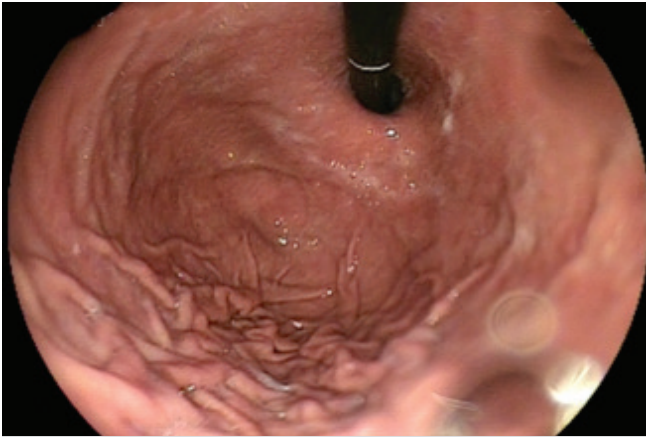


Figure 3. No lesion is seen six weeks after the treatment.

apy (1,2). The control of bleeding due to DLs can usually be provided with endoscopic therapy, but the best modality of endoscopic intervention is not yet certain (1,2). Epinephrine monotherapy has a higher rate of rebleeding (4). Argon plasma coagulation (APC) is compact, mobile and easy-to-use, and has a relatively low cost when compared with the other treatment modalities (5). APC has been used successfully in the upper gastrointestinal tract. However, experience using APC to treat DLs is quite limited (3,6). We report a case of a 58-year-old female who admitted to the emergency department with hematemesis and melena. During endoscopy, a non-bleeding vessel was seen on the lesser curvature of the stomach near the gastroesophageal junction, and a diagnosis of DL was made. The lesion was managed with APC and injection sclerotherapy.

CASE REPORT

A 58-year-old female admitted to the emergency department with hematemesis and melena. She had no complaints of dyspepsia, abdominal pain or ulcer. The patient had a history of diabetes mellitus and hypertension. Her body temperature was 37,2°C, blood pressure 160/90 mmHg, and pulse rate 88 beats/min and regular. The physical examination was normal. Routine biochemical test results were within the normal ranges. During endoscopy, a non-bleeding vessel was seen on the lesser curvature of the stomach near the gastroesophageal junction, and the diagnosis of gastric DL was made (Figure 1). We used epinephrine (4 cc 1:10000) together with APC as the first choice of endoscopic treatment. Three days after the combined treatment, ulcer with white exudate was seen via endoscopy (Figure 2). Six weeks after beginning the treatment, no lesion was seen via endoscopy (Figure 3).

DISCUSSION

Dieulafoy's lesion (DL) is an important cause of upper gastrointestinal bleeding, and this lesion may be seen anywhere

throughout the gastrointestinal tract, but it usually develops in the proximal stomach, predominantly on the lesser curvature (1,9). DLs are usually found within 6 cm of the gastroesophageal junction; the arterial flow in this area emerges directly from the left gastric artery (4). DLs are usually associated with comorbidity such as cardiovascular disease, arterial hypertension or renal failure (4,7).

The most frequent clinical manifestation of DLs is a massive upper digestive hemorrhage. It is probably a recurrent bleeding without pain, and is associated with a severe life-threatening hemodynamic condition, affecting previously healthy individuals without gastrointestinal diseases or peptic symptoms (3,4).

Advances in endoscopy have increased the detection rate of DLs and significantly decreased the mortality (3,7). The endoscopic criteria proposed to define DLs are: active arterial spurting or micropulsatile streaming from a minute (<3 mm) mucosal defect or through normal surrounding mucosa; visualization of a protruding vessel with or without active bleeding within a minute mucosal defect or through surrounding normal mucosa; and fresh, densely adherent clot with a narrow point of attachment to a minute mucosal defect or to normal appearing mucosa (7). The first step to diagnosis DLs is endoscopy, but due to the small size of the lesion, its relatively inaccessible localization and the presence of blood and blood clots, the diagnosis is difficult (3,7). Success rates for the first endoscopy range from 77-92,4% (1,8). Therefore, repeated endoscopy may be necessary (3,7). Endosonography and angiography can also be used for the diagnosis of DLs (4,7).

Several treatment methods like endoscopy, surgery and angiography with embolization have been described for DLs (7). Embolization treatment may lead to ischemia. Surgical treatment may only be necessary in 5% of DLs. Today, endoscopic treatment is the first treatment choice. The safety and efficacy of endoscopic treatments have been widely accepted (1,2,7). Endoscopic interventions in DLs have a success rate of 75–100% in controlling the hemostasis using variable treatment methods, such as injection therapy, heater probe, endoscopic hemoclip placement (EHP), and endoscopic band ligation (EBL) (1,2,9), and the mortality rates have decreased from 80% to 8.6% (7). Nevertheless, there is still no consensus with regard to the optimal method of treatment (1,2,7).

Epinephrine injection is the most commonly used method due to its availability, low cost and safety. Hemostasis in DLs can be controlled with epinephrine injection alone, but the risk of rebleeding is high, and it requires surgery rather than other endoscopic methods (4,9). Mechanical hemostasis causes less damage to the surrounding tissue than injection or thermal therapy, and several reports have shown the superiority of the mechanical endoscopic methods (EHP or EBL) over injection or thermal treatment. Both EHP and EBL

have shown good results for initial hemostasis and long-term outcome. Both are simple methods and easy to perform. The advantage of EHP is its lack of side effects, and therefore, it is a preferred therapy option for DLs (1,9); however, it is very hard to perform when the lesion is tangential or visible only in the retroflexed position of the endoscopy (2,6). On the other hand, APC is a noncontact electrocoagulation method that is used especially for chronic radiation proctitis, watermelon stomach and ablation of Barrett's esophagus. Further, APC can be used in bleeding due to peptic ulcers, angiodysplasia and DLs (6). This method may be advantageous over the contact thermal methods since it permits targeting of the

bleeding sites, even if tangential, and reduces the risk of perforation by limiting the depth of the tissue damage (6). APC can be performed easily to lesions through frontal and lateral probes, independently, depending on the location (2,6,10). A combined endoscopic approach with injection of epinephrine and APC can be used to treat DLs (6,11).

In conclusion, if DLs are not recognized and treated properly, they may cause upper gastrointestinal bleeding, which is life-threatening. Especially in technically difficult cases and in the centers equipped with an APC unit, it may be suitable to use APC together with injection sclerotherapy for the treatment of DLs.

REFERENCES

1. Sone Y, Kumada T, Toyoda H, et al. Endoscopic management and follow up of Dieulafoy lesion in the upper gastrointestinal tract. *Endoscopy* 2005; 37: 449-53.
2. Ahn DW, Lee SH, Park YS, et al. Hemostatic efficacy and clinical outcome of endoscopic treatment of Dieulafoy's lesions: comparison of endoscopic hemoclip placement and endoscopic band ligation. *Gastrointest Endosc* 2012; 75: 32-8.
3. Linhares MM, Filho BH, Schraibman V, et al. Dieulafoy lesion: endoscopic and surgical management. *Surg Laparosc Endosc Percutan Tech* 2006; 16: 1-3.
4. Jamanca-Poma Y, Velasco-Guardado A, Piñero-Pérez C, et al. Prognostic factors for recurrence of gastrointestinal bleeding due to Dieulafoy's lesion. *World J Gastroenterol* 2012; 40: 5734-8.
5. Manner H, May A, Faerber M, Rabenstein T, Ell C. Safety and efficacy of a new high power argon plasma coagulation system (hp-APC) in lesions of the upper gastrointestinal tract. *Dig Liver Dis* 2006; 38: 471-8.
6. Iacopini F, Petruzzello L, Marchese M, et al. Hemostasis of Dieulafoy's lesions by argon plasma coagulation. *Gastrointest Endosc* 2007; 66: 20-6.
7. Baxter M, Aly EH. Dieulafoy's lesion: current trends in diagnosis and management. *Ann R Coll Surg Engl* 2010; 92: 548-54.
8. Yarze JC. Routine endoscopic "marking" of Dieulafoy like lesions. *Am J Gastroenterol* 2001; 96: 264-5.
9. Lara LF, Sreenarasimhaiah J, Tang SJ, Afonso BB, Rockey DC. Dieulafoy lesions of the GI tract: localization and therapeutic outcomes. *Dig Dis Sci* 2010; 55: 3436-41.
10. Yarze JC. Argon plasma coagulation of Dieulafoy's lesions. *Gastrointest Endosc* 2006; 63: 733.
11. Souza JLS. Treatment of Dieulafoy's lesion of the right colon with epinephrine injection and argon plasma coagulation. *Endoscopy* 2009; 41: E192.