

Outcomes of intravenous thrombolytic and adjuvant surgery in acute limb ischemia: Review of 23 patients

Akut bacak iskemisinde intravenöz trombolitik ve adjuvan cerrahi tedavi sonuçları: 23 olgunun değerlendirilmesi

Deniz Demir ¹, Nail Kahraman ¹

¹Bursa Yüksek İhtisas Training and Research Hospital, Department of Cardiovascular Surgery, Bursa, Turkey

ORCID ID of the author(s)
DD: 0000-0003-2169-7647
NK: 0000-0001-9343-0947

Abstract

Aim: Today, combined thrombolytic and surgical adjuvant embolectomy is known to have positive results in acute limb ischemia (ALI) treatment. In thrombolytic therapy, the intra-arterial method is generally used. In our study, we performed an intravenous thrombolytic and / or adjuvant surgical embolectomy in patients with failed bypass or diffuse aorta vascular disease who were unable to perform catheter directed thrombolytic therapy (CDT) due to technical difficulties. We evaluated the mortality and morbidity results of the patients.

Methods: Retrospective cohort study was planned. This study consists of patients treated for ALI between January 2014 and September 2018. First, the intravenous thrombolytic treatment was performed. The patients who failed this treatment were additionally treated with surgical embolectomy. The patients were in Rutherford Class IIa and IIb.

Results: A total of 23 ALI patients were included in the study. Thrombolytic treatment was performed on all of the patients. Twelve (52%) patients who failed thrombolytic treatment were also treated with surgical adjuvant embolectomy. In the first month, two patients (8.7%) required major amputation. In follow-up period of one year, a total three patients (13%) required major amputation and one patient (4.3%) had intracranial hemorrhage.

Conclusions: ALI, despite all the developments in its treatment, is still a life threatening disease. This study suggests that our rate of amputation, hemorrhage and extremity rescue are similar or a little lower than the large series of intra-arterial thrombolytic treatments in the literature. Today, the thrombolytic treatment methods have one thing in common which is the use of intra-arterial route. Yet we reckon that as in our study; the patients who cannot be treated with intra-arterial catheterization the intravenous thrombolytic therapy and/or surgical adjuvant embolectomy can be helpful in rescuing those patient's life and extremity.

Keywords: Acute limb ischemia, Intravenous thrombolytic, Adjuvant surgery

Öz

Amaç: Günümüzde ALI tedavisinde trombolitik ve kombine adjuvan cerrahi embolektominin iyi sonuçlar verdiği bilinmektedir. Trombolitik tedavi de genellikle intra-arteryel yolla yapılmaktadır. Başarısız bypass ya da diffüz aortailiyak damar hastalarında teknik zorluktan dolayı intravenöz trombolitik ve/veya adjuvan cerrahi embolektomi yaptığımız hastaların mortalite ve morbidite sonuçlarını değerlendirdik.

Yöntemler: Bu çalışma Ocak 2014 ile Eylül 2018 yılları arasında ALI sebebiyle tedavi edilen hastalardan oluşmaktadır. Çalışma tek merkezli ve retrospektif olarak yapılmıştır. Tedavide öncelikle venöz trombolitik tedavi uygulandı. Bu tedavinin başarısız olduğu hastalarda ise ek olarak cerrahi embolektomi yapıldı. Hastalar Rutherford class IIa and IIb sınıfından oluşmaktadır.

Bulgular: Toplam 23 ALI hastası çalışmaya dahil edildi. Bütün hastalara trombolitik tedavi uygulandı. Trombolitik tedavinin yetersiz kaldığı 12 (52%) hastaya adjuvan cerrahi embolektomi yapıldı. İlk bir ayda 2(8,7%) hastada major amputasyon tespit edildi. Bir yıllık takip süresinde ise toplam 3(13%) hastada major amputasyon tespit edildi. 1 hastada (4,3%) oranında intrakranial hemoraji görüldü.

Sonuç: ALI tedavisinde günümüzdeki bütün gelişmelere rağmen hastaların ekstremit ve hayatlarını tehdit etmektedir. Bizim hasta grubumuzdaki amputasyon, kanama ve ekstremit kurtarma oranlarımız, literatürdeki intra-arteryel trombolitik tedavinin kullanıldığı geniş serilere benzer ya da biraz daha kötü olduğunu tespit ettik. Günümüzde trombolitik tedavi yöntemlerinde ortak nokta intra-arteryel yolun kullanımı şeklindedir. Ancak bizim çalışmamızda olduğu intra-arteryel kateterizasyonun kullanılmadığı hastalarda venöz trombolitik ve/veya kombine adjuvan cerrahi girişimlerin bu hastaların hayatını ve ekstremitesini kurtarmada faydalı olabileceğini düşünmekteyiz.

Anahtar kelimeler: Akut bacak iskemisi, Intravenöz trombolitik, Adjuvan cerrahi

Corresponding author / Sorumlu yazar:
Deniz Demir

Address / Adres: Bursa Yüksek İhtisas Eğitim ve Araştırma Hastanesi, Kalp Damar Cerrahisi Kliniği, Bursa, Türkiye
E-mail: denizzdr@msn.com

Ethics Committee Approval: The study protocol was approved by the Bursa Yüksek İhtisas Hospital Ethics Committee.

Etik Kurul Onayı: Çalışma protokolü, Bursa Yüksek İhtisas Hastanesi Etik Kurulu tarafından onaylandı.

Conflict of Interest: No conflict of interest was declared by the authors.

Çıkar Çatışması: Yazarlar çıkar çatışması bildirmemişlerdir.

Financial Disclosure: The authors declared that this study has received no financial support.

Finansal Destek: Yazarlar bu çalışma için finansal destek almadıklarını beyan etmişlerdir.

Received / Geliş Tarihi: 11.02.2019

Accepted / Kabul Tarihi: 16.02.2019

Published / Yayın Tarihi: 18.02.2019

Copyright © 2019 The Author(s)
Published by JOSAM

This is an open access article distributed under the terms of the Creative Commons Attribution-NonCommercial-NoDerivatives License 4.0 (CC BY-NC-ND 4.0) where it is permissible to download, share, remix, transform, and build upon the work provided it is properly cited. The work cannot be used commercially without permission from the journal.



Introduction

The arterial embolization and the thrombus of native and graft vessels are the causes of acute limb ischemia. Acute limb ischemia (ALI) is a serious, life-threatening condition. The treatment is usually thrombolytic therapy with an intra-arterial catheterization. Intra-arterial thrombolytic therapy can be performed under local anesthesia and by this means, patients with comorbidities are treated more safely [1].

ALI patients are treated with surgical adjuvant embolectomy when catheter directed thrombolytic therapy (CDT) is not effective. There are also other new treatment choices like revascularization and endovascular treatment. Additionally, another treatment called percutaneous aspiration thrombectomy can also be performed [2]. Yet, in case of complex conditions like failed bypass graft or diffuse aorto-iliac arterial disease; CDT therapy would be difficult to perform due to arterial catheterization complexity. The purpose of this study is to present the results of ALI patients treated with intravenous thrombolytic therapy or surgical adjuvant embolectomy.

Materials and methods

This study consists of patients treated for ALI in our hospital between January 2014 and September 2018. This is a single center, retrospective cohort study. A written informed consent was obtained from each patient. The study protocol was approved by the Bursa Yüksek İhtisas Hospital Ethics Committee. The study was conducted in accordance with the principles of the Declaration of Helsinki. The patient records were taken from the hospital's medical record system. All patients received physical examination, EKG, Echocardiography and routine blood tests. In the physical examination, the patient ALI was accepted in the presence of extremity coldness, pallor, cyanosis, pain, inability to palpate peripheral pulses and/or hand Doppler flow. Vascular scanning was performed with ultrasonography, computed tomography, angiography or conventional angiography (Figure 1). First, the patients were treated with intravenous thrombolytic therapy with Actilyse® (Boehringer Ingelheim, Ingelheim, Germany) which is a recombinant tissue plasminogen activator (rtPA). Patients with unhealed ischemia received surgical adjuvant embolectomy.

The inclusion criteria: Patients with diffuse arterial disease having intravenous thrombolytic therapy, ALI patients with failed bypass graft, patients with symptoms of less than 14 days duration, patients with arterial run-off detected by angiography and/or ultrasonography, ALI of class IIa and IIb according to the Rutherford classification [3].

Exclusion criteria: Patients with active bleeding, recent history of a major surgical operation, recent cerebral trauma, active cancer or recent history (last two months) of neurovascular disease were not included in the case study. Due to the risk of bleeding, patients with anemia (Hemoglobin <8gr/dl), thrombocytopenia (Platelet <80000), with an INR above 1.5 and with serious renal insufficiency are not able to have thrombolytic therapy, for this reason, they are excluded from the study.

The thrombolytic treatment procedure started with Actilyse® bolus dose of 4-5 mg, followed by 0.5-1 mg/h/kg.

Total dose was 50 mg. Patients were given 5000 units unfractionated heparin before the thrombolytic treatment. During the procedure, the patients' vital signs were constantly monitored in intensive care unit. Patients with a blood pressure 120/80 mmHg were constantly given nitroglycerine infusion and blood pressure regulation was provided before thrombolytic treatment.

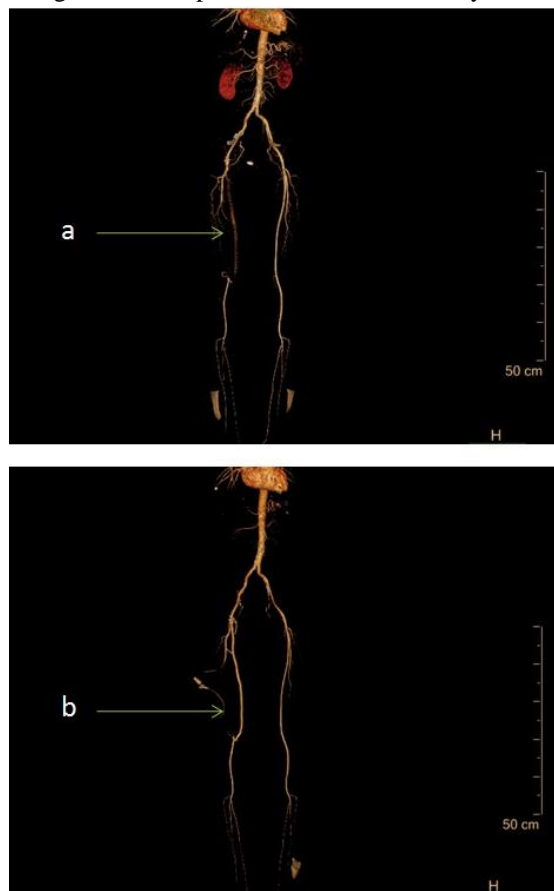


Figure 1: a: before treatment CT angiography of an ALI patient, the arrow shows the graft thrombosis, b: after treatment CT angiography of the same patient, arrow shows the open graft (Combined thrombolytic and surgical adjuvant embolectomy procedures are performed in this patient.)

After the thrombolytic treatment, symptoms like warming of feet, healing of pain, palpable distal pulse or palpable distal pulse measured by a hand-held Doppler were counted as the indications of a successful treatment. In case of a failure in thrombolytic treatment, surgical adjuvant embolectomy was performed after 4-6 hours' time. Embolectomy procedure was performed under local anesthesia in sterilized operating room. Patients were given 5000 UI standard heparin before the operation. After that, thrombectomy was performed with appropriate Fogarty embolectomy catheter inserted with transverse section of the femoral artery. Arteriotomy then closed with 6/0 or 7/0 polypropylene suture. Patients then treated with appropriate antibiotic therapy. After the procedure, the patients' follow-up in 1-month and 1-year periods were examined with regard to bleeding complications, amputation, (Major/minor amputation was defined as amputation above/lower foot-level) and limb rescue. Patients developing extremity gangrene in spite of medical and surgical treatment were referred to orthopedics for amputation. Other patients were discharged after their further treatment in our clinic.

Statistical analysis

SPSS 15.0 (SPSS, Chicago, IL, USA) was used in the evaluation of the results. All the data were presented as mean \pm standard deviation or proportions as appropriate.

Results

Twenty three patients with ALI which were treated with thrombolytic and surgical adjuvant embolectomy were included in this study. 14 (60%) patients were male and the average age of the patients was 62.56±16.60. Number of patients with hypertension was 20 (86%). Number of patients with a history of diabetes mellitus was 9 (39%). Number of smokers was 19 (82%). Number of patients with a history of failed bypass was 13(56%). Patient’s average duration of ALI symptoms was 7.82±3.45 days. Six (26%) patients were in Rutherford Class IIa and 17 (73%) of them were in Rutherford class IIb according to their symptom levels (Table 1).

In the first place, all of the patients were treated with intravenous thrombolytic therapy. 12 patients (52%) with unhealed symptoms of ALI despite of thrombolytic therapy were also treated with surgical adjuvant embolectomy. Two patients (8.7%) were reported need major amputations in the first month. In the follow-up period of one year, a total number of 3 patients (13%) were reported need major amputation. Patients with amputations were previously treated with both thrombolytic and surgical methods. 30-day survival was observed in 22 patients (95.7%). One patient (4.3%) developed intracranial hemorrhage on the first day after the treatment (Table 2). This patient died during the follow-up in intensive care unit due to multi-organ failure. One patient (4.3%), previously treated with thrombolytic and surgical methods, was reported with foot drop in postoperative period. Extremity-rescuing number in the first month was reported as 21 patients (91%). Other patients were not reported with any minor amputations or bleeding complications.

Table 1: Demographic data and preoperative risk factors

	Value
Age mean ± SD	62.56±16.60
Gender male n (%)	14 (61)
Hypertension n (%)	20 (86)
Diabetes Mellitus n (%)	9 (39)
Smoke n (%)	19 (82)
Coronary artery disease n (%)	14 (60)
Peripheral surgical story n (%)	13 (56)
Atrial fibrillation n (%)	4 (17)
Symptom duration (Day) mean ± SD	7.82±3.45
Rutherford classification 2a n (%)	6 (26)
Rutherford classification 2b n (%)	17(73)

SD: Standard deviation

Table 2: Postoperative data and complications

	n (%)
Extremity rescue	21 (91)
Minor amputation	0 (0)
Major amputation 30 day	2 (8.7)
Major amputation 1 year (total)	3 (13)
Intracranial bleeding	1 (4.3)
Additional surgical procedure (embolectomy)	12 (52)
30 Day survival	22 (95.7)
1 year survival	22 (95.7)
Deceased	1 (4.3)

Discussion

ALI is described as a sudden decrease in extremity perfusion and it threatens the vitality of the extremity. The incidence of ALI is 9-16 cases per 100.000 persons per year for the lower extremity. Etiology includes embolism, thrombosis with coexisting peripheral arterial disease, graft/stent thrombosis or peripheral aneurysm with embolism or thrombosis [4]. With the onset of ALI symptoms, both the patient’s extremity and life are under threat. 30-day amputation rate is examined in many early and recent studies of ALI. The amputation rate in the 90s

was reported as 6-16 percent. Yet again in the same era, the 30-day mortality rate was reported as 16-22 percent [5,6]. In a wider study made on ALI patients in 2000s showed that amputation rates were 13-14 percent and mortality rates were 9-12 percent [7]. Today’s studies, 30-day mortality rate are 5.2 percent. The overall rate of major amputation is 15.0% [8].

These studies show that more effective surgical procedures or newer medical therapies lead to a partial decrease in mortality and amputation rates in ALI treatment. In spite of all the new developments, early 30-day mortality and amputation rates are still high. Thus, ALI still continues to be a health problem in today’s world threatening patient’s extremities and lives.

Thrombolysis and open surgical revascularization are current options for the treatment of ALI. Despite the several randomized controlled trials comparing the two options, no single treatment is recommended in the ALI treatment. CDT is preferred in medical treatment. Thrombectomy and perioperative endovascular aspiration and mechanical thrombectomy are used as surgical treatments. Fast revascularization in ALI is achievable with combined thrombolytic therapy [9,10]. Today, commonly-accepted use of thrombolytic agents is in case of an extremity threatening ischemia. When directly applied into thrombus, thrombolytic agents are more effective. Systemic intravenous thrombolysis is less effective than intra-arterial thrombolysis but can have higher risk of bleeding complications [11].

In ALI treatment, CDT therapy when compared to open surgery has become a routine clinical therapy in the last thirty years following three published randomized controlled studies that showed similar findings. The main advantages of intra-arterial thrombolysis are the avoidance of anesthesia and its being a safer way of treatment in elderly patients and patients with comorbidities. Thrombolysis, with lower risk of endothelial dysfunction and re thrombosis, was observed locally dissolve the thrombus even in the divisions of main artery. Furthermore, the underlying stenosis becomes detectable through imaging methods after the dissolution of thrombus with thrombolytic therapy. By this means, following treatment decisions can be simplified and the potential long-term results can be improved [12]. Today, CDT therapy being more effective with fewer side effects compared to the intravenous therapy is the general consent. Yet outside of this consent, there are other researches showing ALI treatments with intravenous thrombolytic therapies and the results’ similarities with CDT therapy results. Saroukhani et al. [13] evaluated the results of intravenous thrombolytic therapy and CTD therapy. According to this research, the complication rates along with the clinical results are comparable. There was no significant difference between two study groups regarding the incidence of limb amputations. At the end of the study, it was also indicated that both therapy methods are safe and effective. The incidents of bleeding complications indicated in Grip et al’s 689 disease studies were high with a rate of 29.8%. Yet most of them were minor and controllable without a cut-off in thrombolysis. Intracranial hemorrhage was reported with a rate of 0.4% in Grip et al.’s patient group [12].

Berridge et al [14] indicated hemorrhagic complications in a meta-analysis of five randomized controlled study that

included a comparison of intra-arterial thrombolysis and operations in ALI treatment including a total 1283 patients. In this study, rate of the stroke incidents was reported as 1.2% while the major bleeding rate was 8.8% [14]. Byrne et al [8] gave alteplase as an intra-arterial thrombolytic agent to his 147 ALI case study patients. This patient group was reported with Rutherford class IIa with 70.1% and class IIb with 20.1%. Technical success was achieved in 83.8% of cases, with a 30-day mortality rate of 5.2%. Procedural complications including systemic bleeding were seen in 5.2%, access site hematoma 4.5%, acute renal failure 1.9%, and distal embolization 9.7%. The overall rate of major amputation was 15.0% [8].

In our patient group, a total of 23 patients are performed intravenous thrombolytic therapy due to ALI. All of the cases were either having a failed bypass graft or with diffuse vascular disease. The patients could not be treated with CDT due to the difficulty of arterial intervention. 17 patients (73%) were in Rutherford class IIb. 12 (52%) patient had to have surgical embolectomy in addition to thrombolytic therapy. Extremity rescue ratio of our patients was 91% with 21 patients. Extremity rescue rate in literature is indicated between 84-94 percent [5,6]. In our patient group, only 2 patients 8.7% were reported with major amputation in the first month. In one-year follow up period 3 patients 13% were reported with major amputation. Minor amputation was not reported. In literature, the major amputation rate was 6.4% in 30 days which increased 13% in 12 months' time [8]. According to the total evaluation of these results, it is seen that the extremity rescue and major amputation rates we have are similar or a little lower than the ones in literature [6,8].

Major hemorrhage was indicated between 5.2% and 13.9% in various series [8,15]. Within our patient group, one patient 4.3% developed major hemorrhage. The type of the major bleeding was intracranial hemorrhage and this patient died. One patient developed foot drop. Other patients did not develop any kind of bleeding or other complications. The two main precautions we took could be effective in our patient group not developing many hemorrhagic complications even if we had not had a control group. First one is the analysis of a probable thrombolytic contraindicated condition on patients we treated with thrombolytic therapy. Second one is the close follow-up of blood pressure of the patients during and after their treatment. In our patient group 30-day survival rate was 22 patients 95.7%. In literature, the 30-day survival in various patient groups is reported rates 93% to 97% [12].

When examined, we reckon there are similarities between our patient group and the patient groups in literature with regard to major bleeding and 30-day survival. Patients in the literature that we are comparing to our patient have also been treated with intra-arterial thrombolytic therapy. CDT is known to have positive effects on patients with ALI symptoms. Yet the patients with inapplicable CDT due to diffuse vascular disease or failed bypass graft as in patients in our group can be treated with intravenous thrombolytic therapy.

30-day survival and bleeding complications are similar to the ones in the literature and amputation rates are generally similar or lower than the literature. In conclusion, we support CDT therapy in ALI patients if possible. Yet ALI patients with

inapplicable or failed arterial catheterization may not be treated with CDT therapy, in this case intravenous thrombolytic therapy and necessary combined surgical interventions can become extremity rescuing and life-saving procedures.

References

1. Su Grip O, Kuoppala M, Acosta S, Wanhainen A, Åkeson J, Björck M. Outcome and complications after intra-arterial thrombolysis for lower limb ischaemia with or without continuous heparin infusion. *British Journal of Surgery*. 2014;101:1105-12.
2. Hastaoğlu İO, Parlar H, Toköz H, Fırat A, Bilgen F. Kateter destekli trombekтоми. *Türk Gogus Kalp Dama*. 2014;22:656-60.
3. Rutherford RB. Clinical staging of acute limb ischemia as the basis for choice of revascularization method: when and how to intervene. *Semin Vasc Surg*. 2009;22:5-9.
4. Knowles M, Timaran CH. Epidemiology of acute critical limb ischemia. *Crit. Limb Ischemia*, Cham: Springer International Publishing. 2017;1-7.
5. Davies B, Braithwaite BD, Birch PA, Poskitt KR, Heather BP, Earnshaw JJ. Acute leg ischaemia in Gloucestershire. *British journal of surgery*. 1997;84:504-8.
6. Campbell WB, Ridler BMF, Szymanska TH. Current management of acute leg ischaemia: results of an audit by the Vascular Surgical Society of Great Britain and Ireland. *British journal of surgery*. 1998;85:1498-503.
7. Eliason J, Wainess R, Proctor M, Dimick J, Cowan JG. et al. A national and single institutional experience in the contemporary treatment of acute lower extremity ischemia. *Ann Surg*. 2003;238:382-9.
8. Byrne RM, Taha AG, Avgerinos E, Marone LK, Makaroun MS, Chaer RA. Contemporary outcomes of endovascular interventions for acute limb ischemia. *J Vasc Surg*. 2014;59:988-95.
9. Taha AG, Byrne RM, Avgerinos ED, Marone LK, Makaroun MS, Chaer RA. Comparative effectiveness of endovascular versus surgical revascularization for acute lower extremity ischemia. *J Vasc Surg*. 2015;61:147-54.
10. Butt T, Gottsäter A, Apelqvist J, Engström G, Acosta S. Outcome of intra-arterial thrombolysis in patients with diabetes and acute lower limb ischemia: a propensity score adjusted analysis. *Journal of thrombosis and thrombolysis*. 2017;4:475-480.
11. Kessel DO, Berridge DC, Robertson I. Infusion techniques for peripheral arterial thrombolysis. *Cochrane Database Syst Rev*. 2004;(1):CD000985.
12. Grip O, Wanhainen A, Acosta S, Björck M. Long-term Outcome after Thrombolysis for Acute Lower Limb Ischaemia. *European Journal of Vascular and Endovascular Surgery*. 2017;53:853.
13. Saroukhani A, Ravari H, Pezeshki RM. Effects of intravenous and catheter directed thrombolytic therapy with recombinant tissue plasminogen activator (Alteplase) in non-traumatic acute limb ischemia; a randomized double-blind clinical trial. *Bull Emerg Trauma*. 2015;3:86-92.
14. Berridge DC, Kessel DO, Robertson I. Surgery versus thrombolysis for initial management of acute limb ischaemia. *Cochrane Database Syst Rev*. 2013 Jun 6;(6):CD002784.
15. Acosta S, Kuoppala M. Update on intra-arterial thrombolysis in patients with lower limb ischemia. *J Cardiovasc Surg (Torino)*. 2015;56:317-24.