

The effects of autologous platelet concentrate on the healing of intra-bony defects: a randomized clinical trial

Purpose

The present study aimed to evaluate the clinical and radiographic effects of autologous platelet concentrate (APC) on the healing of intra-bony defects filled with β -tricalcium phosphate (β -TCP) and covered with collagen membranes.

Subjects and methods

This study included 30 defects of 14 systemically healthy subjects. All of them had, at least, two deep intra-bony, inter-proximal periodontal defects. Minimum probing pocket depth (PPD) was 6 mm. Clinical and imaging examination was performed both at baseline and at 3, 6, and 9 months after surgery.







Results

Both the test and control group revealed a significant reduction in all variables when compared with the base line. Mean reduction of the PPD in two groups at each follow-up time point showed no significant difference. Means of the clinical attachment gain of the same groups were significantly different ($p < 0.05$). Mean gingival recession at 3 month was not significant. However, the means of gingival recession coverage of two groups were significantly different at 6 and 9 months ($p < 0.05$ for both).

Conclusion

Sites treated with APC are more likely to demonstrate more clinical attachment gain and recession coverage at the end of 9 month compared to those without APC.

Keywords: Intra-bony defects; periodontal regeneration; periodontitis; platelet rich plasma; β -tricalcium phosphate

Nitin Kudyar¹ ,
Nitin Dani² ,
Shahab Saquib Abullais³ ,
Nabeeh A. AlQahtani³ ,
Aashima Gupta⁴ ,
Nilofar Attar⁵ 

Introduction

Periodontitis is a site-specific disease that causes periodontal attachment and bone loss (1). In the general population, periodontitis is a common cause of tooth loss (2). One of the important goals of periodontal treatment is to reduce the pocket depth (3). Non-surgical treatment is indicated in cases with moderate periodontitis. On the other hand, standard treatment protocol should be supported with periodontal surgery in the presence of deep pockets and intrabony defects (4).

According to Melcher's hypothesis (5), the selected cell population in the periodontium can regenerate periodontal tissues provided that the cells could occupy the periodontal wound. Guided tissue regeneration (GTR) is a regenerative technique in which a physical barrier was positioned between the flap and the root surface to prevent the migration of the connective tissue and epithelium. This provides an opportunity for the pluripotent ligament cells to multiply on the root surface (6).

Tricalcium phosphate (TCP) is an alloplastic bone substitute which has been extensively researched since the 1970's. This resorption rate of this

ORCID IDs of the authors: N.K. 0000-0003-4882-6795;
N.D. 0000-0002-4254-6920; S.S. 0000-0002-5223-2167;
N.A.A. 0000-0001-5064-7556; AG. 0000-0002-4367-4844;
N.A. 0000-0001-6279-3534

¹Department of Periodontics Himachal Dental College, Mandi, Himachal Pradesh, India

²Department of Periodontics M.G.V Dental College and Hospital, Panchavati, Nasik, Maharashtra, India

³Department of Periodontics and Community Dental Sciences, College of Dentistry, King Khalid University, Abha, Saudi Arabia

⁴Department of Oral medicine and Radiology, Pacific Dental College, Udaipur, Rajasthan, India

⁵Department of Periodontology Government Dental College, Mumbai, India

Corresponding Author: Shahab Saquib Abullais
E-mail: drsaquib24@gmail.com

Received: January 18, 2018

Revised: June 6, 2018

Accepted: October 8, 2018

DOI: 10.26650/eor.20192207101715

material has been reported to be similar to that of the new bone apposition (7). Its potential to stimulate the bone formation is higher than hydroxyapatite, but lower than that of the Bioglass (6,8).

SynOss® (Dentacare, Pune, India) is a commercially available pure phase Beta TCP. It meets the purity requirements for bioceramics of the American standards (ASTM F 1088-87). It is biocompatible, carries no risk of disease transmission and shows no immunogenic reactions (9). SynOss® has unique forms of the granules mimicking the bone macroscopic structure (9). It fully degrades within 6-12 months which is close to the native bone apposition rate, depending on the patient's individual regeneration potential (10).

Various types of absorbable and non-absorbable materials have been tested as membranes for GTR (11,12). Perio-Col® GTR is a bio-absorbable Type I collagen membrane manufactured from the air-bladder of edible fresh water fish. Perio-Col® is a non-toxic, non-allergenic and non-immunogenic biocompatible material (13). Especially when combined with platelet rich plasma, Perio-Col® GTR membrane has shown promising results in the treatment of intra-bony defects (14).

Mitogenesis, chemotaxis and cell differentiation during the repair and/or regeneration process are regulated by growth factors (15). Improved osseous defect fill has been reported in patients treated with platelet derived growth factors (PDGF/IGF-I) during its first human clinical trial (16).

PDGF, insulin-like growth factor (IGF) and transforming growth factor- β (TGF- β) enhance wound healing and provoke regeneration (17). PRP's potential in new bone formation was first reported in 1998 (18). The aim of the present study is therefore to examine the effect of autologous platelet concentrate on periodontal regeneration when used in combination with an alloplastic bone graft and GTR membrane. The null hypothesis of this research is that no difference can be observed between study and control groups.

Subjects and Methods

Study participants

The study was approved by the ethics review and research board (Approval no. 16/2013, MGVS 30134/43246). The study design was a randomized clinical case-controlled trial that follows the guidelines cited by CONSORT. Written, informed consents were obtained from all patients. Thirty defects of 14 systemically healthy patients were included. Male to female ratio was 1:1, their age range was 20 to 55 years and mean age was 34 ± 10.57 years.

Patient selection

Having no contraindication for periodontal surgery, good oral hygiene habits, having at least two intra-bony defects, one at each quadrant or contra-lateral sides of the same region, having minimum 6 mm of probing pocket depths (PPD) and having radiographic angular bone defect of at least 4 mm at baseline were the inclusion criterion. Patients with more than 1 mm of mobility, prosthetic restoration and/or endodontic treatment in the affected teeth, those who are allergic to drugs, pregnant and/or lactating, smokers or having any other contraindication for periodontal surgery were excluded.

Study design

Thirty selected sites in 14 patients were randomly allocated into either one of the Site A or Site B groups stratified by the treatment plan, each site in different quadrants. Defects in Site A were filled with β -TCP mixed with autologous platelet concentrate (APC) and then covered with absorbable collagen membrane (Perio-Col®-GTR). Defects in site B received also a β -tricalcium β -TCP but no APC and they were again covered with the same collagen membrane. The healing process was recorded by following the baseline scores and those registered after 3, 6, and 9 months after surgery. Full mouth plaque index (PI) (19), full mouth papillary bleeding index (PBI) (20), PPD, clinical attachment level (CAL), gingival recession (REC) were determined at each time point. A cast model was obtained from alginate impression and occlusal stents from acrylic resin were fabricated for probe positioning (21).

Radiographic parameters

After initial therapy, standardized radiovisiographs (RVG) (Kodak DS, Rochester, NY, USA) were taken with the RINN XCP system (DENTSPLY, Tulsa, Oklahoma, USA), at baseline, and after 3, 6, and 9 months following surgery. The following landmarks were identified on the radiographs: Cemento-enamel junction (CEJ), base of the defect (BD), alveolar crest (AC), cemento-enamel junction to root apex (RA) (Figure 1). Pre- and post-treatment radiographs (RVG) pairs were compared to investigate the presence of crestal bone resorption (ACC), bone defect filling (BF) and the extent of defect resolution which was calculated with the following formula: $DR = (BF - ACC)$.

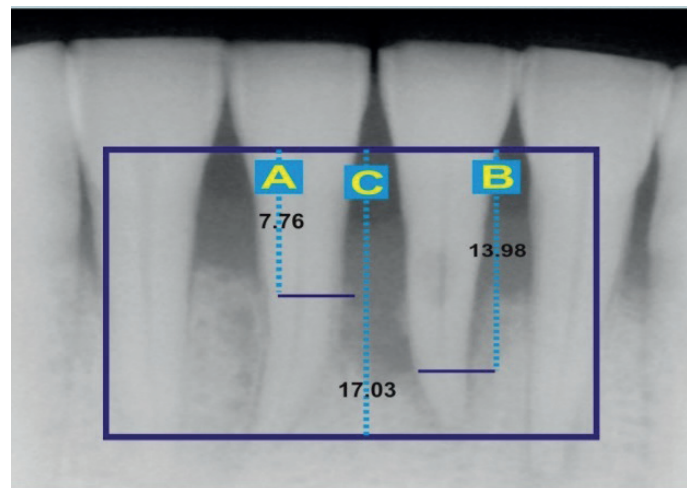


Figure 1. Radiographic planning of the treatment (A: cemento-enamel junction to alveolar crest, B: cemento-enamel junction to base of the defect, C: root).

Surgical procedure

An hour prior to surgery, venous blood was collected and stored in a 10 ml tube that contains 3.2% sodium citrate as anticoagulant. Tubes were then placed in a manual centrifugation device (e-tek, Remi laboratory, India). The first step was completed in 13 minutes at 1000 rpm and the second one in 10 minutes at 2000 rpm. APC was collected from the bottom layer of the test tube (Figure 2). 10% calcium chloride



Figure 2. Autologous platelet concentrate.

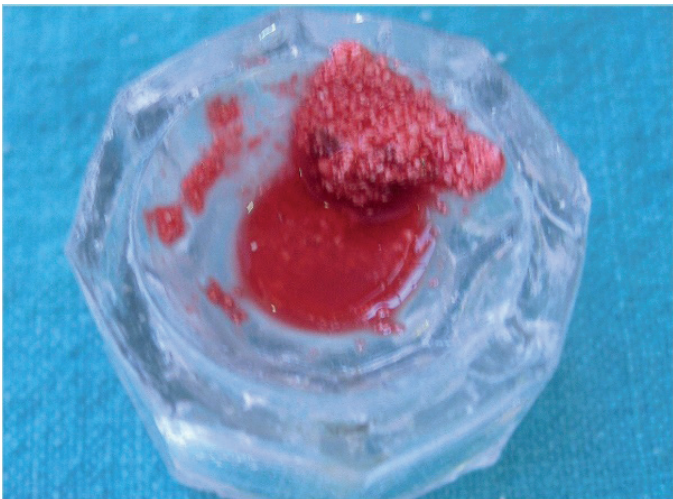

Figure 3. SynOss mixed with autologous platelet concentrate and patients' blood.

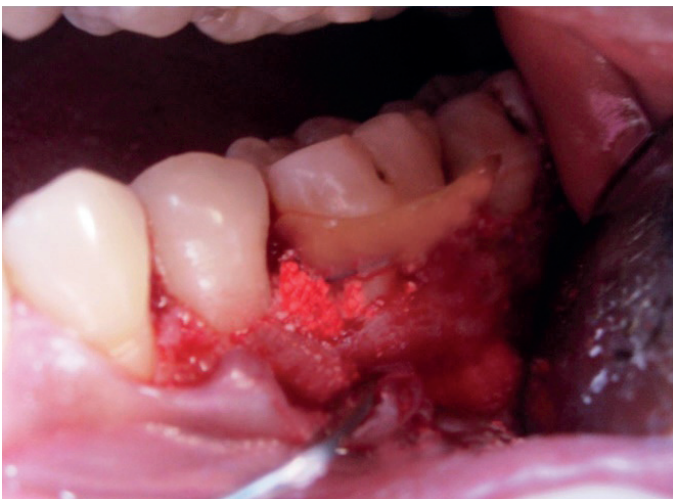

Figure 4. Pre-suturing of the membrane and graft placed in the defect.

was added to activate APC, and then the mixture was left undisturbed for 15-20 minutes to ensure a proper gel formation.

The surgical procedure was performed under local anesthesia, β -tricalcium phosphate granules (SynOss[®]) of 300 μ - 600 μ particle size, were mixed with 2-3 drops of fresh blood from the same defect and then mixed with the coagulated APC (Figure 3). Bio-absorbable membrane (Perio-Col[®]) was used for guided tissue regeneration. The membrane was placed and sutured over the defect with absorbable suture material (Vicryl[®] 4-0 reverse cutting, Ethicon, Johnson and Johnson, India). β -tricalcium phosphate granules mixed with APC was packed in the defect up to the level of the surrounding bony walls (Figure 4). Mucoperiosteal flaps were then approximated and sutured at their initial position using 3-0 silk. In the control sites, the same procedure was carried out, but β -tricalcium phosphate granules were mixed with normal sterile saline instead of APC, and the root surface was not coated with APC. Recall appointments were made after 1, 3, 6, and 9 months post-surgery for clinical evaluation. Post-operative patients' evaluation was done clinically and radiographically at 3, 6, and 9 months (Figure 5 and Figure 6).

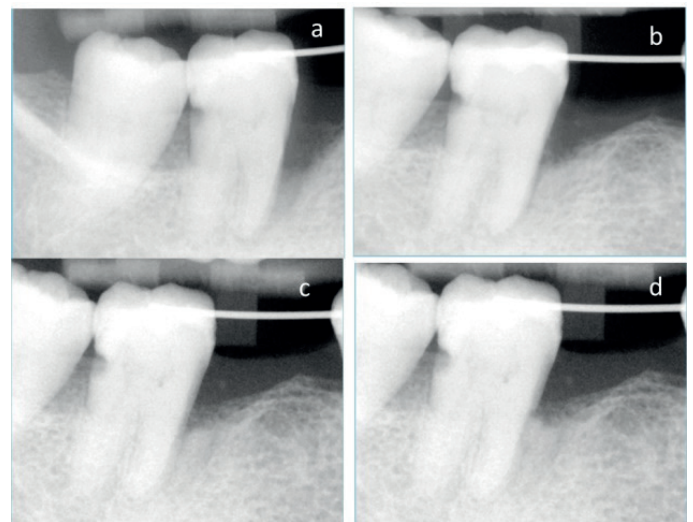


Figure 5. Control site radiographic evaluation at baseline (a), three months (b), six months (c) and 9 months (d).

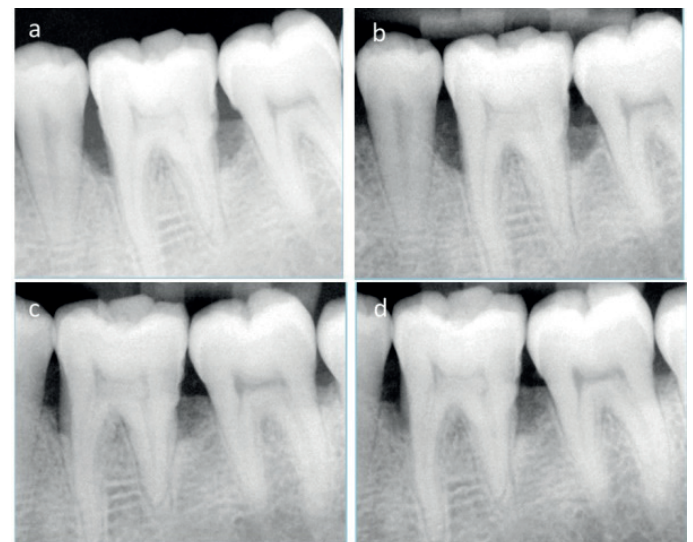


Figure 6. Test site radiographic evaluation at baseline (a), three months (b), six months (c) and 9 months (d).

Statistical analysis

All the clinical and radiographic parameters recorded were transferred to Statistical Package for Social Sciences (SPSS Inc., Chicago, IL, USA), and subjected to the following statistical analysis: the paired-t test was performed to compare intra-group variation, Intergroup variation between the two groups was compared by using a non-parametric, rank test (Mann-Whitney U test). Confidence level was set to 95% and $p < 0.05$ was considered significant.

Results

Of the 14 patients who have completed the study, seven were male and seven were female. The mean baseline PI score was 0.83 ± 0.05 and 0.38 ± 0.17 at 9 months follow up which

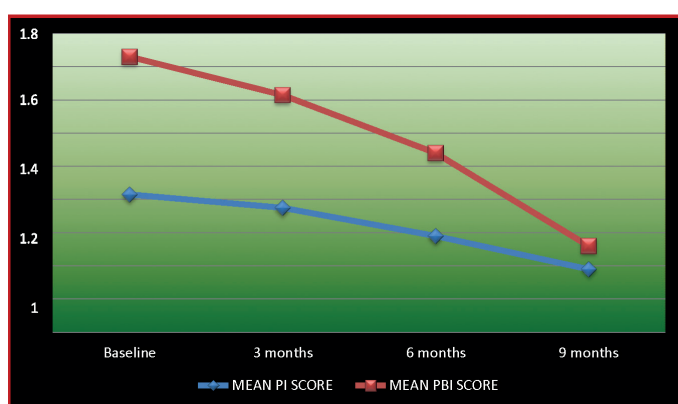

Figure 7. Changes in the mean plaque (PI) and papillary bleeding index (PBI) score over time.

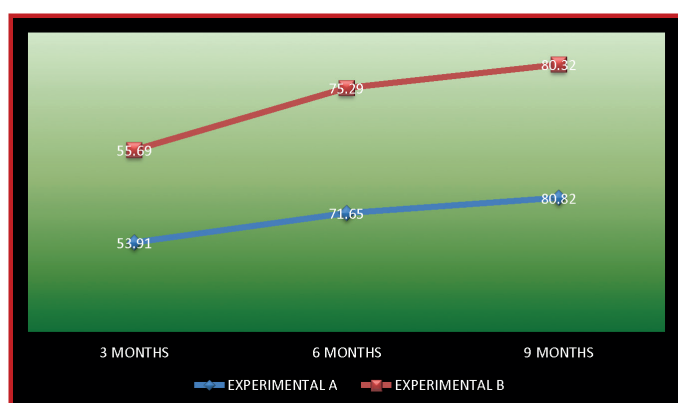


Figure 8. Comparison of the percentage of mean radiographic defect resolution over time.

indicated a significant mean 54% reduction to 0.45 ± 0.19 ($p < 0.001$) (Figure 7). Also, the mean PBI score at baseline (0.83 ± 0.19) dropped down to 0.14 ± 0.14 at 9 months which shows significant 84% reduction (0.69 ± 0.22) ($p < 0.001$) (Figure 8). The reduction in PPD between the baseline and at 9 months was statistically significant in both experimental site A and experimental site B ($p < 0.05$). The CAL between baseline and 9 months was statistically significant in both groups ($p < 0.05$). At 9 month time point, the difference in the mean CAL gain (1.4 mm) was statistically significant ($p < 0.05$) (Table 1). After 9 months from baseline, the mean REC gain was statistically significant in both groups ($p < 0.05$). The mean REC between the two groups at 6 months and 9 months was 0.86 mm and 1.06 mm respectively which was statistically significant ($p < 0.05$) (Table 1).

Both groups showed a statistically significant ($P < 0.001$) gain in bone defect fill compared to the baseline and 1, 3 and 9 months, with the maximum reduction recorded at the end of the 9 month follow-up (Table 1). The mean defect fill was statistically significant in both groups when the baseline was compared to 1, 3 and 9 months, with the maximum defect fill recorded at the 9 month interval ($p < 0.05$ for each). Both groups revealed gradual increase in the defect resolution percentage from baseline to 1, 3 and 9 months. A comparison between the two groups revealed a difference of $1.78 \pm 0.37\%$, $3.57 \pm 0.69\%$ and $0.50 \pm 0.08\%$ at 3 months, 6 months and 9 months respectively, but this was not statistically significant.

Discussion

Histologic evidence gathered from experimental studies indicated that the application of growth factors such as PDGF and IGF might be beneficial in the periodontal regenerative therapy when applied in the short term (21,22). Less post-operative membrane exposures and higher rate of bone apposition have been reported following the use of PRP, β -TCP and GTR up to 6 months although no difference was found at 12 months (23). However, the treatment of bone defects with β -TCP, β -TCP + PRP and β -TCP + GTR did not show significant differences among 3 groups (24).

The present study evaluated the effects of growth factors on GTR, by delivering an increased concentration of growth factors directly to the defect site along with the benefit of the barrier action of the collagen membrane and scaffold effect of the β -TCP bone graft. In this study, the platelet density in the resulting APC preparation was higher (573.27%) than the one obtained by Landesberg (18) (205.7%) and Marx (25) (338%). This difference could be due to variations in the preparation

Table 1. Presentation of the mean and standard deviations of the study variables stratified by the time point parameter (PPD: pocket probing depth, CAL clinical attachment level, REC: recession coverage, BD: bone defect fill, ACC: alveolar crest change, RED: radiographic extent of bony defect).

	Experimental Site A						Experimental site B					
	PPD	CAL	REC	BD	ACC	RED	PPD	CAL	REC	BD	ACC	RED
Base line	8.07 ± 1.53	9.40 ± 1.80	1.60 ± 1.18	11.59 ± 3.56	4.12 ± 2.34	7.47 ± 3.71	7.73 ± 1.39	8.60 ± 2.03	0.87 ± 1.13	9.57 ± 2.51	3.58 ± 1.44	5.99 ± 2.07
3 Months	3.93 ± 1.28	5.53 ± 1.41	1.60 ± 1.12	8.06 ± 2.91	4.39 ± 2.95	3.68 ± 3.11	4.33 ± 0.90	5.53 ± 1.51	1.20 ± 1.21	6.75 ± 3.06	3.98 ± 1.86	2.77 ± 1.98
6 Months	3.27 ± 0.96	4.47 ± 1.46	1.20 ± 1.08	6.76 ± 2.78	4.56 ± 2.92	2.20 ± 2.48	3.40 ± 1.18	4.73 ± 1.83	1.33 ± 1.40	5.99 ± 2.99	4.26 ± 2.28	1.73 ± 1.96
9 Months	2.87 ± 0.83	3.93 ± 1.33	1.07 ± 1.03	5.37 ± 2.27	4.09 ± 2.98	1.28 ± 1.17	3.13 ± 1.19	4.53 ± 2	1.40 ± 1.40	5.42 ± 2.90	3.94 ± 2.10	1.48 ± 2

steps such as force or time. Before being applied to the test defect, 10% calcium chloride solution in 6:1 ratio was used to activate the platelet concentrate. This ratio is the minimal amount of CaCl₂ to neutralize the citrate and induces the platelet concentrate clotting. In contrast to Marx et al.(18), no xenogenous material such as bovine thrombin was added in order to prevent possible infection or contamination. To accelerate the coagulation process, some drops of collected venous blood were added to the β -TCP before mixing it with APC, which is consistent with the work of Appel et al.(26).

Post-operative membrane exposure rate in the control sites of the present study was 13.33% and no membrane exposure was found at the test sites. Growth factors included in the APC might have therefore positively affected the soft tissue closure in test sites. Consistently, PDGF released from platelet's α -granules has been reported to show mitogenic and chemotactic effects on fibroblasts and proliferative effects on endothelial cells (27).

Both test and control groups showed significant reduction in PPD and higher CAL gain after 3, 6, and 9 months compared to baseline values. The PPD reduction and CAL gain was higher in sites treated with APC at 3, 6 and 9 months than those without APC. However, no significant difference was found between the two, although the test site had significantly gained more CAL at 9 months compared to the control site.

All the sites, except for the two in the control group, showed ≥ 3 mm of CAL gain in both groups at the end of 9 months. Around 53.3% of the control and all of the test sites showed CAL gain of ≥ 4 mm at the end of 9 months. Previous studies in which only the membranes were used, CAL gain of at least 4 mm was found in 51.6%, 38.7%, and 69% of cases (28,29). The lower CAL gain found in the present one could be due its longer duration.

The defect fill variable showed an acceptable outcome. In the test site, the mean defect fill was 30%, 42% and 54% at 3 months, 6 months and 9 months respectively, which was highly significant when compared to baseline values. These findings were consistent with others (30). A similar pattern was observed in the control sites with a mean defect fill of 29%, 37% and 43% at 3 months, 6 months and 9 months respectively. This was also significant when compared to the baseline which is line with previous research (31). The difference between the means of two groups, however, was not significant.

Following periodontal surgery, remodeling of the alveolar bone leads to crestal resorption. In the present study, the APC sites showed supracrestal bone formation as compared to the site where APC was not used. However, the results were not statistically significant. In this variable, our findings were not consistent with previous studies where there was no supracrestal bone formation (32). The results obtained in this study with regards to the gain in alveolar crest height at the end of 9 months could be due to the stickiness of the APC gel as well as the small (300-600 μ) particle size of ss-TCP granules. However, the surgical technique used in this study (i.e. pre-suturing of membrane before placement of ss-TCP), could be another reason by preventing the dislodgment of the bone graft due to fresh bleeding because of suturing.

CAL gain found in the present study acted together with significant bone gain in the defects in both groups. The imaging study showed substantial changes in the hard

tissue changes compared to those reported in previous research (33,34). However, this finding should be considered cautiously because of the radiopacity of the bone graft granules. Increased bone turnover rate at 6 weeks after the application of rh-PDGF has been shown previously (35). In addition, positive effects of growth factor combinations, such as IGF-I and PDGF-BB or TGF- β 1 and FGF, on the bone cells' proliferation and activity have been reported in vitro (36).

Conclusion

At 9 months, the PPD reduced and CAL gain increased in both groups. However, the test sites' CAL gain was higher. REC was also more pronounced in the test groups. Both groups showed considerable defect fill rates but no significant difference was observed between them. In addition, although not significant, APC sites showed supracrestal bone formation compared to those without APC. The pre-suturing of the membrane and the use of APC improved the handling properties of β -TCP. APC could have been prepared without the use of bovine thrombin, although it would have taken slightly longer to form a sticky gel and release growth factors.

Acknowledgements: We would to thank Mrs. Pradnya Dani (Director of Operations, Alpha Plus, Nashik) for her assistance in performing statistical analysis.

Ethics committee approval: The study was approved by the ethics review and research board (Approval no. 16/2013, MGV 30134/43246).

Informed consent: Written informed consents were obtained from all patients.

Conflict of interest: The authors have no conflicts of interest to declare.

Financial disclosure: The authors declared that this study has received no financial support.

Peer review: Externally peer-reviewed.

Author contributions: NK, ND and SSA participated in designing the study. NK, NAA and NA participated in generating the data for the study. NK, ND, NAA and AG participated in gathering the data for the study. ND, SSA and NA participated in the analysis of the data. SSA and NAA wrote the majority of the original draft of the paper. NK, SSA and AG participated in writing the paper. All authors approved the final version of this paper.

Türkçe öz: Otojen trombosit konsantrasyonlarının kemik içi defektlerin iyileşmesi üzerine etkisi: randomize kontrollü çalışma. Amaç: Bu çalışma, otojen trombosit konsantrasyonlarının β -trikalsiyum fosfat (β -TCP) ile doldurulmuş ve kollajen membran ile örtülmüş kemik içi defektlerin klinik ve radyografik olarak iyileşmesini incelemeyi amaçlamaktadır. Gereç ve yöntem: Bu çalışma sistemik olarak sağlıklı 14 bireyin 30 defektini içermektedir. Her birinin, en aziki derin kemik içi, interproksimal periodontal defekti bulunmaktadır. Minimum sondalanabilir cep derinliği (SCD) 6 mmdir. Klinik ve görüntü muayenelerinin her biri başlangıç ve cerrahi sonrası 3., 6. ve 9. aylarda yapılmıştır. Sonuç: Hem test hem de kontrol grubu başlangıç seviyesi ile karşılaştırıldığında tüm sonuçlarda anlamlı bir azalma göstermiştir. Her iki grupta da SCD'nin her muayene zamanındaki ortalama azalışı anlamlı bir farklılık göstermemiştir. Aynı grupların ortalama klinik ataşman kazançları anlamlı farklılık göstermiştir ($p < 0.05$). 3. ayda ortalama dişeti çekilmesi kapanması anlamlı değildir. Fakat, her iki grubun 6. ve 9. aylardaki ortalama dişeti çekilmesi kapanma miktarı anlamlıdır ($p < 0.05$ her

ikisi için). Tartışma: OTK ile tedavi edilmiş bölgeler edilmemiş bölgelere oranla 9. ayın sonunda daha fazla klinik ataşman kazancı ve dişeti çekilmesi kapanması göstermeye eğilimlidir. Anahtar kelimeler: Kemik içi defekt; trombositten zengin plazma; β -trikalsiyum fosfat.

References

- Socransky SS, Haffajee AD. Nature of periodontal diseases. *Ann Periodontol* 1997;2:3-10. [CrossRef]
- Dikbas I, Tanalp J, Tomruk CO, Koksal T. Evaluation of reasons for extraction of crowned teeth: a prospective study at a university clinic. *Acta Odontol Scand*. 2013;71:848-856. [CrossRef]
- Zander HA, Polson AM, Heijl LC. Goals of periodontal therapy. *J Periodontol*. 1976 May;47(5):261-6. [CrossRef]
- Caton J, Nyman S, Zander H. Histometric Evaluation of Periodontal Surgery. II Connective tissue attachment levels after four regenerative procedures. *J Clin Periodontol* 1980;7:224-31. [CrossRef]
- Melcher AH. On the repair potential of periodontal tissues. *J Periodontol*. 1976;47:256-260. [CrossRef]
- Nyman S, Lindhe J, Karring T, Rylander H. New Attachment following surgical treatment of human periodontal disease. *J Clin Periodontol*. 1982;9:290-6. [CrossRef]
- Mayubala I, Shivkumar M, Sureshkumar RV, Sastry TP. Bioactivity and Osseointegration Study of Calcium Phosphate Ceramic of different chemical composition. *J Biomed Mater Res*. 2002;63:2:200-8. [CrossRef]
- Wilson J, Low SB. Bioactive ceramics for periodontal treatment: comparative studies in the Patus Monkey. *J Appl Biomater* 1992;3:123-9. [CrossRef]
- Gosain AK, Song L, Riordan P, Amarante MT, Nagy PG, Wilson CR, et al. A 1-year study of osteoinduction in hydroxyapatite-derived biomaterials in an adult sheep model: part I. *Plast Reconstr Surg*. 2002;109:619-30. [CrossRef]
- Koepp HE, Schorlemmer S, Kessler S, Brenner RE, Claes L, Günther KP, Ignatius AA. Biocompatibility and osseointegration of beta-TCP: histomorphological and biomechanical studies in a weight-bearing sheep model. *J Biomed Mater Res B Appl Biomater*. 2004 Aug 15;70:209-17. [CrossRef]
- Busschop J, De Boever J. Clinical and histological characteristics of lyophilized allogenic duramater in periodontal bony defects in humans. *J Clin Periodontol*. 1983;10:399-411. [CrossRef]
- Pitaru S, Tal H, Soldinger M. Partial regeneration of periodontal tissues using collagen barriers. Initial observations in the canine. *J Periodontol*. 1988;59:380-6. [CrossRef]
- Sandhya G, Bal Reddy P, Jeevan Kumar A, Sridhar Reddy B, Prasad N, and Kiran G. Surgical Management of Oro-Antral Communications Using Resorbable GTR Membrane and FDMB Sandwich Technique: A Clinical Study. *J Maxillofac Oral Surg*. 2013 Sep;12:254-9. [CrossRef]
- Anila S, Nandkumar K. To evaluate the efficacy of a Collagen barrier membrane of Fish origin for GTR with or without autologous PRP in the treatment of periodontal intrabony defects. *Trends Biomater Artif Organs*. 2006;20:78-83.
- The American Academy of Periodontology. Position paper-The potential role of growth and differentiation factors in periodontal regeneration. *J Periodontol*. 1996;67:545-53.
- Howell TH, Fiorellini J, Paquette D, Offenbacher S, Antoniadis H, Linch S. Evaluation of platelet derived growth factor – BB / Purified Insulin- Like Growth Factor – I in patients with periodontal disease. *J Dent Res*. 1995;74:253-7.
- Arlson NE, Roach RB Jr. Platelet rich plasma; Clinical Applications in Dentistry. *J Am Dent Assoc*. 2002 Oct;133:1383-6. [CrossRef]
- Marx RE, Carlson ER, Eichstaedt RM, Schimmele SR, Strauss JE, Georgeff KR. Platelet rich plasma-Growth Factor enhancement for one Grafts. *Oral Surg Oral Med Oral Pathol Oral Radiol Endod*. 1998 Jun;85:638-46. [CrossRef]
- Silness J, Loe H. Periodontal disease in pregnancy II. Corelation between oral hygiene and periodontal conditions. *Acta Odont Scand*. 1964;24:747-59. [CrossRef]
- Saxer UP and Muhlemann H. Motivation and Education. *SSO Schweiz Monatsschr Zahnheilkd*. 1975 Sep;85(9):905-19.
- Camargo PM, Lekovic V, Weinlander M, Vasilic N, Madzarevic M, Kenney EB. Platelet rich plasma and bovine porous bone mineral combined with guided tissue regeneration in the treatment of intrabony defects in humans. *J Periodont Res*. 2002;37:300-6. [CrossRef]
- Wang HL, Pappert TD, Castelli WA, Chiego Jr. DJ, Shyr Y and Smith BA. The effect of platelet derived growth factor on the cellular response of the periodontium: An auto-radiographic study on dogs. *J Periodontol*. 1994;65:429-36. [CrossRef]
- Rutherford RB, Niekrash CE, Kennedy JE, Charette MF. Platelet derived and insulin like growth factors stimulate regeneration of periodontal attachment in monkeys. *J Periodont Res*. 2002;27:285-90. [CrossRef]
- Christgau M, Moder D, Wagner J, Glässl M, Hiller KA, Wenzel A, Schmalz G. Influence of autologous platelet concentrate on healing on intrabony defects following guided tissue regeneration therapy: A randomized Prospective Clinical Split-Mouth Study. *J Clin Periodontol*. 2006;33(12):908-21. [CrossRef]
- Yassibag-Berkman Z, Tuncer O, Subasioglu T, Kantarci A. Combined use of platelet rich plasma and bone grafting with and without guided tissue regeneration in the treatment of anterior interproximal defects. *J Periodontol*. 2007;78:801-9. [CrossRef]
- Massague J. The TGF-beta family of growth and differentiation factors. *Cell* 1987;49:437-8. [CrossRef]
- Appel TR, Pötzsch B, Müller J, von Lindern JJ, Bergé SJ, Reich RH. Comparison of three different preparations of platelet concentrates for growth factor enrichment. *Clin Oral Impl Res* 2002;13:522-8. [CrossRef]
- Ross R. Platelet-derived growth factor. *Lancet*. 1989 May 27;1(8648):1179-82. [CrossRef]
- Christgau M, Bader N, Felden A, Gradl J, Wenzel A, Schmalz G. Guided tissue regeneration in intrabony defects using an experimental bioresorbable polydioxanone (PDS) membrane. A 24-month split-mouth study. *J Clin Periodontol*. 2002;29:710-23. [CrossRef]
- King GN, King N, Hughes F. Effect of two delivery systems for rhBMP-2 on periodontal regeneration in vivo. *J Periodont Res*. 1998;33:226-34. [CrossRef]
- Lekovic V, Camargo PM, Weinlander M, Vasilic N, Alesiz, Canney EG. Effectiveness of a combination of platelet rich plasma, bovine porous bone mineral and guided tissue regeneration in the treatment of mandibular grade II furcation in humans. *J Clin Periodontol*. 2003;30:746-51. [CrossRef]
- Lioubavina-Hack N, Carmagnola D, Lynch SE, Karring T. Effect of bio-oss with or without platelet derived growth factor on bone formation by guided tissue regeneration: A pilot study in rats. *J Clin Periodontol*. 2005;32:1254-60. [CrossRef]
- Brägger U, Hämmerle CF, Mombelli A, Bürgin W. and Lang NP. Remodelling of periodontal tissues adjacent to sites treated according to the principles of guided tissue regeneration (GTR). *J Clin Periodontol*. 1992;19:615-24. [CrossRef]
- Christgau M, Bader N, Felden A, Gradl J, Wenzel A, Schmalz G. Guided tissue regeneration in intrabony defects using an experimental bioresorbable polydioxanone (PDS) membrane. A 24-month split-mouth study. *J Clin Periodontol*. 2002;29:710-23. [CrossRef]
- Sarment DP, Cooke JW, Miller SE, Jin Q, McGuire MK, Kao RT, et al. Effect of rhPDGF-BB on bone turnover during periodontal repair. *J Clin Periodontol*. 2006;33:135-40. [CrossRef]
- Giannobile WV, Whitson SW, Lynch SE. Non-coordinate control of bone formation displayed by growth factor combinations with IGF-I. *J Dent Res*. 1997;76:1569-78. [CrossRef]