

Ateşli Silah Yaralanması Sonrası Geç Dönemde Gelişen Torakobiliyer Fistül Olgusu

Thoracobiliary Fistula Developing At a Late Stage After a Gunshot Injury

Mehmet ERGİN¹, Mahmut TOKUR²

*1 Kahramanmaraş Devlet Hastanesi Acil Servisi, Kahramanmaraş, Türkiye
2 Kahramanmaraş Devlet Hastanesi Göğüs Cerrahisi Kliniği, Kahramanmaraş, Türkiye*

ABSTRACT

Thoracobiliary fistula (TBF) is a rare but highly serious complication of thoraco-abdominal trauma. The most significant factor in the early diagnosis of TBF is considered to be a laceration of the diaphragm and accompanied mostly by hepatic injury in the trauma of lower thoracic region. Fever, chills, biliptysis, abdominal and chest pain, pleural effusion, hepatomegaly and leucocytosis are among the most common presenting symptoms of TBF. Existence of indirect bilirubin in sputum and/or pleural fluid is also supporting agents in the diagnosis. Even though there exist no optimal management of TBF, surgical and conservative approaches in its management are available. In cases where TBF treatment is started late, development of bile empyema with acute necrotizing bile bronchiolitis, pneumonia and sepsis is inevitable. In this article, a biliary-bronchial fistula case, which developed as a late complication after a gunshot injury and resulted in mortality, is presented.

Keywords: *Gunshot Injury, Penetrating Trauma, Thoracobiliary Fistula.*

Received : 01.06.2010 **Accepted :** 23.08.2010

ÖZET

Torakobiliyer fistül (TBF) nadir ancak torako-abdominal travmanın ciddi bir komplikasyonudur. TBF'nin erken tanısında en önemli faktör, alt torasik bölge travmasında diyafram lacerasyonu ve eşlik eden hepatik yaralanmadan şüphelenmesidir. Ateş, titreme, biliptizi, karın ve göğüs ağrısı, plevral effüzyon, hepatomegali ve lökositoz en yaygın başvuru semptomlarıdır. Balgam ve/veya plevral sıvıda indirekt bilirubin varlığı tanıyı destekler. TBF tedavisi için optimum bir yöntem olmamakla birlikte, cerrahi ve konservatif yaklaşımlar mevcuttur. TBF tedavisinde geç kalınırsa, safra ampiyemi ile akut nekrotizan safra bronşiyoliti, pnömoni ve sepsis kaçınılmazdır. Bu yazıda ateşli silah yaralanma sonrası geç dönemde gelişen ve mortal seyreden bir torakobiliyer fistül olgusu sunulmaktadır.

Anahtar Sözcükler: *Ateşli Silah Yaralanması, Penetran Travma, Torakobiliyer Fistül.*

Başvuru Tarihi : 01.06.2010 **Kabul Tarihi :** 23.08.2010

Yazışma Adresi/Corresponding to:

Dr. Mehmet Ergin
Kahramanmaraş Devlet Hastanesi Acil Servisi,
Egemenlik Mah. Cahit Zarifoğlu Cad. 52/7 Kahramanmaraş - Türkiye
e-mail: drmehmetergin@gmail.com
Tel: 0 532 345 26 73

INTRODUCTION

Thoracobiliary fistula (TBF) is a rare but highly serious complication of thoraco-abdominal trauma. Ideal clinical manifestation in the development of TBF would involve hepatic injury with penetrating thoraco-abdominal trauma⁽¹⁻³⁾.

CASE REPORT

A 34-year-old male patient was admitted to the emergency department (ED) due to a gunshot injury with shock findings. The bullet on entry was approximately 2 centimeters (cm.) above his right breast. The bullet was palpated subcutaneously on the left 8th costovertebral junction level (Figure 1A). Decreased respiratory sounds on right hemithorax and loss of weakness on both lower extremities together with fecal incontinence were observed. In the computerized thorax tomography (CTT), the right lung lower lobe contusion, the right hemopneumothorax, and the liver dome contusion with air densities were detected (Figure 1B and C).

During urgent thoracotomy, pervasive bleeding on the right liver lower lobe and in the liver dome, contusion and necrosis areas were noticed. Liver lower lobe and transdiaphragmatic repairs of parenchymal injuries in the liver dome, diaphragm repairs, and bleeding control were performed. On the postoperative 10th day, all of the drains were removed and the patient was transferred to the neurosurgical service for treatment of vertebral fractures. The patient was discharged on the thirty-third day following his initial gunshot injury.

Two days after his discharge, he presented to the ED with the complaint of biliary expectoration. Respiratory insufficiency developed immediately. During urgent thoracotomy, persistent bile empyema in the thorax, pervasive necrotic areas in the lower lobe of the lung, bile leak into the thorax through bronchopleural fistula and suture lines in the diaphragm was observed. Resection of necrotic areas in the lower lobe, diaphragm repair, T Tube drainage in biliary tract, together with cholecystectomy and two drains on bottom and one under diaphragm were performed. A wide-spectrum antibiotherapy was initiated. On the postoperative thirty-sixth hour, fever and respiratory problems occurred again; on the forty-eighth hour, biliary expectoration and biliary fluid drainage through tubes thoracostomy were again observed. The patient developing respiratory insufficiency rapidly became exitus on the forty-sixth day following his initial gunshot injury.

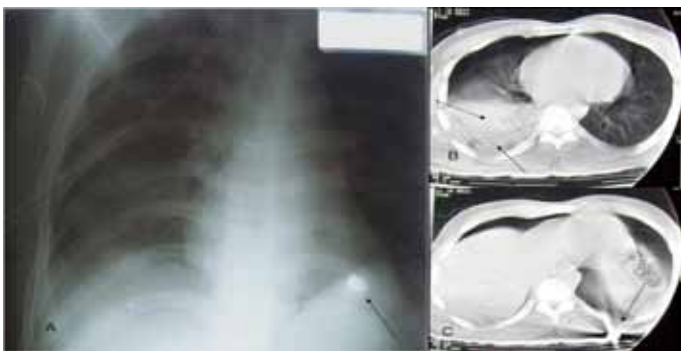


Figure: The bullet was at the left 8th costovertebral junction level on chest x-ray (A). In the computerized thorax tomography (CTT), the right lower lobe contusion and hemopneumothorax, the liver dome contusion with air densities and bullet were detected (B and C).

DISCUSSION

Among other causes of TBF, obstructive biliary duct diseases together with infective liver diseases are conceived as leading causes. Rarely thoracoabdominal traumas, particularly gunshot injuries, are considered another important etiological factor⁽¹⁻³⁾. Even though there is no definite incidence, it is reported in the literature that of all hepatic injuries, only in 2 to 4% of the cases, TBF was observed⁽²⁾. Liver injury, which obstructs biliary tract with laceration of diaphragm, is crucial in development of 'pleuro-biliary fistula'. Following accumulation of bile in thorax, bile empyema occurs and drainage of the residual cavity with tubes exteriorized through thoracic wall is performed. A clear bronchus and lung damage added to this picture will result in development of 'broncho-biliary fistula'. Patients also have histories of biliary expectoration (biliaryptysis)⁽¹⁻³⁾.

Right upper quadrant pain, chest pain, biliaryptysis, fever, chills, hepatomegaly with leucocytosis are observed in cases. It has also been reported that in all of the patients' lung graphic findings, pleural effusion is detected⁽¹⁻³⁾. Yet, jaundice is rare^(1,2). In our case, there were complaints of biliaryptysis and fever, and pleural effusion was detected through lung graphy and CTT.

Biliaryptysis is a patognomic finding regarding broncho-biliary fistula^(1,2). Either pleural effusion or fluid examinations gathered by tube thoracostomy contribute in the diagnosis of pleuro-biliary fistula cases⁽¹⁻³⁾. In our case, biliary fluid drainage through tube thoracostomy was observed. In the diagnosis of TBF, some techniques such as bronchography, fistulagraphy, endoscopic retrograde cholangiopancreatography, and noninvasive nuclear techniques are being used⁽¹⁻³⁾.

There exists no optimum protocol agreed upon in the literature on the management of TBF⁽¹⁻³⁾. It is striking that surgical methods are successful at a rate of 97%, and conservative approaches involving tube thoracostomy and antibiotherapy fail at a rate of 37%^(1,2). In our case, urgent surgery was practiced due to massive biliaryptysis and respiratory problem that developed rapidly. However, serious progress has recently been reported on conservative management approaches owing to development in endoscopic and radiologic initiatives⁽³⁾. Antibiotherapy is combined to the treatment being applied⁽¹⁻³⁾.

CONCLUSION

TBF is a rare but highly serious complication observed after thoraco-abdominal trauma. The most crucial point in diagnosis is to suspect in the convenient clinical scenario. Even though the success rate of surgical treatment is quite high in TBF management, conservative management alternatives should also be reviewed.

REFERENCES

1. Posacioğlu H, Şen S, Çıkrıkçıoğlu M, Taylan İ, Soydemir H, Koşar A, et al. Ateşli silah yaralanmasına bağlı oluşan torakobilyer fistüllerin tanı ve tedavisi. [Article in Turkish] *Ulus Travma Acil Cerrahi Derg* 2000;6:61-5.
2. Navsaria PH, Adams S, Nicol AJ. Traumatic thoracobiliary fistulae. *Ann Thorac Surg* 2002;73: 1088-91.
3. Sing H, Moodley J, Sheik-Gafoor MH, Dhooma N, Reddi A. Conservative management of thoracobiliary fistula. *Ann Thorac Surg* 2002;73:1088-91.