

# Warfarin Induced İliopsoas Hematoma Detected by Bedside Emergency Ultrasonography *Yatak Başı Acil Ultrasonografi ile Tespit Edilen Warfarine Bağlı İliopsoas Hematomu*

**Fırat Bektaş, Seçgin Söyüncü**

*Department of Emergency Medicine, Akdeniz University, Antalya*

## ABSTRACT

Warfarin is frequently used as an oral anticoagulant in a variety of clinical settings, e.g. atrial fibrillation or following valvular heart disease. The most serious and common complication associated with anticoagulation using warfarin is bleeding. Hemorrhage into the iliopsoas muscle causing femoral neuropathy is an infrequent complication of anticoagulant therapy. Two women, 53 and 70 year-old, each with a history of mitral valve replacement surgery, presented at the emergency department with right hip pain. They had been taking warfarin 5 mg once a day since their operations. Physical examinations were normal except for the right hip pain, on movement and femoral nerve palsy in the second patient. Prothrombin, activated prothrombin time and international normalized ratio were prolonged. In order to make the differential diagnosis, we decided to perform bedside emergency ultrasound examination. Ultrasound examination of the patients showed an anechoic lesion in the area of the right iliopsoas muscle. They were admitted to hospital for observation and treatment. Fresh frozen plasma and vitamin K were given for treatment. The possibility of iliopsoas hematoma should be considered in any patient with hip pain undergoing anticoagulant treatment.

**Keywords:** *İliopsoas hematoma, warfarin, anticoagulant therapy*

**Received:** 23.05.2011

**Accepted:** 29.06.2011

## ÖZET

Warfarin atriyal fibrilasyon, valvüler kalp hastalığı vb. gibi klinik durumlarda kullanılan oral antikoagülan bir ilaçtır. Antikoagülan olarak warfarin kullanan hastalarda en ciddi ve en sık görülen komplikasyon kanamadır. İliopsoas kası içine kanayarak oluşan femoral nöropati antikoagülan tedavinin sık görülmeyen bir komplikasyonudur. 53 ve 70 yaşında mitral kapak replasmanı yapılan iki bayan hasta kalça ağrısı nedeniyle acil servise getirildi. Hastalar geçirdikleri kalp operasyonlarından bu yana 5 mg/gün warfarin tedavisi almaktaydı. Her iki hastada kalça hareketlerinde ağrı ve ikinci hastada femoral sinir paralizisi bulguları dışında fizik muayene bulguları normaldi. Protrombin, Aktive edilmiş protrombin zamanı ve INR düzeyleri artmıştı. Acil serviste yapılan ultrasonografik görüntülemelerde sağ iliopsoas kas bölgesinde hematoma mevcuttu. Hastalar gözlem ve tedavi için hastaneye yatırıldı. Taze donmuş plazma ve K vitamini hastaların tedavisinde kullanıldı. Oral antikoagülan kullanan ve kalça ağrısı nedeniyle acil servise getirilen bütün olgularda iliopsoas hematomu varlığı araştırılmalıdır.

**Anahtar Kelimeler:** *İliopsoas hematomu, warfarin, antikoagülan tedavi*

**Başvuru Tarihi:** 23.05.2011

**Kabul Tarihi:** 29.06.2011

## Corresponding to/Yazışma Adresi:

Fırat Bektaş  
Akdeniz Üniversitesi Tıp Fakültesi,  
Acil Tıp Anabilim Dalı Kampus, 07059 Antalya, Türkiye  
GSM: 0533 647 29 42  
e-mail: fbektas@akdeniz.edu.tr

## INTRODUCTION

Warfarin is frequently used as an oral anticoagulant in a variety of clinical settings, e.g. atrial fibrillation or following valvular heart disease. The most serious and common complication associated with anticoagulation using warfarin is bleeding. Hemorrhage into the iliopsoas muscle causing femoral neuropathy is an infrequent complication of anticoagulant therapy (1). We present two cases of iliopsoas hematoma secondary to usage of warfarin therapy diagnosed with bedside emergency ultrasonography (EUS).

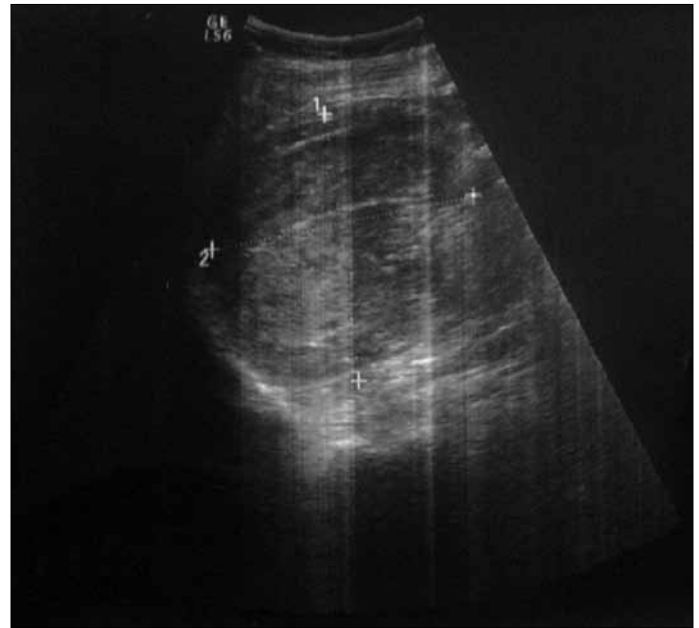
## CASE REPORT

**Case 1:** A 53-year-old woman with a history of mitral valve replacement surgery two years previously presented at the emergency department (ED) after right hip pain of 2 days duration. She had been taking warfarin 5 mg once a day for two years. In the ED, the patient's vital signs were as follows: blood pressure was 159/99 mm-Hg, heart rate 117/min, respiratory rate 19/min and body temperature 36.6°C. Physical examination was normal except for right hip pain on movement. Prothrombin (PT) and activated prothrombin time (aPTT) and International Normalized Ratio (INR=7.25) were prolonged. In order to make the differential diagnosis, we decided to perform an EUS. Sonographic examination of the patient showed 11 cm x 10 cm x 10 cm anechoic lesion in the right iliopsoas muscle (Figure 1). She was admitted to hospital for treatment. Vitamin K and fresh frozen plasma (FFP) were given. In 24 hours, symptoms, signs and INR (1.25) resolved almost completely and the patient showed no signs of hemodynamic instability at any time. She was discharged from the hospital fully recovered 3 days later.

**Case 2:** A 70-year-old woman with a history of mitral valve replacement surgery eleven years previously presented at the ED with right hip pain which had started 4 days earlier. She had been taking warfarin 5 mg once a day since her operation. In the ED, the patient's vital signs were as follows: blood pressure was 117/83 mm-Hg, heart rate 70/min, respiratory rate 21/min and body temperature 36.1 °C. Physical examination was normal except for right hip pain on movement and right femoral nerve palsy. Femoral and foot pulses were also normal. Prothrombin (PT), activated prothrombin time (aPTT) and International Normalized Ratio (INR=6.71) were prolonged. In order to make the differential diagnosis, we decided to perform an EUS. Sonographic examination of the patient showed a 15 cmx8 cmx8 cm anechoic lesion in the right iliopsoas muscle. She was admitted to hospital and treated with Vitamin K and FFP. In 24 hours, symptoms, signs and INR (2.42) resolved. She showed no signs of hemodynamic instability at any time, as in the first case. She was discharged from hospital with minimal numbness or paraesthesia 7 days later.

## DISCUSSION

Anticoagulation is very effective for primary and secondary prevention of thromboembolic events. Warfarin sodium is the best known and most widely used anticoagulant. The most common complication of warfarin therapy is bleeding in the genitourinary



**Figure 1.** Sonographic examination of the patient showed a 11 cm x 10 cm x 10 cm anechoic lesion in the right iliopsoas muscle

and gastrointestinal tracts, skin, central nervous system, nose, penis, or retroperitoneum. Major bleeding, which includes intracranial hemorrhage and bleeding leading to death or hospitalization, has been reported in 1.2%-8.1% of patients during each year of long-term warfarin therapy (1). An iliopsoas hematoma as in our patients is a rare and unexpected complication. It can occur either spontaneously or secondary to trauma or bleeding tendency due to hemophilia and anticoagulant therapy or retroperitoneal hemorrhage (2-4). Differential diagnoses of the iliopsoas hematoma include infection/abscess, metastatic or local tumors, soft tissue inflammation such as bursitis, post-operative seromas, urinoma and pseudoaneurysms involving the iliopsoas (5). Early symptoms of iliopsoas hematoma are hip pain. If the hematoma is growing, this increases the pressure in the iliopsoas compartment, leading to compressive femoral neuropathy. The presentation is an acute unilateral lower limb numbness or paraesthesia. The other feature that points to the diagnosis is the presence of a flexed hip on the involved site that is tender on passive extension (5). There were a number of case reports with spontaneous iliopsoas hematoma complicated by femoral nerve palsy in the medical literature (4-9). These cases vary in their severity. Our cases are more benign than other cases. The differential diagnosis of iliopsoas hematoma was made by ultrasonography, computed tomography (CT) and magnetic resonance imaging. The diagnostic utility of bedside EUS for detecting iliopsoas hematoma, has not been determined in the medical literature but, especially in unstable patients, EUS may be a useful technique for detecting iliopsoas hematoma. Other advantages of the EUS are that it is cheap, non-invasive, non-ionized and easy to perform. As a result, EUS may enhance the emergency physician's performance by shortening of length of stay in the ED, reducing the number of unnecessary tests to be ordered, and hastening critical therapeutic interventions. However, this technique is dependent on the operator, affordability and skill training. Both patients in this review were diagnosed using bedside EUS. CT

images are superior to ultrasonography in displaying the density, site and extent of a retroperitoneal hematoma. The gold standard diagnostic modality of the iliopsoas hematoma is (MR) Magnetic Resonant imaging. The deep location of the muscle and the presence of overlying bowel loops make ultrasonographic assessment difficult (3). However, MR imaging may be expensive, time consuming and troublesome for patients. When the patients are unstable, this technique cannot be performed in the ED. Treatment of Warfarin induced iliopsoas hematoma is conservative, including fluids, transfusion, and reversal of anticoagulation. Oral anticoagulant should be immediately reversed with FFP, followed by vitamin K; FFP is rich in active vitamin K-dependent coagulation factors and will reverse oral anticoagulant-induced coagulopathy in most patients. In general, approximately 15 mL/kg of FFP should be adequate to reverse any coagulopathy (6). Because the rate of permanent motor deficit is low, the role of surgical decompression is limited and controversial. Transarterial catheter embolization of the feeding lumbar arteries offers a valuable therapeutic option in selected patients (3).

## CONCLUSION

In summary, the possibility of iliopsoas hematoma should be considered in any patient with hip pain undergoing anticoagulant treatment, if APTT and PT-INR values are in the 'non-therapeutic' anticoagulation range. In the presence of hip pain or neurological deficit, ultrasonography or CT must be performed immediately to detect iliopsoas hematoma.

## REFERENCES

1. Gallus AS, Baker RI, Chong BH, Ockelford PA, Street AM. Consensus guidelines for warfarin therapy. Recommendations from the Australasian Society of Thrombosis and Haemostasis. *Med J Aust.* 2000; 172: 600-5.
2. Parmer SS, Carpenter JP, Fairman RM, Velazquez OC, Mitchell ME. Femoral neuropathy following retroperitoneal hemorrhage: case series and review of the literature. *Ann Vasc Surg.* 2006; 20: 536-40. [\[CrossRef\]](#)
3. Cronin CG, Lohan DG, Meehan CP, Delappe E, McLoughlin R, O'Sullivan GJ, et al. Anatomy, pathology, imaging and intervention of the iliopsoas muscle revisited. *Emerg Radiol.* 2008; 15: 295-310. [\[CrossRef\]](#)
4. Ong HS. Compressive femoral neuropathy: a rare complication of anticoagulation. *Singapore Med J.* 2007; 48: e94-5.
5. Seijo-Martinez M, Castro del Rio M, Fontoira E, Fontoira M. Acute femoral neuropathy secondary to an iliacus muscle hematoma. *J Neurol Sci.* 2003; 209: 119-22. [\[CrossRef\]](#)
6. Cruickshank J, Ragg M, Eddey D. Warfarin toxicity in the emergency department: Recommendations for management. *Emerg Med (Fremantle).* 2001; 13: 91-7. [\[CrossRef\]](#)
7. Wada Y, Yanagihara C, Nishimura Y. Bilateral iliopsoas hematomas complicating anticoagulant therapy. *Intern Med.* 2005; 44: 641-3. [\[CrossRef\]](#)
8. Marquardt G, Barduzal Angles S, Leheta F, Seifert V. Spontaneous haematoma of the iliac psoas muscle: a case report and review of the literature. *Arch Orthop Trauma Surg.* 2002; 122: 109-11. [\[CrossRef\]](#)
9. Kwon OY, Lee KR, Kim SW. Spontaneous iliopsoas muscle hematoma. *Emerg Med J.* 2009; 26: 863. [\[CrossRef\]](#)