



# Tension Pneumocephalus and Brain Abscess Due to Penetrating Head Trauma in a Child

## Bir Çocukta Penetran Kafa Travmasına Bağlı Tansiyon Pnömocefali ve Beyin Apsesi

Ali Riazi<sup>1</sup>, Samad Shams Vahdati<sup>2</sup>, Arezou Tajlil<sup>3</sup>, Leila Rasi Marzabadi<sup>3</sup>

<sup>1</sup>Department of Neurosurgery, Tabriz University of Medical Science, Tabriz, Iran

<sup>2</sup>Department of Emergency, Tabriz University of Medical Science, Tabriz, Iran

<sup>3</sup>Tabriz University of Medical Science, Tabriz, Iran

### ABSTRACT

Penetrating brain injuries are uncommon causes of head trauma with serious complications. In this case study, we describe a six-year-old child with penetrating head trauma that occurred four days before presentation. The foreign body was removed by the parents on the first day, but the child had become progressively ill and experienced headache and vomiting. With the presence of fever and a stiff neck, we considered meningitis. The CT scan of the brain revealed tension pneumocephalus and a brain abscess. IV antibiotics were given, and surgery was performed. In a patient with penetrating head trauma, we should consider various complications and assess the presence of them to avoid future sequelae.

**Keywords:** Tension pneumocephalus, brain abscess, penetrating head trauma

**Received:** 02.12.2011 **Accepted:** 06.01.2012

### ÖZET

Penetran beyin yaralanmaları, ciddi komplikasyonlu kafa travmalarının nadir sebepleridir. Bu olgu sunumunda, başvurudan dört gün önce penetran kafa travması geçirmiş 16 yaşında bir çocuk vakayı tanımlamaktayız. Yabancı cisim ebeveynleri tarafından ilk günde çıkarıldı, ancak çocuk giderek artan şekilde hastalandı ve baş ağrısı ve kusma yaşadı. Ateş ve ense sertliği varlığından dolayı menenjit düşündük. Bilgisayarlı beyin tomografisi taraması tansiyon pnömocefali ve beyin apsesi olduğunu gösterdi. İntravenöz antibiyotikler verildi ve ameliyat edildi. Penetran kafa travması bir hastada çeşitli komplikasyonları düşünmeliyiz ve gelecekteki se-kelleri önlemek için varlıklarını değerlendirmeliyiz.

**Anahtar Kelimeler:** Tansiyon pnömocefali, beyin apsesi, penetran kafa travması

**Geliş Tarihi:** 02.12.2011 **Kabul Tarihi:** 06.01.2012

### Introduction

Head trauma can be classified as blunt or penetrating. Penetrating head trauma is uncommon but can have serious complications. Various objects have been described as causing such injuries. When dealing with these cases, sufficient attention should be paid because underestimating the importance of the trauma can cause complications, even years later. In this case study, we report on a six-year-old child with a penetrating head trauma that had occurred four days before presentation with progressive symptoms.

### Case Report

A rural six-year-old girl presented to the emergency center, complaining about vomiting and headache. Four days earlier, her brother had shot an iron nail with a bow, and it had hit her forehead above her left eyebrow. Her parents had removed the nail from the wound at home, but they had not sought any medical care at that time. Over a period of four days, the child had become progressively ill and started to experience headache, nausea and vomiting. In her past medical history, she did not have any previous problems, and she did not use any medications. Upon physical examination in the emergency room, it was apparent that she was ill. She had a body temperature of 37.9°C, and all other vital signs were stable. Her GCS (Glasgow Coma Scale) was 11/15 (E3V3M5).

Performing a brain CT scan can help in the diagnosis and management of complications. There was a very small laceration above her left eyebrow, and she had suspicious neck stiffness. Her pupils were isocoric and reactive to light stimulation. The cranial nerves were intact and Babinski's sign was absent. Her lungs were clear to auscultation. The heart exam showed a regular rhythm with

### Address for Correspondence/Yazışma Adresi:

Dr. Samad Shams Vahdati, No1, Golestan 2, Pezeshkan Alley, Abrasani Street Tabriz, Iran  
Phone: 00984116581401 E-mail: sshamsv@yahoo.com

©Copyright 2012 by Emergency Physicians Association of Turkey - Available on-line at www.jaemcr.com

©Telif Hakkı 2012 Acil Tıp Uzmanları Derneği - Makale metnine www.jaemcr.com web sayfasından ulaşılabilir.

normal sounds and without any murmurs, rub or gallop. Her abdomen was soft to the touch without any abnormal findings.

Regarding her fever and stiff neck, we suspected the presence of meningitis. A CT (computed-tomography) scan was performed (Figure 1).

With a diagnosis of tension pneumocephalus, meningitis and a brain abscess, IV antibiotics were started and surgery was performed the same day. With frontal craniotomy, the brain abscess, necrotic tissue and air were evacuated. Hemostasis was established, and duraplasty was performed.

## Discussion

Head trauma can be either blunt or penetrating. Penetrating brain injuries have a higher mortality rate than closed brain injuries (1). Such injuries are uncommon in children and mostly occur as a result of gunshots, but various objects have been reported to cause brain injury. Nails, wooden foreign bodies, stones and umbrella tips are examples of reported objects (2-6). The patient may have minimal symptoms when the accident happens, so they may not seek medical care or even minimal findings at presentation, which can lead to misdiagnosis (2, 5, 6). Penetrating brain injuries can cause significant complications and a prompt diagnosis and treatment of complications improve the prognosis (3, 4). Even in the presence of a very small laceration on the head, there may be very serious damage and future complications (2). Brain abscess, meningitis, vascular complications, superficial and deep infections, seizures, cerebrospinal fluid fistulae and pneumocephalus are reported complications from penetrating head traumas (3, 5-11). In managing the patient, the foreign body should not be taken out carelessly since there is a risk of bleeding, and the presence of a broken part of the object can lead to future complications (2).

The incidence of septic complications of low velocity penetrating head injuries is reported to be higher in children than in adults (12).

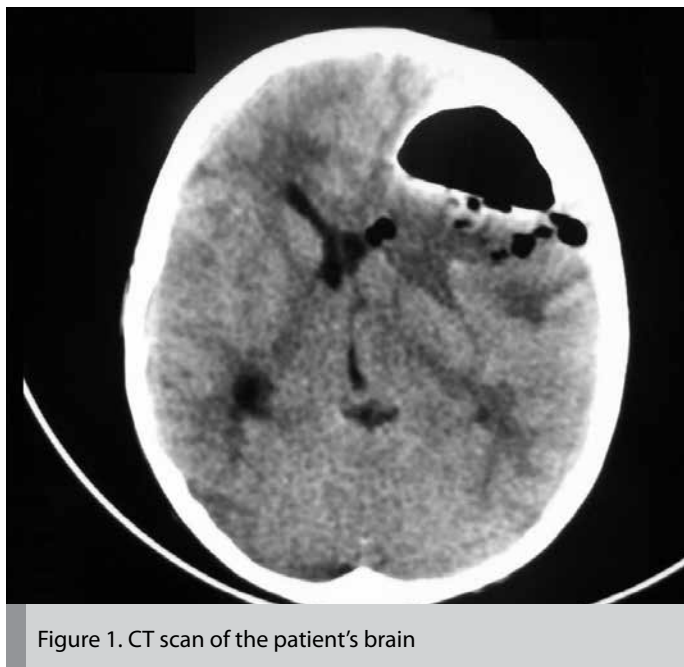


Figure 1. CT scan of the patient's brain

In recent years, there has been an increase in brain abscesses due to neurosurgery and trauma (13). There are some reports of cases who presented with brain abscesses months or years after a penetrating head trauma (2, 5, 6). As mentioned before, intracerebral pneumocephalus following a penetrating head injury can occur, but it is a rare condition (8, 10, 11).

Pneumocephalus is commonly caused by surgical procedures, but it can be a consequence of trauma or other causes. Tension pneumocephalus is a type of pneumocephalus in which the gas is collected in intracranial compartments under pressure compared to the outside atmospheric pressure. Pneumocephalus can present as a headache, nausea, vomiting, seizures, dizziness and a depressed neurological state. A CT scan can confirm the diagnosis (14).

We conclude that managing a patient with penetrating head injury should be concise in order to minimize the chance of missing an existing or future complication of such injuries and to reduce the mortality and morbidity of patients. Early presentation to a medical center is necessary. Performing a brain CT scan can help in the diagnosis and management of complications.

## Conflict of interest

No conflict of interest was declared by the authors.

## References

1. Peek-Asa C, McArthur D, Hovda D, Kraus J. Early predictors of mortality in penetrating compared with closed brain injury. *Brain Inj* 2001; 15: 801-10. [\[CrossRef\]](#)
2. Kawamura S, Hadeishi H, Sasaguchi N, Suzuki A, Yasui N. Penetrating head injury caused by chopstick--case report. *Neurol Med Chir (Tokyo)* 1997; 37: 332-5. [\[CrossRef\]](#)
3. Karim T, Topno M. An unusual case of penetrating head injury in a child. *Emerg Trauma Shock* 2010; 3: 197-198. [\[CrossRef\]](#)
4. Bhootra BL, Bhana BD. An unusual missile-type head injury caused by a stone: case report and medicolegal perspectives. *Am J Forensic Med Pathol* 2004; 25: 355-7. [\[CrossRef\]](#)
5. Ishikawa E, Meguro K, Yanaka K, Murakami T, Narushima K, Aoki T, et al. Intracerebellar penetrating injury and abscess due to a wooden foreign body--case report. *Neurol Med Chir (Tokyo)* 2000; 40: 458-62. [\[CrossRef\]](#)
6. Liu WK, Ma L, Mao BY. A delayed frontorbital abscess caused by a penetrating nonmissile foreign body (A bamboo stick). *Neurol India* 2009; 57: 208-10. [\[CrossRef\]](#)
7. Takinami K, Hasegawa T, Miyamori T, Matumoto T, Arakawa Y, Sugino M. Intracerebral pneumocephalus following a head injury: case report. *No Shinkei Geka* 2003; 31: 425-9.
8. Tokitsu M, Nakamura M, Yokoyama H, Watanabe H, Hara M, Takeuchi K. Skullbase-penetrating injuries caused by umbrella tips: case reports. *No Shinkei Geka* 1990; 18: 189-92.
9. Hagan RE. Early complications following penetrating wounds of the brain. *J Neurosurg* 1971; 34: 132-41. [\[CrossRef\]](#)
10. Detorakis ET, Drositis I, Drakonaki EE, Panayotaki E, Deville JG. Pneumocephalus and presumed meningitis following inconspicuous penetrating periocular trauma. *Acta Ophthalmol Scand* 2004; 82: 603-5 [\[CrossRef\]](#)
11. Kuncz A, Roos A, Lujber L, Haas D, Al Refai M. Traumatic prepontine tension pneumocephalus--case report. *Ideggyogy Sz* 2004; 57: 313-5.
12. Domingo Z, Peter JC, de Villiers JC. Low-velocity penetrating craniocerebral injury in childhood. *Pediatr Neurosurg* 1994; 21: 45-9 [\[CrossRef\]](#)
13. Carpenter J, Stapleton S, Holliman R. Retrospective analysis of 49 cases of brain abscess and review of the literature. *Eur J Clin Microbiol Infect Dis* 2007; 26: 1-11. [\[CrossRef\]](#)
14. Schirmer CM, Heilman CB, Bhardwaj A. Pneumocephalus: case illustrations and review. *Neurocrit Care* 2010; 13: 152-8. [\[CrossRef\]](#)