

To cite this article: Tumer NB, Kunt AT, Gunertem OE, Babaroglu S, Budak AB, Karahasanoglu O, Gunaydin S, Ozisik K. Treatment for venous aneurysm: A salvage technique of AVF with an early cannulation prosthetic graft. Turk J Clin Lab 2019; 1: 74-78.

■ Original Article

Treatment for venous aneurysm: A salvage technique of AVF with an early cannulation prosthetic graft

Venöz anevrizma tedavisi: Erken kanüle edilebilen prostetik grefti ile AVF kurtarma tekniği

Naim Boran TUMER¹ , Atike Tekeli KUNT¹ , Orhan Eren GUNERTEM¹ , Seyhan BABAROĞLU² , Ali Baran BUDAK¹ , Onur KARAHASAOĞLU³ , Serdar GUNAYDIN¹ , Kanat OZISIK¹ 

¹University of Health Sciences, Ankara Numune Training and Research Hospital, Department of Cardiovascular Surgery, Ankara/TURKEY

²29 Mayıs Hospital, Department of Cardiovascular Surgery, Ankara/TURKEY

³University of Health Sciences, Türkiye Yüksek İhtisas Training and Research Hospital, Department of Cardiovascular Surgery, Ankara/TURKEY

ABSTRACT

Aim: A Venous aneurysm (VA) is one of the complications of arteriovenous fistulas (AVF) and may lead to rupture and potentially fatal bleeding. VA formation in AVF is mostly seen in the upper arm.

Material and Methods: Between January 2018 and December 2018, a total of 12 VA patients underwent surgery to end-to-end anastomosis using a vascular graft.

Results: Eight of the patients (66%) were males, and the mean age was 43.1 years (range 25-69 years). All of the fistulas were in the upper arm; two were basilic transpositions, and 10 were brachiocephalic AVF. Mean VA diameter was 4,7 cm (range 3-7 cm). All patients cannulated successfully within 24-48 hours from the newly placed AV access.

Conclusions: The procedure we described in this series is a successful and effective method for the treatment of VA in AVF. Postoperatively, most of the patients discharged early, and the VA site could be used for HD in 24-48 hours.

Keywords: early cannulation; vascular graft; arteriovenous fistula; venous aneurysm

Correspondence Author*: Naim Boran TUMER, University of Health Sciences, Ankara Numune Training and Research Hospital, Department of Cardiovascular Surgery, Ankara/TURKEY

E-mail: naimborantumer@hotmail.com

ORCID: 0000-0002-4775-2053

Received: 08.01.2019 accepted: 31.01.2019

Doi: 10.18663/tjcl.509859

ÖZ

Amaç: Venöz anevrizma (VA), rüptür ve ölümcül kanamalara da sebep olabilen arteriyovenöz fistüllerin sık görülen komplikasyonudur. AVF' de venöz anevrizma çoğu üst ekstremitede de görülür.

Gereç ve Yöntemler: Ocak 2018 ile Aralık 2018 tarihleri arasında toplam 12 venöz anevrizma hastasına vasküler greft kullanılarak end-to-end anastomoz yapılmıştır.

Bulgular: Hastaların 8 (%66) tanesi erkekti. Ortalama yaş 43.1 yaşdı.(25-69 yaş aralığı). Tüm fistüller üst ekstremitede yer alıyordu, 2 tanesi bazilik ven transpozisyonu ve 10 tanesi brakioyosefalik arteriyovenöz fistüldü. Venöz anevrizma ortalama çapı 4.7cm (3-7cm aralığı) tespit edildi. Tüm hastalarda kullanılan vasküler greft ilk 24-48 saat içinde başarılı bir şekilde AV giriş için kullanıldı.

Tartışma: Bu seride anlattığımız prosedür, AVF' de sık görülen venöz anevrizma komplikasyonunun çözümü için başarılı ve etkin bir yöntemdir. Postoperatif dönemde hastaların erken taburcu edilebilmesi ve VA bölgesindeki greftin 24-48 saat içinde hemodiyaliz için kullanılabilir olması işlemin avantajı olarak görülmüştür.

Anahtar kelimeler: erken kanülasyon; vasküler greft; arteriyovenöz fistül; venöz anevrizma

Introduction

Arteriovenous fistula (AVF) is now widely accepted as the vascular access in patients undergoing HD (Hemodialysis) due to its low complication and high patency rate. Although superior to grafts and catheters, venous aneurysm (VA), one of the significant difficulties of AVF, can cause rupture and even fatal bleeding. VA formation in AVF is mostly seen in the upper arm [1].

The most often cause of VA formation is repeated punctures at the vascular access sites. This repeated injury results in weakening of the vascular wall and consequently a VA formation [2]. The other mechanism that causes VA formation is proximal stenosis raising the pressure in the AVF. Expansion and rupture of the VA are the main complications, and this expansion can lead to skin atrophy and ulceration that may result in infection and rupture of the aneurysmatic vein. VA can also severely reduce the patient's quality of life. Ligation is the best treatment option for VA of the AVF and creation of a new access site. Salvage is possible by resection of the VA followed by end-to-end anastomosis, thus in such patients bypass needed [3]. Experience has shown that bypass using a prosthetic material is reliable [4] and early cannulation from the new access site is successful.

Material and Methods

Twelve patients included in the study who underwent VA resection between January 2018 and December 2018 at Ankara Numune and Research Hospital. Data were retrieved

from our hospital medical record system.

All 12 patients underwent a preoperative colour Doppler ultrasound examination to determine aneurysm diameter, detect intraluminal thrombus, identify stenosis, measure flow through the AVF, and assess the central outflow. Sedation and local anaesthesia used for the procedure (Figure 1). No heparin given during surgery and antibiotics were not used. A longitudinal incision was performed on the VA (Figure 2). VA was completely skeletonised using this incision (Figure 3). Vascular clamps used to control the proximal and distal portion of the AVF. Then the VA was circumferentially dissected, and a large amount of organised thrombus material was removed, and the aneurysm sac was resected. End-to-end anastomosis performed between the proximal and distal portion of the AVF with 6 mm of Acuseal® Vascular Graft (Gore Ltd, Flagstaff, AZ) (Figure 4). This vascular graft is a multi-layer vascular graft which includes an elastomer membrane between the inner and outer layers of expanded polytetrafluoroethylene (ePTFE). The lumen of the Acuseal vascular graft incorporates the CBAS Heparin Surface which imparts thromboresistant properties to the vascular graft. After placing the vascular graft the excess skin over the AVF resected and hemostasis achieved. HD was successfully performed on patients with interpositional Acuseal vascular graft the following day. These patients did not require preoperative placement of a tunnelled HD catheter. Local ethics committee approved the study and informed consent was obtained from participant(s)

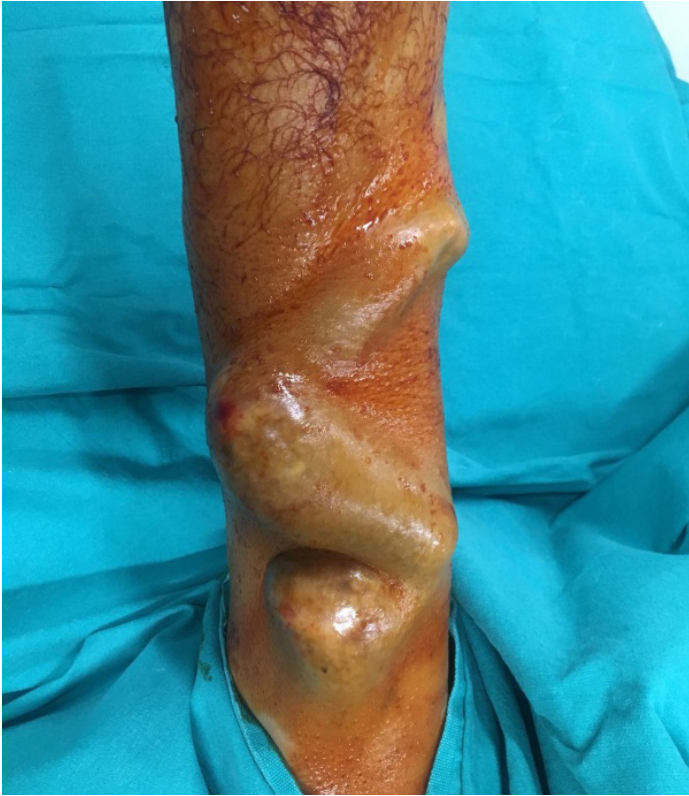

Figure 1. Preoperative massive aneurysmal arteriovenous fistula (AVF).

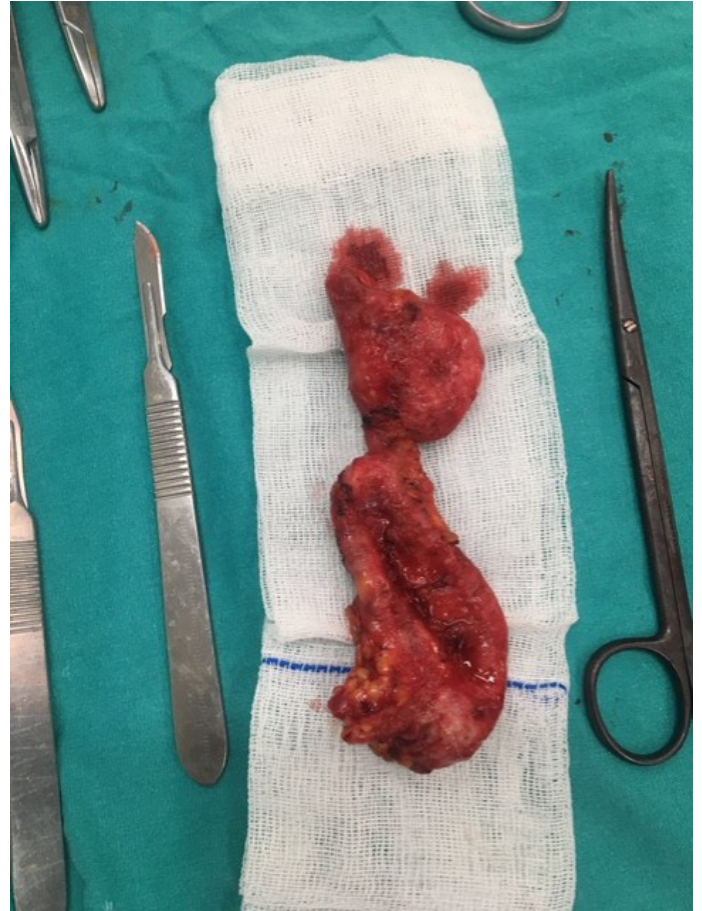

Figure 3. Circumferential dissection of a venous aneurysm (VA).

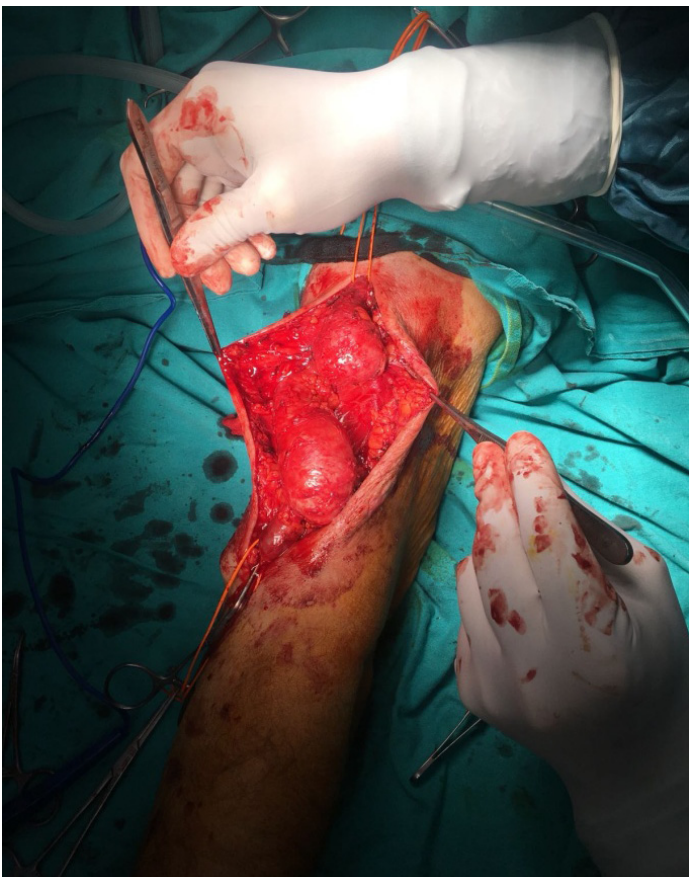


Figure 2. Intraoperative venous aneurysm.

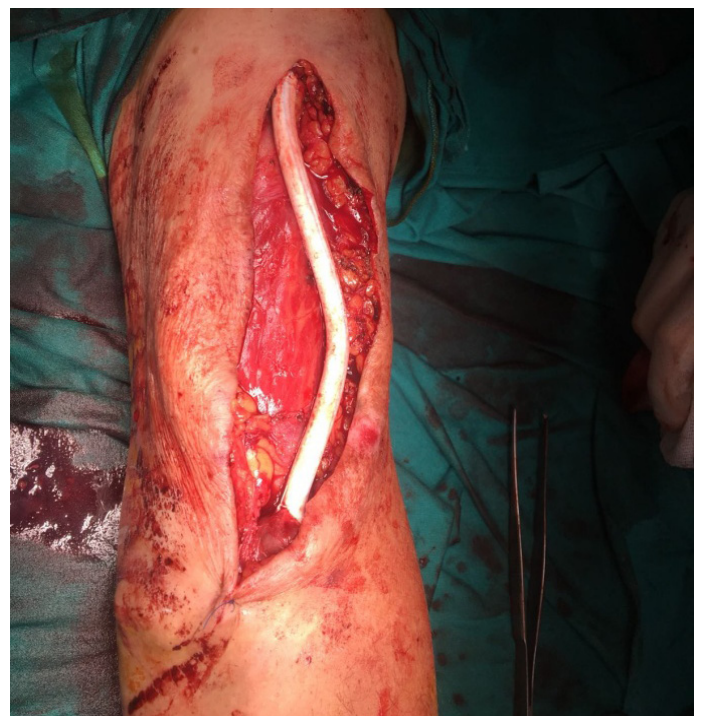

Figure 4. End-to-end anastomosis was performed between the proximal and distal portion of the AVF with 6 mm of Acuseal vascular graft.



Results

A total of 12 patients underwent this procedure within one year. Eight of the patients (66%) were males, and mean age was 43.1 years (range 25-69 years). In 6 patients (50%) the indication for operation was skin necrosis and erosion with imminent danger of bleeding, stenosis related to an aneurysm in two (16%) and difficulty with needle cannulation in four (33%).

All patients discharged on day two. The average operative duration was 65 minutes, and there was only one complication after surgery which was wound bleeding and stopped with adrenaline packing.

All of the fistulas were in the upper arm; two were basilic transpositions, and 10 were brachiocephalic AVF's. Mean VA diameter was 4.7 cm (range 3-7 cm). All patients were able to enter HD within 24-48 hours — no postoperative complications seen such as infection, hematoma, lymphatic leak, or skin flap necrosis. There was no 30-day mortality. In two of the patient, there were swelling on the forearm, but the flow of AVF was normal two months after the surgery. Colour Doppler ultrasound revealed a stenosis segment of the axillary vein in one patient and the patient treated with percutaneous transluminal angioplasty. No vascular complications were seen during the follow-up period and all patients with functional AVF.

Discussion

VA, may disrupt the function of AVF, may limit vascular access sites for HD and can result in rupture and massive bleeding. Unfortunately, most of our patients have been cannulated for dialysis from the VA segments. This is because of the dialysis staff awareness or carelessness or insufficient vascular access sites along the AVF, or both. [5]. The incidence of rupture after vascular access is 0.8% to 5.2% [6,7]. The primary goal of VA treatment is to remove the VA segment with the weakened vascular wall and to preserve the AVF functionality. It is known that the aneurysm continues to expand from this weak vessel wall segments and increases the risk of rupture during HD cannulation. Also in time, makes it difficult to find a proper and safe cannulation site. In tortuous and aneurysmal AVF, thrombus formation is typical and can affect the flow during HD.

Several techniques for treatment like the surgical or endovascular treatment of VA have been described in the literature. In the surgical procedure, VA resection or ligation can be performed and after a new AVF can be created [8]. One of the salvage techniques is aneurysmorrhaphy and

external porous polyethylene terephthalate (PET) prosthesis. This method also could prevent possible new aneurysms at access site [9,10]. Ligation or resection of the VA and creation of a new AVF in another location is undesirable for patients because until the newly created avf becomes available for cannulation the patients will require a temporary vascular access catheter insertion. Catheters also have their problems and complications, and it is uncomfortable for the patients.

Other surgical options include vascular grafting after ligation and resection. Although the patency rate of the prosthetic graft we use is satisfactory, its superiority over PTFE grafts in the long term is not clear. It is reported that the Acuseal grafts have shown almost the same patency comparable to conventional PTFE grafts used for AVF. These grafts low bleeding rates and contains elastomeric middle membrane between the inner and outer layers of PTFE [11]. Covalently bonded heparin coated luminal surface provides the maintenance of bioactivity and gives thromboresistant properties to the graft [12]. The most significant advantages compared to other standard grafts are that the patients can be cannulated for HD almost immediately after surgery, and patients do not need central venous catheterisation. Finally, this surgical approach should be considered for treatment of VA and rescue of AVF.

The procedure that we have described in this series is a novel and highly successful approach to the problem of diffuse VA change in AVF for dialysis. Postoperatively, most of the patients were discharged early, and the VA site could be used for HD.

Declaration of conflict of interest

The authors received no financial support for the research and/or authorship of this article. There is no conflict of interest.

References:

1. Salahi H, Fazelzadeh A, Mehdizadeh A, Razmkon A, Malek-Hosseini SA. Complications of arteriovenous fistula in dialysis patients. *Transplant Proc* 2006; 38: 1261-64.
2. Jürg Schmidli et al. *Vascular Access: 2018 Clinical Practice Guidelines of the European Society for Vascular Surgery (ESVS)*. *Eur J Vasc Endovasc Surg* 2018; 55: 757-818
3. Management of aneurysms: Vascular Access Society guidelines, <http://www.vascularaccessociety.com>; October 30, 2009.
4. Huber TS, Carter JW, Carter RL, Seeger JM. Patency of autogenous and polytetrafluoroethylene upper extremity arteriovenous HD accesses a systematic review. *J Vasc Surg* 2003; 38: 1005-11.

5. Gilmore J. KDOQI Clinical Practice Guidelines and Clinical Practice Recommendations for 2006 Updates: HD adequacy, peritoneal dialysis adequacy, and vascular access. *Am J Kidney Dis* 2006; 48: 1-322.
6. Haimov M, Baez A, Neff M, Slifkin R. Complications of arteriovenous fistulas for HD. *Arch Surg* 1975; 110: 708-12.
7. Zibari GB, Rohr MS, Landreneau MD et al. Complications from permanent HD vascular access. *Surgery* 1988; 104: 681-86.
8. Woo K, Cook PR, Garg J, Hye RJ, Canty TG. Midterm results of a novel technique to salvage autogenous dialysis access in aneurysmal arteriovenous fistulas. *J Vasc Surg* 2010; 51: 921-25.
9. Dedow E, Kaduk M. The Biocompound Shunt as a method of treatment of a.v. fistula aneurysm-a critical assessment. *Zentralbl Chir* 2006; 131: 42-44.
10. Balaz P, Rokosny S, Klein D, Adamec M. Aneurysmorrhaphy is an easy technique for arteriovenous fistula salvage. *J Vasc Access* 2008; 9: 81-84.
11. Maytham GG, Sran HK, Chemla ES. The use of the early cannulation prosthetic graft (Acuseal™) for angioaccess for HD. *J Vasc Access* 2015; 16: 467-61.
12. Chiang N, Hulme KR, Haggart PC, Vasudevan T. Comparison of FLIXENE™ and standard PTFE arteriovenous graft for early HD. *J Vasc Access* 2014; 15: 116-22.