









To cite this article: Kunt AT, Daglar G, Babaroglu S, Tumer NB, Gunertem OE, Budak AB, Ozisik K, Gunaydin S. Surgical management of "forgotten" goiter in a patient with the history of coronary artery bypass grafting.. Turk J Clin Lab 2019; 1: 117-119.

## ■ Case Report

# Surgical management of "forgotten" goiter in a patient with the history of coronary artery bypass grafting.

## *Koroner arter bypass greftleme öyküsü olan bir hastada "gizli" guatrın cerrahi tedavisi*

Atike Tekeli KUNT<sup>1</sup> , Gul DAGLAR<sup>2</sup> , Seyhan BABAROGLU<sup>1</sup> , Naim Boran TUMER<sup>1</sup> ,  
Orhan Eren GUNERTEM<sup>1</sup> , Ali Baran BUDAK<sup>1</sup> , Kanat OZISIK<sup>1</sup> , Serdar GUNAYDIN<sup>1</sup> 

<sup>1</sup>University of Health Sciences, Ankara Numune Training and Research Hospital, Department of Cardiovascular Surgery, Ankara/TURKEY

<sup>2</sup>University of Health Sciences, Ankara Numune Training and Research Hospital, Department of General Surgery, Ankara/TURKEY

### ABSTRACT

Forgotten goiter is a rare condition and it is surgically managed through cervical approach in most cases. Extracervical management could be necessary in rare cases. We report a case of a forgotten goiter managed with thyroidectomy through a mini-re sternotomy combined with a transcervical approach as the patient underwent previous cardiac surgery.

**Keywords:** retrosternal guatr, resternotomy, minimal invasive surgery

### ÖZ

Gizli guatr nadir karşılaşılan bir durum olmasına rağmen servikal bölgeye yapılan kesilerle cerrahi olarak tedavi edilebilmektedir. Ekstraservikal yaklaşım istisnai durumlarda başvurulan bir yöntemdir. Biz bu olgu sunumunda daha önce kardiyak cerrahi geçirmiş, gizli guatrı olan bir hastada tiroidektomi için transservikal yaklaşım ile mini-sternotomiyi nasıl kombine ettiğimizi anlatmak istedik.

**Anahtar Kelimeler:** retrosternal guatr, resternotomi, minimal invazif cerrahi

Sorumlu Yazar<sup>2</sup>: Atike Tekeli Kunt, University of Health Sciences, Ankara Numune Training and Research Hospital, Department of Cardiovascular Surgery, Ankara/TURKEY

E-mail: atikemd@gmail.com

ORCID: 0000-0001-9764-7393

Received: 07.05.2018 accepted: 08.06.2018

Doi: 10.18663/tjcl.421573

## Introduction

Retrosternal goiter was described for the first time in 1749 by Haller [1]. Massard et al, in 1992, first described the term “forgotten goiter” that means a mediastinal mass diagnosed after a cervical total thyroidectomy [2]. Forgotten goiter is a rare condition with an incidence of 2%-16% [3]. The main reasons for this issue to occur are; incomplete removal of a cervico-mediastinal goiter during initial cervical thyroidectomy or an undiagnosed mediastinal goiter which has no connection to the cervical mass [4]. Surgical management in forgotten goiter varies from patient to patient however in most cases cervical approach is sufficient for the removal of the retrosternal goiter [5]. In the literature, the requirement of extracervical approach is suggested to be 2%-11%, either through sternotomy for anterior mediastinal mass or through thoracotomy for posteriorly located masses [5].

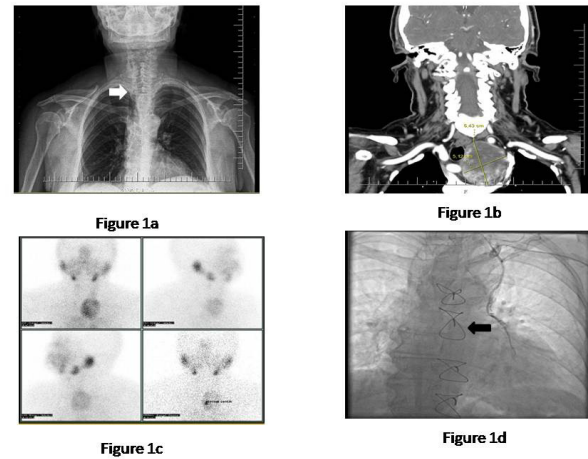
Herein, we report a case of a patient managed with thyroidectomy through a mini-re sternotomy combined with a transcervical approach since she had a past history of cervical total thyroidectomy 20 years ago and a coronary artery bypass graft operation 3 years ago.

## Case

A 67-year-old female patient with a past medical history of total cervical thyroidectomy for multinodular goiter was admitted to endocrine surgery department with mild dyspnea. In her previous thyroidectomy, the surgeon reported that a total cervical thyroidectomy was carried on without any complication. She was on levothyroxine sodium treatment since her initial operation that was 20 years ago. Additionally, the patient underwent a coronary artery bypass graft surgery for left anterior descending artery (LAD) lesion through a median sternotomy and a left internal thoracic artery (LITA) to LAD anastomosis was performed 3 years ago.

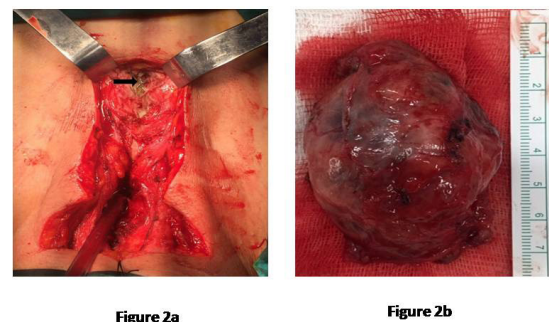
Her physical examination on her admission to endocrine surgery department was normal and there was no palpable cervical thyroid. She was euthyroid with normal serum levels of Free T4 and TSH (1.38 ng/dl (0.87-1.7 ng/dl) and 0.646  $\mu$ U/ml (0.27-4.2  $\mu$ U/ml) respectively). Her chest X-ray revealed a significant deviation of the trachea to the right side (Figure 1a). Computed tomography of neck and chest revealed a mass with a diameter of 64x51mm located on superior mediastinum leading to a rightward deviation of both trachea and left carotid artery and compressing both left internal jugular and brachiocephalic veins (Figure 1b). Thyroid scintigraphy demonstrated hyperplasia of the left thyroid lobe and a nodule that was located retrosternally showing a heterogenous activity (Figure 1c). As the patient had a history of CABG and a “forgotten” goiter, endocrine surgeons consulted us, as cardiovascular

surgeons, for requirement of a sternotomy. Her coronary angiography revealed a patent LITA-LAD anastomosis (Figure 1d).



**Figure 1:** **1a;** preoperative chest X-ray, white arrow showing the tracheal deviation. **1b;** preoperative computed tomography of the patient showing the retrosternal goiter that deviated trachea to the right. **1c;** thyroid scintigraphy. **1d;** coronary angiography, black arrow showing the patent LITA-LAD anastomosis.

Initially, the patient underwent a transcervical approach for the removal of the mass. Thyroid gland with a diameter of 1x1cm was explored and removed. A neural integrity monitor (NIM) was used during the procedure to identify the left recurrent laryngeal nerve. Due to the patient’s previous CABG surgery we thought that there could be massive fibrous adhesions around the mediastinal mass that may lead to an uncontrollable bleeding when trying to deliver the mass through the cervical incision, and decided to perform a mini resternotomy (Figure 2a). The nodule was removed with its capsule successfully without a vascular complication (Figure 2b). The patient’s recovery was uneventful and discharged on 3rd postoperative day.



**Figure 2:** **2a;** mini resternotomy combined with cervical incision, black arrow showing sternal wires, **2b;** thyroid gland.

Local ethics committee approved the study and informed consent was obtained from participant(s)

## Discussion

Retrosternal goiter is the extension of thyroid gland in the me-



diastinum. It is called primary when there is an ectopic thyroid gland in the mediastinum that is fed by mediastinal vessels and it is called secondary when the cervical thyroid gland extends to the mediastinum either posteriorly or anteriorly and fed by neck vessels. Forgotten goiter is a condition that defines a mediastinal mass diagnosed after a total cervical thyroidectomy [2]. Most forgotten goiters are asymptomatic and diagnosed incidentally [5]. Surgery is indicated whether the goiter is symptomatic or not. Complete delivery of "forgotten" goiter through a standard cervical approach is mostly sufficient. However, extracervical approach either sternotomy or thoracotomy could be required in rare cases. Recently, video-assisted thoracoscopic surgery (VATS) and the da Vinci robotic surgery approaches are started to use in retrosternal goiters to avoid the complications of thoracotomy or sternotomy. These minimal invasive approaches lead to shorter hospital stays, reduced pain and also better cosmetic results, however these are expensive systems [5].

We performed standard cervical incision combined with a mini re-sternotomy in this case to avoid troublesome bleeding, injury to recurrent laryngeal nerve and also to avoid incomplete removal of the mediastinal mass. In the literature, there are cases that report standard cervical incision combined with a sternotomy for retrosternal goiters. What makes the things complex and interesting in our case is that the patient underwent a CABG operation 3 years ago through a median sternotomy and resternotomy was necessary. To the best of our knowledge this case is the first case report that required resternotomy for a forgotten goiter excision.

## Conclusion

Surgical resection of forgotten goiter even asymptomatic is the gold standard. Sternotomy combined with transcervical approach is necessary in rare cases. We conclude that even resternotomy can be performed safely in retrosternal goiters who underwent a median sternotomy for a cardiac surgery.

## Declaration of conflict of interest

The authors received no financial support for the research and/or authorship of this article. There is no conflict of interest.

## References

1. Haller A. *Disputationes Anatomica Selectae*. Gottingen: Vandenhoeck 1749: 96.
2. Massard G, Wihlm JM, Jeung MY, Roeslin N, Dumont P, Witz JP. Forgotten mediastinal goiter: seven cases. *Ann Chir* 1992; 46: 770–73.
3. Calò PG, Tatti A, Medas F, Petruzzo P, Pisano G, Nicolosi A. Forgotten goiter. Our experience and a review of the literature. *Ann Ital Chir* 2012; 83: 487-90.
4. Riquet M, Deneuille M, Debesse B, Chretien J. Autonomous intrathoracic goiter: apropos of 2 new cases, *Rev Pneumol Clin* 1986; 42: 267–73.
5. Tsilimigras DI, Patrini D, Antonopoulou A, Velissaris D, Koletsis E, Lawrence D, et al. Retrosternal goitre: the role of the thoracic surgeon. *J Thorac Dis* 2017; 9: 860-63.