

Twin Reversed Arterial Perfusion (TRAP) Sequence

TRAP (Twin Reversed Arterial Perfusion) Sekansı

Ayşe Seçil EKŞİOĞLU¹, Aylin ÖZGÜN², Saliha ŞENEL³

¹ Dr. Sami Ulus Obstetrics, Children's Health and Diseases Training and Research Hospital, Department of Radiology, Ankara, Turkey

² Dr. Zekai Tahir Burak Maternity Hospital, Department of Radiology, Ankara, Turkey

³ Dr. Sami Ulus Obstetrics, Children's Health and Diseases Training and Research Hospital, Department of Pediatrics Ankara, Turkey

ABSTRACT

The TRAP sequence is a rare anomaly seen in 0.3-1% of all monochorionic twin gestations. One of the twins is acardiac and acts like a parasite. The normal co-twin pumps blood for the other through abnormal vascular communications in the placenta. It is lethal for the acardiac fetus and also poses a high risk of morbidity and mortality for the 'pump' fetus secondary to anemia, high-output cardiac failure and prematurity. The sonographic prenatal diagnosis is important for proper management. This case has been presented to remind that the TRAP sequence is a rare and serious anomaly and to emphasize the importance of ultrasonographic examination as a simple but adequate tool in the diagnosis, follow-up, and even in the treatment of such a case.

Key Words: Acardiac twin, TRAP sequence, Ultrasonography

ÖZET

TRAP sekansı tüm monokoryonik ikiz gebeliklerin %0,3-1'inde görülen nadir bir anomalidir. İkizlerden biri akardiyaktır ve parazit gibi davranır. Normal olan ikiz eşi plasentadaki anormal vasküler iletişimlerle diğerine kan pompalar. Bu akardiyak fetus için ölümcül bir durumdur ve pompacı fetus için de anemi, yüksek debili kalp yetmezliği ve prematürite açısından yüksek risk oluşturur. Uygun yaklaşım açısından prenatal ultrasonografik inceleme önemlidir. Burada, TRAP sekansının nadir ve ciddi bir anomali olduğunu hatırlatmak ve ultrasonografik incelemenin basit ama tanı, takip ve hatta tedavide kullanışlı bir yöntem olduğunu vurgulamak için bu vaka sunulmuştur.

Anahtar Sözcükler: Akardiyak ikiz, TRAP sekansı, Ultrasonografi

INTRODUCTION

The twin reversed arterial perfusion (TRAP) sequence is a rare and serious anomaly that occurs in 1/35000 of all pregnancies or %0.3-1 of all monozygotic twin gestations (1,2). No well-defined cardiac structure has been identified in one twin (acardiac) which acts as a parasite that is hemodynamically dependent on the other (normal or pump) twin. Here, we have presented a twin pregnancy with TRAP sequence to remind this rare and serious anomaly.

CASE REPORT

A 27-year-old woman, gravida 1, para 0, was referred to the radiology department for a second-trimester anomaly scan.

Ultrasound (US) revealed a monochorionic, monoamniotic twin gestation with one normal appearing fetus of gestational age 18-19 weeks. The second fetus had an abdominal stump without any intraabdominal organs and a partly developed spinal cord but no head, upper extremities, thoracic structures, or heart. Massive, diffuse soft tissue edema consistent with lymphedema and a large dorsal cystic hygroma were determined (Figure 1). Hypoplastic lower extremities and polyhydramnios were also detected (Figure 2). The Doppler US examination showed reversed blood flow in the single umbilical artery of the abnormal fetus. This appearance was typical of a TRAP sequence with an acardiac parabiotic twin. The pump twin had no obvious congenital anomalies.

The family preferred close follow-up and did not accept any intervention. The patient was followed-up with serial US examinations. She went into premature labor secondary to

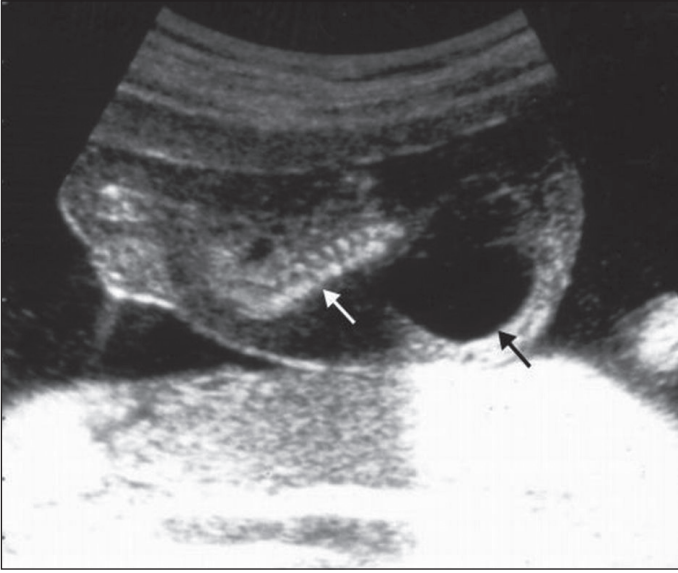


Figure 1: Prenatal midsagittal US image shows incompletely formed spinal cord (white arrow), increased subcutaneous tissue thickness secondary to lymphedema and an accompanying large cystic hygroma (black arrow). Note the absence of any identifiable abdominal organs, heart, head or upper extremities.

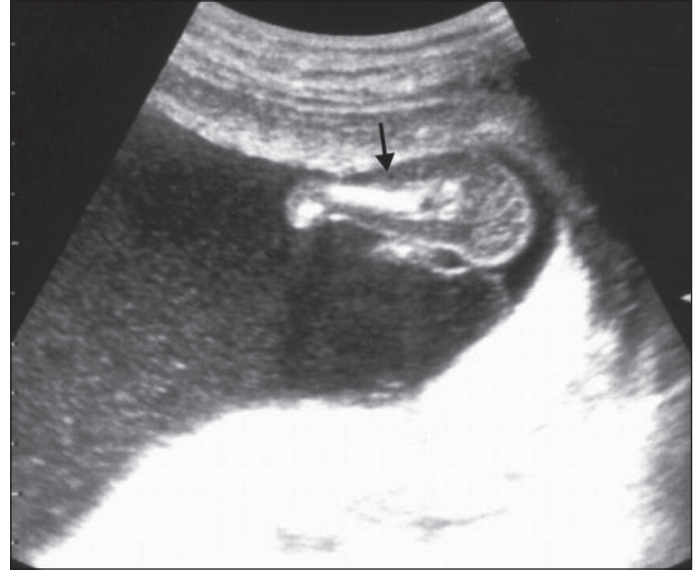


Figure 2: Prenatal US image through the level of the hypoplastic left lower extremity (arrow). Polyhydramnios with internal echoes is present.

polyhydramnios at the 24th week and delivered an amorphous mass and a normal-appearing fetus which, however, died on the second day because of respiratory insufficiency due to prematurity. No malformations were detected in the pump fetus after the delivery and chromosomal analysis was found to be normal in this fetus. The family did not give consent for autopsy.

DISCUSSION

The recipient twin has a single umbilical artery as in our case in 75% of TRAP sequences. Poorly oxygenated umbilical arterial blood from the donor flows into the single umbilical artery of the recipient in reversed direction, resulting in a wide spectrum of gross malformations (3). Because the 'pump' twin heart has to pump for two, it has a high risk for development of anemia and high-output cardiac failure. This high cardiac output causes increased perfusion of the fetal kidneys resulting in overproduction of fetal urine and polyhydramnios.

Chromosomal anomalies are present in up to 50% of acardiac fetuses and 9% of pump twins. The acardiac twin usually has a dorsal cystic hygroma as determined in our case (3). The perinatal mortality of the healthy twin is about 50-70% due to polyhydramnios leading to premature delivery or congestive heart failure (1-3). Our case also resulted in labor at 24th week and eventual loss of the baby secondary to prematurity.

After excluding chromosomal anomalies and malformations in the pump fetus, close follow-up by US can be started. As

the ratio of the weight of the acardiac fetus to the weight of the donor fetus gets smaller, the prognosis gets better. A rough estimate of the acardiac fetus weight can be made by comparing the ratio of the abdominal perimeters of the twins. When the acardiac twin reaches a size more than half the size of the pump twin, the risk for congestive heart failure increases to 94% (4). In our case although any increase in acardiac fetus size or any sign of congestive heart failure was not detected by sonographic follow-up, preterm labor resulted in the loss of the normal fetus. Treatment for acardiac twin pregnancy is indicated when poor prognostic signs including increased mass of acardiac twin, polyhydramnios, hydrops or a difference of more than 0.20 between the resistive indices (RI) of the umbilical arteries of the twins are present (2,4). However the optimal management is controversial with options ranging from conservative management to elective termination or surgical intervention (4-6).

CONCLUSION

The twin reversed arterial perfusion (TRAP) sequence is a rare, serious anomaly and ultrasonographic evaluation is very important in the diagnosis, follow-up and timing of intervention or delivery of these cases.

REFERENCES

1. Bornstein E, Monteagudo A, Dong R, Schwartz N, Timor-Tritsch IE. Detection of twin reversed arterial perfusion sequence at the time of first- trimester screening: the added value of 3-dimensional volume and color Doppler sonography. *J Ultrasound Med* 2008;27: 1105-9.
2. Wong AE, Sepulveda W. Acardiac anomaly: current issues in prenatal assessment and treatment. *Prenat Diagn* 2005;25: 796-806.
3. Chandramouly M, Namitha. Case series: TRAP sequence. *Indian J Radiol Imaging* 2009;19:81-3.
4. Rohilla M, Chopra S, Suri V, Aggarwal N, Vermani N. Acardiac-acephalus twins: A report of 2 cases and review of literature. *Medscape J Med* 2008;10:200.
5. Malhotra N, Sinha A, Deka D, Roy KK. Twin reversed arterial perfusion: Report of four cases. *J Clin Ultrasound* 2004;32: 411-4.
6. Kaleliođlu İH, İyibozkurt AC, Delier YH, Topuz S, Çetin C, Has R. Conservative management of twin reversed arterial perfusion sequence (TRAP): Case Report. *Türkiye Klinikleri J Gynecol Obst* 2010;20:203-6.