

## A Case of Anhidrotic Ectodermal Dysplasia

### Ektodermal Displazili Bir Olgu

Cihangir AKGÜN<sup>1</sup>, Lokman ÜSTYOL<sup>1</sup>, Avni KAYA<sup>1</sup>, Sinan AKBAYRAM<sup>1</sup>, Süleyman ÖZEN<sup>2</sup>,  
Remzi ERTEN<sup>2</sup>, Fesih AKTAR<sup>1</sup>, Berfin ÖZGÖKÇE ÖZMEN<sup>1</sup>

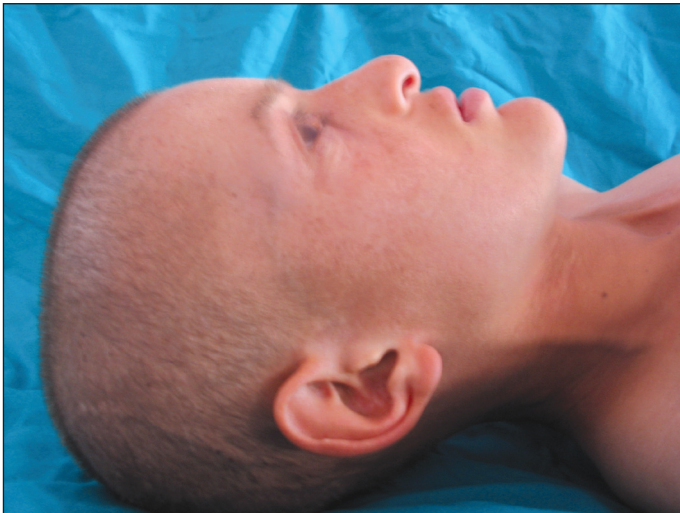<sup>1</sup> University of Yüzüncü Yıl, School of Medicine, Department of Pediatrics, Van, Turkey

<sup>2</sup> University of Yüzüncü Yıl, School of Medicine, Department of Pathology, Van, Turkey

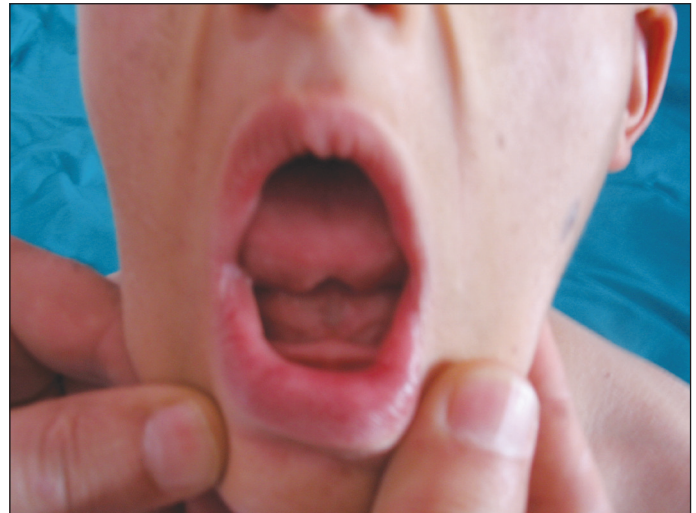Ectodermal dysplasia is a heterogeneous group of disorders characterized by a constellation of findings involving defects of 2 or more of the following: teeth, skin, and appendageal structures including hair, nails, and eccrine and sebaceous glands (1). The incidence of ectodermal dysplasia is estimated to be 0.7 to 1 per 100000 births (2). Anhidrotic (hypohidrotic) ectodermal dysplasia is manifested as a triad of defects: partial or complete absence of sweat glands, anomalous dentition, and hypotrichosis. Although rare autosomal dominant and recessive forms exist, this syndrome is a sex-linked recessive condition that manifests fully in affected males and partially in females (3). It is characterized by a small saddle-shaped nose, frontal bossing, prominent supraorbital ridges, maxillary hypoplasia, microstomia, prominent pouting lips, small conical (peg shaped) or missing teeth and dysplastic nails (4).

A 9-year-old boy was admitted to our hospital with a history of fever, cough and respiratory distress. He was the first child of consanguineous parents and he had five healthy siblings. His past history revealed that he was unable to sweat and he was referred many times to health centers because of fever of unknown origin.

On physical examination, his body measurements were as follows: weight was 20 kg (10th to 25th percentile), height 108 cm (10th to 25th percentile) and he had anodontia, frontal bossing, saddle nose, dry and finely wrinkled skin, thick everted lips and his scalp hair, eyebrows and lashes were sparse (Figure 1,2). Otolaryngologic and ophthalmologic examinations were normal. Auscultation of the lung revealed scattered crackles and slightly diminished breath sound. There was pneumonic infiltration on the chest radiograph. Laboratory



**Figure 1:** The typical face with frontal bossing, saddle nose, thick everted lips, sparse hair and eyebrows.



**Figure 2:** Congenital anodontia.

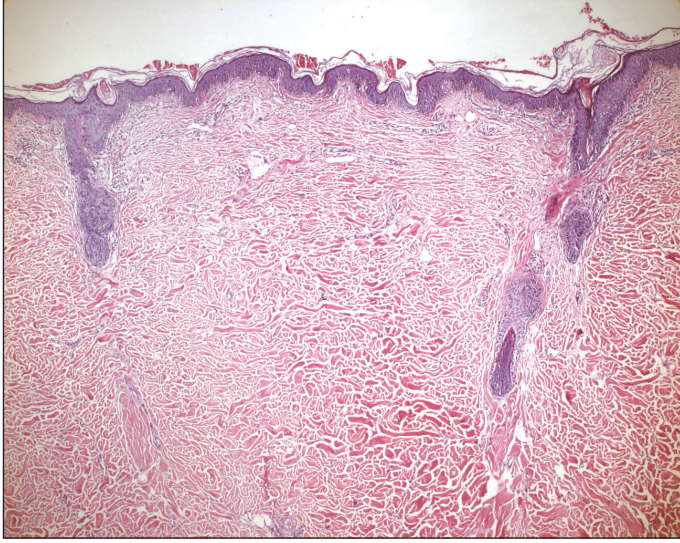
Correspondence Address / Yazışma Adresi:

**Avni KAYA**  
Yüzüncü Yıl Üniversitesi, Tıp Fakültesi, Çocuk Sağlığı ve Hastalıkları Anabilim Dalı, Van, Turkey  
E-mail: avnikaya@gmail.com

Received / Geliş tarihi : 22.07.2011

Accepted / Kabul tarihi : 03.08.2011

DOI: 10.12956/tjpd.2013.1.13



**Figure 3:** The absence of eccrine and sebaceous glands.

examinations revealed white blood cell count of  $15000/\text{mm}^3$ , C - reactive protein of 56 mg/dl and sedimentation rate of 60 mm per hour. Biochemical parameters and immunoglobulin levels were normal. Skin biopsy was performed and eccrine and sebaceous glands could not be seen (Figure 3). He was diagnosed as anhidrotic ectodermal dysplasia and pneumonia with all these physical examination findings and skin biopsy result. He was treated with ampicillin-sulbactam for pneumonia and discharged with suggestions for anhidrotic ectodermal dysplasia such as avoiding excessive physical exercises that can cause an increase in body temperature. He was referred to a dentist for cosmetic reasons. It is important to identify the components of the disorder so that appropriate treatment can be provided to ectodermal dysplasia patients. It is also important to understand the genetic hereditary patterns so that the parents of an affected child can be advised on the possibility of new cases in the family but unfortunately we did not have a chance to perform a genetic study of this patient.

## REFERENCES

1. Morelli JG. Ectodermal Dysplasias. In: Nelson Textbook of pediatrics. Kliegman RM, Behrman RE, Jenson HB, Stanton BF (eds.). Philadelphia, Saunders Elsevier, 2008; 2666-7.
2. Shin JJ, Hartnick CJ. Otologic Manifestations of ectodermal dysplasia. Arch Otolaryngol Head Neck Surg 2004;130:1104-7.
3. Sinha V, Sinha S. Anhidrotic ectodermal dysplasia presenting as atrophic rhinitis and maggots. Indian Pediatr 2003;40:1105-6.
4. Gordon CP, Litz S. Multicore myopathy in a patient with anhidrotic ectodermal dysplasia. Can J Anaesth 1992;39:966-8.