

Transient Isolated Right Ventricular Hypertrophy in a Neonate

Yenidoğan Döneminde Geçici İzole Sağ Ventrikül Hipertrofisi

Zehra KARATAŞ, Fatih ŞAP, Sevim KARAARSLAN, Hayrullah ALP, Hakan ALTIN, Tamer BAYSAL

Necmettin Erbakan University, Meram Faculty of Medicine, Department of Pediatric Cardiology, Konya, Turkey

This study is partly present as a poster in 10th National Pediatric Cardiology and Cardiovascular Surgery Congress in Gaziantep at 4-7 May 2011.



ABSTRACT

Transient hypertrophic cardiomyopathy is rarely seen in neonates. We have reported a term neonate with transient right ventricular hypertrophy, diagnosed with echocardiographic investigation on the third day of life and interestingly disappeared within 10 weeks without any specific treatment. Transient right ventricular hypertrophy has not attracted enough attention in the pediatric cardiology literature. It is well known that during pregnancy, maternal consumption of polyphenol-rich substances may cause fetal ductal constriction. In our case, this anomaly might be due to premature closure of ductus arteriosus. We have reported such a case because of the rarity of this anomaly and we wanted to attract attention about the nutrition of pregnant women.

Key Words: Ductus arteriosus, Hypertrophy, Newborn, Right ventricular

ÖZET

Yenidoğan döneminde geçici hipertrofik kardiyomiyopati nadir görülmektedir. Term olarak dünyaya gelen ve yaşamının üçüncü gününde yapılan ekokardiyografik inceleme ile sağ ventrikül hipertrofisi tespit edilen bir yenidoğan olgusu sunulmuştur. Rutin takiplerinde ilginç bir şekilde 10 hafta içinde hipertrofinin herhangi bir tedavi uygulanmadan kendiliğinden düzeldiği görüldü. Geçici sağ ventrikül hipertrofisi pediatrik kardiyoloji literatüründe yeterince yer almamıştır. Gebelik süresince polifenol içeriği yüksek besinlerin tüketiminin duktusun erken kapanmasına neden olduğu bilinmektedir. Olgumuzda görülen sağ ventrikül hipertrofisi duktus arteriozusun erken kapanmasına bağlı gelişmiş olabilir. Geçici sağ ventrikül hipertrofisi nadir görülmesi nedeniyle ve annelerin gebelik döneminde intrauterin duktusun erken kapanmasına neden olabilecek besinler yönünden dikkatli olunması gerektiğini vurgulamak amacıyla bu olgu sunulmuştur.

Anahtar Sözcükler: Duktus arteriozus, Hipertrofi, Yenidoğan, Sağ ventrikül

INTRODUCTION

Transient right ventricular hypertrophy (RVH) is a rare anomaly that is seen during the neonatal period (1-2). Metabolic diseases, maternal diabetes, non-steroidal anti-inflammatory drug (NSAID) treatment during pregnancy, and dexamethasone therapy in premature newborns for bronchopulmonary dysplasia may cause transient RVH in the newborn period (1-4). The peculiarity of our case is the complete echocardiographic regression of right ventricular hypertrophy and the lack of relationship between transient RVH and any secondary causes described above.

We have reported this case because of the rarity of transient RVH and we wanted to attract attention about the importance of pregnant nutrition.

CASE REPORT

A female neonate was born at 39 weeks gestation by cesarean section with general anesthesia because of perinatal distress. Maternal exposure to indomethacin or other NSAID medications and gestational diabetes were not noted during pregnancy. In addition, there was no family history of hypertrophic cardiomyopathy. Birth weight was 3300 g with high Apgar scores. Oxygen saturation as well as pulmonary and cardiac findings (except sinus tachycardia) were all normal. An electrocardiogram revealed sinus tachycardia and RVH. Chest radiogram was normal. Echocardiographic investigation which was performed on third day of life, showed severe RVH (wall thickness of 11 mm in diastole) with a small right ventricular cavity (1.85 cm² in diastole). Myocardial hypertrophy was seen at the anterior wall

Correspondence Address / Yazışma Adresi:

Zehra KARATAŞ
Selçuk Üniversitesi, Meram Tıp Fakültesi, Pediatrik Kardiyoloji Anabilim Dalı, Konya, Turkey
E-mail: zehrakaratas1975@hotmail.com

Received / Geliş tarihi : 29.09.2011
Accepted / Kabul tarihi : 24.10.2011
DOI: 10.12956/tjpd.2013.14

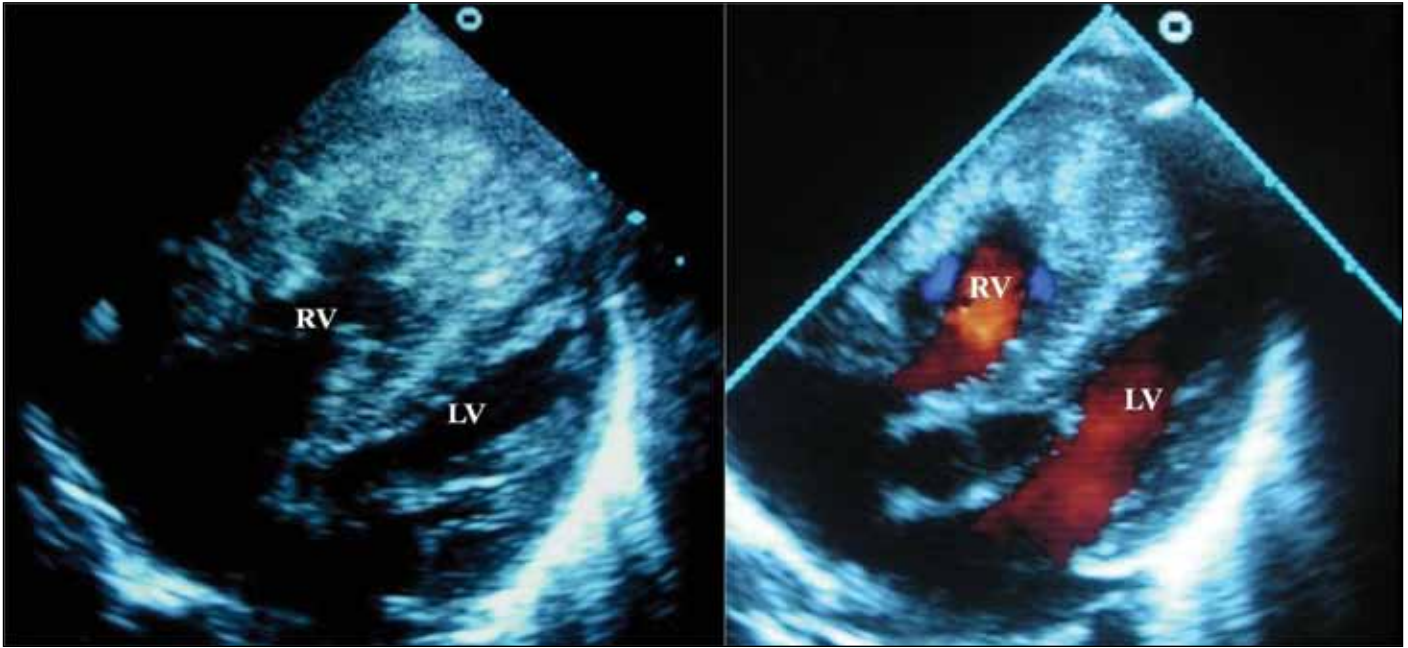


Figure 1: A subcostal four-chamber view on the third day of life revealed severe isolated RVH with reduced right ventricular cavity while the left ventricle was normal. **RV:** right ventricle, **LV:** left ventricle.

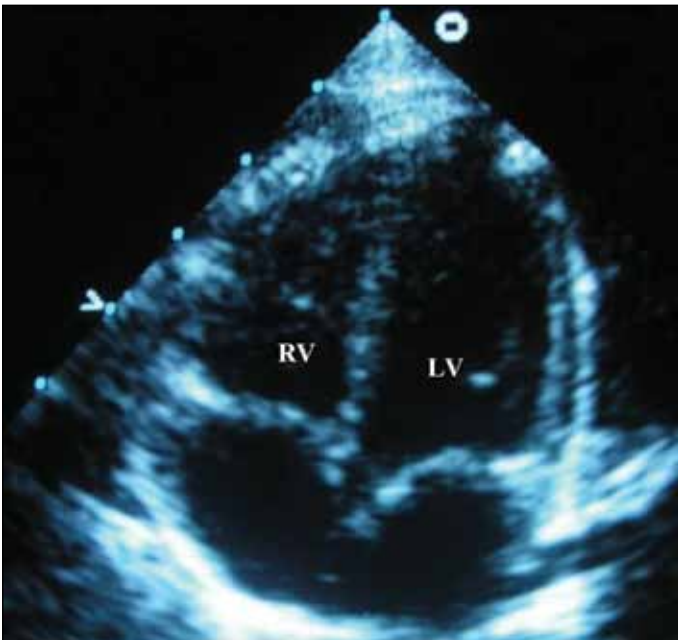


Figure 2: The comparable subcostal four-chamber view at ten weeks of life showed complete regression of the RVH. **RV:** right ventricle, **LV:** left ventricle.

and apex of the RV and also at right side of the interventricular septum (Figure 1). Color Doppler echocardiography revealed only mild tricuspid regurgitation with a normal right ventricular pressure (~25 mmHg). There was no blood flow through ductus arteriosus (DA), so it was diagnosed as closed. The remainder echocardiographic findings were all normal. Complete regression of the right ventricular hypertrophy and normalization of the

right ventricular cavity were demonstrated on the tenth week after birth (Figure 2).

DISCUSSION

Some congenital heart anomalies, such as pulmonary stenosis, tetralogy of Fallot or truncus arteriosus, may cause RVH. Echocardiographic examination was normal for these anomalies in our infant. Other causes of RVH include metabolic and hereditary disease, maternal diabetes and premature closure of DA (1,2,4-7). Also, we could not explain RVH with metabolic or hereditary disease because of the transient nature of RVH and the lack of familial history about metabolic and hereditary diseases. It is well known that maternal diabetes mellitus may cause transient RVH, but blood sugar analyses were within normal ranges during her pregnancy. Transient RVH in neonates may result from remodeling of pulmonary vasculature secondary to acute perinatal distress (8). Our case was also born with cesarean section because of perinatal distress. The reason of idiopathic or spontaneous intrauterine closure of the DA is not known exactly (9,10). Intrauterine closure of the human DA has been reported following maternal administration of the prostaglandin synthetase inhibitors such as aspirin, glucocorticoids and NSAIDs (5,11-14). There was no history of such medications during pregnancy in our case.

On the third day echocardiographic examination, DA was diagnosed as closed in our patient. We really do not know whether the closure of DA was in utero or after birth. Recently, clinical and experimental evidence showed that maternal consumption of polyphenol-rich substances (PRFs), such as

herbal teas, orange and grape juice, chocolate, and others, may interfere with fetal DA dynamics and may cause fetal ductal constriction (15,16). Also, we found that a large amount of herbal tea rich in PFRs was consumed during the last 3 months of her pregnancy. The need to limit ingestion of foods with high concentrations of PFRs to avoid fetal ductal constriction in the third trimester of pregnancy is well known (15).

It is well known that maternal consumption of PFRs during pregnancy may cause fetal ductal constriction (15,16). Although we were not sure whether the ductal closure had occurred in utero or after birth, probably ductal narrowing had taken place during the third trimester in our case owing to consumption of a large amount of herbal tea as a kind of PFR. We wanted to emphasize the importance of nutrition during pregnancy with our case with transient RVH.

REFERENCES

1. Towbin JA, Lipshultz SE. Genetics of neonatal cardiomyopathy. *Curr Opin Cardiol* 1999;14:250-62.
2. Vaillant MC, Chantepie A, Casasoprana A, Chamboux C, Suc AL, Gold F, et al. Transient hypertrophic cardiomyopathy in neonates after acute fetal distress. *Pediatr Cardiol* 1997;18:52-6.
3. Werner JC, Sicard RE, Hansen TW, Solomon E, Cowett RM, Oh W. Hypertrophic cardiomyopathy associated with dexamethasone therapy for bronchopulmonary dysplasia. *J Pediatr* 1992;120(2 Pt 1):286-91.
4. Akcoral A, Oran B, Tavli V, Oren H, Cevik NT. Transient right sided hypertrophic cardiomyopathy in an infant born to a diabetic mother. *Indian J Pediatr* 1996;63:700-3.
5. Luchese S, Manica JL, Zielinsky P. Intrauterine ductus arteriosus constriction: Analysis of a historic cohort of 20 cases. *Arq Bras Cardiol* 2003;81:405-10.
6. Trevett TN Jr, Cotton J. Idiopathic constriction of the fetal ductus arteriosus. *Ultrasound Obstet Gynecol* 2004;23:517-9.
7. Long WE, Wilson AD, Srinivasan S, Seeger KJ, Maginot KR. In utero premature closure of the ductus arteriosus presenting as isolated RVH. *WMJ* 2009;108:370-2.
8. Tomar M, Radhakrishnan S, Shrivastava S. Transient severe isolated RVH in neonates. *Cardiol Young* 2003;13:384-6.
9. Mielke G, Steil E, Gonser M. Prenatal diagnosis of idiopathic stenosis of the ductus arteriosus associated with fetal atrial flutter. *Fetal Diagn Ther* 1997;12:46-9.
10. Mielke G, Gonser M. Closure of the human fetal ductus arteriosus (Letter). *Am J Obstet Gynecol* 1997;176:495-6.
11. Van Marter LJ, Leviton A, Allred EN, Pagano M, Sullivan KF, Cohen A, et al. Persistent pulmonary hypertension of the newborn and smoking and aspirin and nonsteroidal antiinflammatory drug consumption during pregnancy. *Pediatrics* 1996;97:658-63.
12. Boeuf B, Maragnes P, Belzic I, Lacotte J, Bonte JB, Guillois B. Glucocorticoid-induced hypertrophic cardiomyopathy in premature infants: Apropos of 4 cases. *Arch Pediatr* 1997;4:152-7.
13. Sciacca P, Romeo MG, Falsaperla R, Mattia C, Betta P, Tornambene G, et al. Transient RVH in a newborn infant exposed in utero to nimesulide. *Minerva Pediatr* 2005;57:313-8.
14. Schiessl B, Schneider KT, Zimmermann A, Kainer F, Friese K, Oberhoffer R. Prenatal constriction of the fetal ductus arteriosus-related to maternal pain medication? *Z Geburtshilfe Neonatol* 2005;209:65-8.
15. Zielinsky P, Piccoli AL Jr, Manica JL, Nicoloso LH. New insights on fetal ductal constriction: Role of maternal ingestion of polyphenol-rich foods. *Expert Rev Cardiovasc Ther* 2010;8:291-8.
16. Zielinsky P, Manica JL, Piccoli Jr A, et al. Ductal flow dynamics right ventricular size are influenced by maternal ingestion of polyphenol-rich common beverages in normal pregnancies. *Ultrasound Obstet Gynecol* 2007;30:397.