

Perifoveal Cupping Detected by Optical Coherence Tomography May Represent an Early Sign of Antimalarial-Associated Maculopathy

Burak TURGUT^{a1}, Süleyman KOCA²

¹Firat University, Department of Ophthalmology, Elazig, Turkey

²Firat University, Department of Rheumatology, Elazig, Turkey

ABSTRACT

Objective: To evaluate foveal structural changes by spectral domain optical coherence tomography (Sd-OCT) in patients receiving antimalarials.

Materials and Methods: The study was designed as an observational case-control study. Twenty eight patients receiving chloroquine (CQ) or hydroxychloroquine (HCQ) were evaluated clinically using Sd-OCT and automated visual fields. Twenty age-matched subjects serving as controls were imaged with Sd-OCT.

Results: The mean age of the patients was 34.2 years (ranged from 22 to 40 years). All patients were female. The control subjects were included twenty females (mean age: 31.4; ranged from 19 to 42 years). Eighteen patients receiving anti-malarial drugs had mild retina pigment epithelium (RPE) changes and perifoveal cupping detected by Sd-OCT without visual field defect. In the rest of patients in and the controls, perifoveal retinal thicknesses as well as central foveal thicknesses did not show any significant difference. These cases had not perifoveal cupping and visual field defect. The mean central foveal thicknesses in the patients with perifoveal cupping and without perifoveal cupping were 219.57±20.12 µm and 222.42±24.02 µm, respectively. The mean central foveal thickness, as determined by OCT, was 221.13±25.44 (range 201–248 µm) in the patients and 218.96±22.02 µm (range 189–239 µm) in controls. The difference between the groups was not statistically significant (p=0.7).

Conclusion: Perifoveal cupping, in the other words, perifoveal retinal thinning may be a predictor for impending antimalarial related maculopathy.

Key Words: Optical coherence tomography, Chloroquine, Hydroxychloroquine, Perifoveal cupping.

ÖZET

Optik Koherens Tomografi ile Saptanan Perifoveal Çanaklaşma Antimalaryal İlişkili Makulopatinin Erken Bulgusu Olabilir

Amaç: Antimalaryal ilaç kullanan hastalarda spectral domain optik koherens tomografi kullanılarak foveal yapısal değişiklikleri değerlendirmek.

Gereç ve Yöntem: Çalışma bir gözlemsel vaka-kontrol çalışması olarak kurgulandı. Klorakin veya hidroksiklorakin alan 28 hasta ile benzer demografik özelliklere sahip 20 kontrol olgusu spektral domain optik koherens tomografi ve otomatize görme alanı ile klinik olarak değerlendirilerek bulgular karşılaştırıldı.

Bulgular: Hastaların yaş ortalaması 34.2 yaş (22 to 40 yaş) idi. Tüm hastalar kadındı. Kontrol olgularının tümü kadın olup yaş ortalaması 31.4 yaş (19-42) idi. Antimalaryal ilaç alan hastaların onsekizinde görme alanı defekti bulunmadan hafif retina pigment epitel değişikliği ve optik koherens tomografi ile saptanan perifoveal çanaklaşma mevcuttu. Geri kalan hastalarda ve de kontrol grubundaki bireylerde santral foveal kalınlıklar gibi perifoveal retinal kalınlıklar da herhangi bir anlamlı fark göstermedi. Bu olgularda perifoveal çanaklaşma ve görme alanı defekti saptanmadı. Perifoveal çanaklaşma olan ve çanaklaşma olmayan hastalardaki santral foveal kalınlıklar sırasıyla 219.57±20.12 µm ve 222.42±24.02 µm idi. Optik koherens tomografi ile saptanan ortalama santral foveal kalınlık hasta grubunda 221.13±25.44 µm (201–248 µm aralığında) ve kontrol grubunda 218.96±22.02 µm (189–239 µm aralığında) idi. Gruplar arasındaki farklılık istatistiksel olarak anlamlı değildi (p=0.740).

Sonuç: Perifoveal çanaklaşma, diğer deyişle perifoveal retinal incelmeye antimalaryal ile ilişkili makulopatinin gelişiyor olduğunu gösteren bir prediktör olabilir.

Anahtar Kelimeler: Optik koherens tomografi, Klorakin, Hidroksiklorakin, Perifoveal çanaklaşma.

Antimalarial drugs hydroxychloroquine (HCQ) and chloroquine (CQ) are widely used in the treatment of systemic autoimmune disorders such as systemic lupus erythematosus (SLE) rheumatoid arthritis (RA), discoid lupus erythematosus (DLE), dermatomyositis, Sjogren's syndrome, and other diseases since the 1940s (1, 2). The irreversible retinopathy, which may lead to severe loss of visual fields and visual acuity, is the most important side effects of antimalarials. The visual field defects correlate with the degree of retinal damage, and it is known as the first indicator of antimalarial

related retinopathy. Although, in experimental studies, the earliest abnormalities were detected in retinal ganglion cells, paracentral photoreceptors showed the most severe damage. Therefore, it is difficult to detect antimalarial related retinopathy before visual field defect by conventional methods (3-5).

There is no definitive clinical test for the identification of toxic effects of antimalarials before the appearance of specific funduscopic changes, visual field defects and symptomatic loss of vision. Screening for CQ/HCQ retinopathy is difficult due to the vastness of

^a Corresponding Adress: Dr. Burak TURGUT, Firat University, Department of Ophthalmology, Elazig, Turkey
e-mail: drburakturgut@yahoo.com

patients receiving treatment, nonspecificity of antimalarial related retinopathy symptoms including reading and far-sight difficulties, and limited availability and high costs for sophisticated diagnostic methods (2-5).

In this study, we aimed to evaluate foveal structural changes by spectral domain optical coherence tomography (Sd-OCT) in patients receiving CQ or HCQ.

MATERIALS AND METHODS

Twenty eight female patients (22 SLE and 6 RA) referred to our ophthalmology outpatient clinic from Rheumatology Clinic for the evaluations of antimalarial maculopathy were examined. Twenty controls were selected from female individuals with normal Sd-OCT images and visual fields. All patients and the control subjects underwent a complete ophthalmologic examination including best-corrected visual acuity, slit-lamp biomicroscopy, intraocular pressure measurement, dilated funduscopy.

Repeated visual field tests were performed with full-threshold screening program, by an automated perimeter (Octopus 101, Haag Streit Interziag Inc.). The Sd-OCT images of patients and controls were evaluated by single observer (BT) who is retinal specialist experienced in the evaluation of Sd-OCT images. OCT examinations were performed using a Spectral OCT (OCT/SLO, OTI Inc., Toronto, Canada). During OCT examination the maculae were scanned on six radial sections including the horizontal, vertical and oblique planes through the centre of the fovea. The foveal thicknesses and the perifoveal thicknesses at the endpoint of the flattening foveal contour in four quadrants (temporal, nasal, superior and inferior) were measured automatically using the topography software and were manually measured using caliper built into the OCT device, respectively (Figure 1 and 2).

The study was performed following the tenets of the Declaration of Helsinki and the approval of the institutional ethics committee and was designed an observational comparative clinical trial. Informed consents were obtained from the participants.

Statistical Analysis

Statistical analysis was performed using the Statistical Package for the Social Sciences version 13.0 (SPSS, Inc., Chicago, IL, USA). The Student t test and chi-square test was used to compare nominal and categorical variables among the study groups, respectively. Results were given as means \pm standard deviations. P value less than 0.05 was considered as statistically significant.

RESULTS

The mean age of the patients was 34.2 years (ranged from 22 to 40 years). The control subjects were included twenty females (mean age: 31.4; ranged from 19 to 42 years). Twenty two patients had SLE and six patients had RA. Visual acuities were ranged in 20/40-20/20 in all patients. The duration of the antimalarial drug use in the patients was ranged from 18 to 72 months.

Ophthalmoscopy was revealed mild to moderate retina pigment epithelium (RPE) changes in twenty eight patients receiving antimalarials. One patient had incomplete bull's eye maculopathy in the right eye and moderate narrowing of retinal vessels in the left eye beside RPE changes. Although OCT failed to reveal the disruption of inner and outer segment (IS/OS) junction in 26 patients, it demonstrated the perifoveal cystic lesions in both eyes in a patient without perifoveal thinning, and the disruption of IS/OS junction in another patient which has incomplete bull's eye maculopathy and without perifoveal thinning. The mean central foveal thicknesses were 221.1 ± 25.4 (range 201–248 μm) and 218.9 ± 22.1 μm (range 189–239 μm) in patients and controls respectively ($p > 0.05$). 64.3% patients (18 patients) had perifoveal retinal thinning without central foveal thinning and visual field defect (Figure 3 and 4) while 35.7% patients (10 patients) had similar perifoveal retinal thicknesses in controls. The mean perifoveal thickness in patients with perifoveal cupping was lower than in patients without perifoveal cupping ($p = 0.03$) and controls ($p = 0.04$, Table 1).

Table 1. Mean central foveal thickness, and mean perifoveal thicknesses from four quadrants

	Patients (n=28)		Controls (n=20)
	With perifoveal cupping (n=18)	Without perifoveal cupping (n=10)	
Central foveal thickness (μm)	219.57 \pm 20.12	222.42 \pm 24.02	218.9 \pm 22.1
Perifoveal thicknesses			
Nasal quadrant (μm)	198.4 \pm 15.9	245.12 \pm 40.8	249.11 \pm 29.2
Temporal quadrant (μm)	201.70 \pm 20.13	237.8 \pm 46.6	246.5 \pm 35.16
Superior quadrant (μm)	199.31 \pm 23.72	246 \pm 39.1	244.5 \pm 39.58
Inferior quadrant (μm)	200.9 \pm 17.8	230.11 \pm 45.9	251.3 \pm 40.15

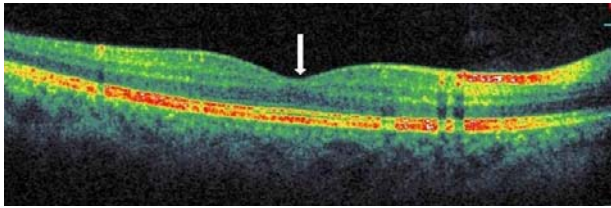


Figure 1. Macular OCT scan image samples from controls. Spectral domain OCT demonstrates normal foveal contour and central foveal depression (white arrow)

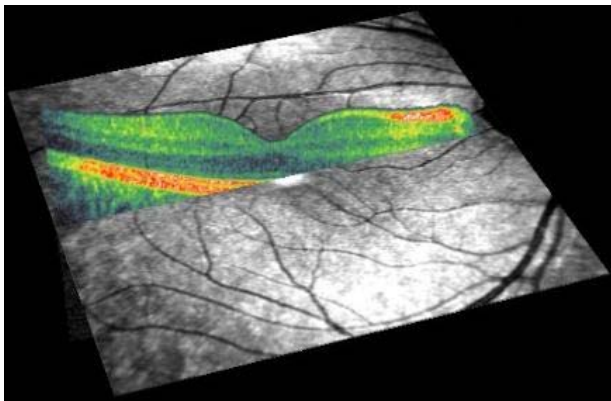


Figure 2. OCT scan crossing over fovea superimposed onto scanning laser ophthalmoscope image for same control

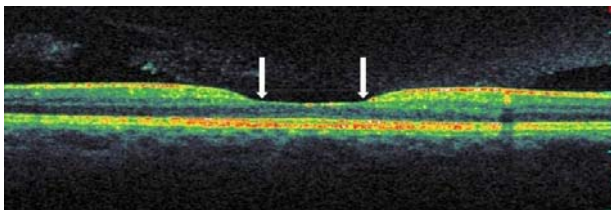


Figure 3. Macular OCT scan image samples from patients receiving antimalarial. Spectral domain OCT demonstrates flattening of foveal contour, perifoveal cupping (white arrows) and disappearance in the visualization of normal central foveal depression but neither loss of the photoreceptor nor increased choroidal reflectivity

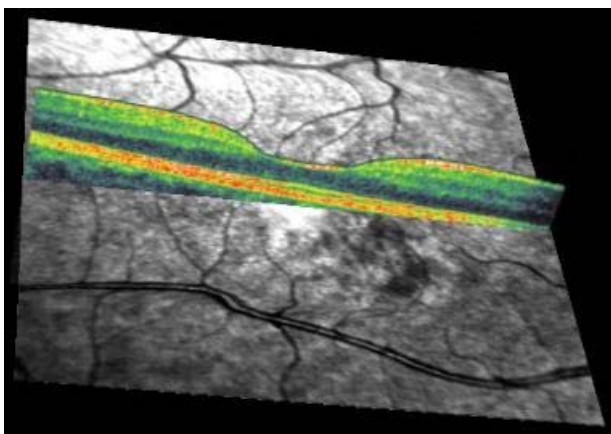


Figure 4. OCT scan crossing over fovea superimposed onto scanning laser ophthalmoscope image for same patient.

DISCUSSION

Antimalarial drugs CQ and HCQ are widely used in the treatment of various autoimmune disorders. Although antimalarial are usually well tolerated, often retinal toxicity which may cause vision-threatening effects is required to change or discontinue these drugs. Thus, it is important to detect early stages of CQ/HCQ retinopathy and, to predict the development of retinopathy which may be more useful (1, 5).

The pathophysiologic mechanisms of CQ/HCQ retinopathy are not exactly understood. The earliest abnormalities in retina are detected in ganglion cells. Parafoveal photoreceptors are showed the most severe damage whilst ganglion cells and retinal pigment epithelium (RPE) cells are less severely affected (2-6). Histopathologic studies of human and animal retinas with CQ/HCQ toxicity have shown loss of ganglion cells and subsequently photoreceptors and consequently leading to atrophy of the RPE, especially in the perifoveal region (2).

Antimalarial related maculopathy is characterized by relative sparing of foveolar function in the presence of parafoveal dysfunction and subsequent photoreceptor degeneration (1, 4).

Antimalarial-associated retinopathy may be classified as premaculopathy and bull's eye retinopathy. The visual field defects correlate with the degree of retinal damage and it is the first indicator of retinopathy (3-5).

Antimalarials are highly concentrated in the pigmented ocular tissues such as RPE, binds to melanin, and may remains there for prolonged periods of time even after cessation of therapy. The destruction of parafoveal photoreceptors with sparing of the foveal cones explains the fundoscopic appearance of the bull's eye maculopathy (1, 2).

Premaculopathy consists of fine pigmentary stippling of the macula and loss of foveal reflex. It may progress to true retinopathy that usually consists of stippled hyperpigmentation of the macula, and is surrounded first by a clear zone of depigmentation and then by a second ring of pigment, giving a bull's eye appearance. Frequent screening may be necessary to detect reversible premaculopathy (3-5).

Early CQ/HCQ retinopathy though still inadequately described, is defined as an acquired parafoveal scotoma on threshold visual field testing, with no detectable retinal findings, while advanced retinopathy has associated parafoveal RPE atrophy (1-3).

The ganglion cell population is the densest at the macular region. So, antimalarials would affect firstly ganglion cells at perifoveal region. The fact that the first functional change is a parafoveal scotoma, and the first observable RPE changes are seen in this area supports this assumption (1-5). Therefore, the detection of

perifoveal cupping or perifoveal retinal thinning may provide more accurate and earlier predictions of antimalarial toxicity, even before the scotoma develops and even maybe prevent further damage by stopping the drug at this point.

The OCT may give the information on the status of the RPE, photoreceptors, and the retinal thickness (6-9). Recently, Rodriguez et al have shown discontinuity or loss of perifoveal photoreceptor inner segment and outer segment (IS/OS) junctions and thinning of the outer nuclear layer by ultra high resolution optical coherence tomography (UHR-OCT) in patients receiving HCQ (8). However, they have not been able to show distinctive effects on the ganglion cells. We present a distinctive finding on these cells and consider that it may be termed as perifoveal cupping because of the thinning or foveolar flattening at the retinal ganglion cell layer.

Retinal structural abnormalities in patients receiving antimalarial drugs have been identified prior to ophthalmoscopically visible alterations using multifocal electroretinography (mfERG) and UHR-OCT (8-10). However, the screening for antimalarial related maculopathy is difficult because of the vastness of patients receiving treatment, nonspecific early symptoms (reading difficulties, far sight difficulties), and limited availability and the sophistication and expensiveness of diagnostic methods above mentioned. In addition, UHR-OCT is not available as yet for general clinical use (7).

Up to date, the reduction of retinal thickness and disruption at IS/OS junction at perifoveal region were demonstrated in the OCT studies concerning antimalarial related maculopathy (7-11). Kellner et al. reported that loss of outer nuclear layer thickness detected by OCT might be the earliest indicator of CQ retinopathy. Also, Kellner et al demonstrated that retinal thickness in parafoveal area by OCT was most severely reduced (7-10).

REFERENCES

1. Fyodorov I, Sturm PF, Robertson WW Jr. Compression-plate fixation of femoral shaft fractures in children aged 8 to 12 years. *J Pediatr Orthop* 1999; 19: 578-81.
2. Yam JC, Kwok AK. Ocular toxicity of hydroxychloroquine. *Hong Kong Med J* 2006; 12: 294-304.
3. Wetterholm DH, Winter FC. Histopathology of chloroquine retinal toxicity. *Arch Ophthalmol* 1964; 71: 82-7.
4. Weiner A, Sandberg MA, Gaudio AR, Kini MM, Berson EL. Hydroxychloroquine retinopathy. *Am J Ophthalmol* 1991; 112: 528-34.
5. Easterbrook M. The ocular safety of hydroxychloroquine. *Semin Arthritis Rheum* 1993; 23: 62-7.
6. Marmor MF, Carr RE, Easterbrook M, Farjo AA, Mieler WF. Recommendations on screening for chloroquine and hydroxychloroquine retinopathy: a report by the American Academy of Ophthalmology. *Ophthalmology* 2002; 109: 1377-82.
7. Huang D, Swanson EA, Lin CP, et al. Optical coherence tomography. *Science* 1991; 254: 1178-81.
8. Kellner S, Weinitz S, Kellner U. Spectral domain optical coherence tomography detects early stages of chloroquine retinopathy similar to multifocal electroretinography, fundus autofluorescence and near-infrared autofluorescence. *Br J Ophthalmol* 2009; 93: 1444-7.
9. Rodriguez-Padilla JA, Hedges TR 3rd, et al. High-speed ultra-high-resolution optical coherence tomography findings in hydroxychloroquine retinopathy. *Arch Ophthalmol* 2007; 125: 775-80.

Similarly, two recent case reports by Fung and Fontaine et al. demonstrated that the detection of reduced macular thickness with hyporeflexive atrophic retina and pigment epithelium or increased reflectance of the choroid layer in a perifoveal region by OCT can support a suspected diagnosis of CQ or HCQ related retinal toxicity (11, 12). In addition, Korah et al reported that loss of ganglion cell layers, causing marked retinal thinning of the macula and parafoveal region may be early evidence of CQ toxicity (13).

In our previous case report, we had been demonstrated the regression in the HCQ maculopathy by Sd-OCT. However, we did not observe any foveal contour changes such as perifoveal cupping or the flattening of the foveal contour and foveal/perifoveal retinal thinning (14).

However, none of these studies above mentioned demonstrated the foveal cupping. The observation of this finding in some patients without clinically and perimetrically specific findings of antimalarial maculopathy is spectacular. In our study, we demonstrated the enlargement of central foveolar depression area due to flattening foveal contour or perifoveal cupping in eighteen patients. In these cases, central foveal thicknesses were normal range whereas perifoveal retinal thicknesses were reduced.

Conclusion

OCT is a noninvasive and easy method for screening antimalarial maculopathy (6- 10). The detection of perifoveal cupping in patients without specific visual field defects in OCT, and with mild visual acuity complaints may be a predictor for early antimalarial maculopathy. However, further studies are necessary to verify this prediction.

Acknowledgments The authors indicate no financial support or financial conflict of propriary interest.

10. Kellner U, Renner AB, Tillack H. Fundus autofluorescence and mfERG for early detection of retinal alterations in patients using chloroquine/hydroxychloroquine. *Invest Ophthalmol Vis Sci* 2006; 47: 3531-8.
11. Kellner U, Kellner S, Weinitz S. Chloroquine retinopathy: lipofuscin- and melanin-related fundus autofluorescence, optical coherence tomography and multifocal electroretinography. *Doc Ophthalmol* 2008; 116: 119-27.
12. Fung AE, Samy CN. Optical coherence tomography findings in hydroxychloroquine and chloroquine-associated maculopathy. *Retinal Cases & Brief Reports* 2007; 1: 128-30.
13. Fontaine F, Rougier MB. Optical coherence tomography in hydroxychloroquine retinopathy: two observational case reports. *Retinal Cases & Brief Reports* 2007; 1: 131-3.
14. Korah S, Kuriakose T. Optical coherence tomography in a patient with chloroquine-induced maculopathy. *Indian J Ophthalmol* 2008; 56: 511-3.
15. Turgut B, Turkuoglu P, Koca SS, Aydemir O. Detection of the regression on hydroxychloroquine retinopathy in optical coherence tomography. *Clin Rheumatol* 2009; 28: 607-9.

Gönderilme Tarihi: 01.06.2012