

# Antenatal sonographic diagnosis of diffuse cavernous hemangioma of the uterus

## Uterusun diffüz kavernöz hemanjiyomunun antenatal sonografik tanısı

Aytül ÇORBACIOĞLU ESMER, Mehmet ÖZSÜRMEİ, Atıl YÜKSEL, İbrahim KALELİOĞLU, Recep HAS, Nevin BAKAR

### ABSTRACT

Cavernous hemangioma of the uterus may be either localized presenting as an endometrial polyp or a uterine mass mimicking myoma, or as a diffuse mass in which most of the uterine wall is composed of enlarged vascular spaces replacing the normal myometrium. It is usually asymptomatic, but can present with menometrorrhagia and infertility in gynecological practice, and intra or postpartum bleeding or thromboembolism in obstetric patients. Diffuse cavernous hemangioma can be seldom, identified during routine antenatal ultrasonographic examination as the thickened uterine wall composed of cavernous fluid-filled spaces with turbulent flow. We present an antenatally diagnosed case of diffuse cavernous hemangioma in which the fetus was severely growth-restricted. Caesarean section was performed successfully without any intra or postpartum hemorrhage.

**Keywords:** Cavernous hemangioma, Uterus, Antenatal diagnosis, Ultrasonography

### ÖZET

Uterusun kavernöz hemanjiyomu, endometriyal polip veya myoma benzeyen bir kitle şeklinde ortaya çıkabileceği gibi (lokalize tip), uterus duvarında normal myometriyumun yerini alan geniş vasküler boşluklar şeklinde de (diffüz tip) görülebilir. Genellikle asemptomatiktir, ancak jinekolojik pratikte menometroraji ve infertilite şeklinde, obstetrik hastalarda ise intrapartum veya postpartum kanama ya da tromboembolizm şeklinde ortaya çıkabilir. Diffüz kavernöz hemanjiyom, türbülant akım içeren kavernöz boşluklarla dolu kalınlaşmış uterus duvarı görüntüsüyle, rutin antenatal ultrasonografi incelemesi sırasında nadiren saptanabilir. Fetusta ağır gelişme geriliği olan, sezaryen sırasında ve sonrasında hemorajik komplikasyon gelişmeyen ve antenatal dönemde tanısı koyulan bir diffüz kavernöz hemanjiyom olgusu sunmaktayız.

**Anahtar kelimeler:** Kavernöz hemanjiyom, Uterus, Antenatal tanı, Ultrasonografi

Aytül Çorbacıoğlu Esmem (✉), Mehmet Özsürmeli, Atıl Yüksel, İbrahim Kalelioğlu, Recep Has  
*Division of Maternal-Fetal Medicine, Department of Obstetrics and Gynecology, Faculty of Medicine, Istanbul University, Istanbul, Turkey*  
e-mail: [aytulcorbacioglu@gmail.com](mailto:aytulcorbacioglu@gmail.com)

Nevin Bakar  
*Department of Radiology, Faculty of Medicine, Istanbul University, Istanbul, Turkey*

Submitted/Gönderilme: 03.10.2013 Accepted/Kabul: 15.11.2013

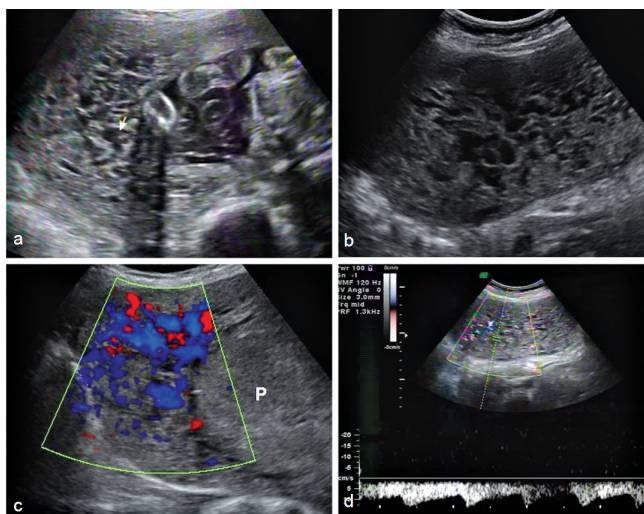
### Introduction

Hemangioma is a benign tumor originating from endothelial cells of blood vessels or from the pericytes located on the outer side of the vascular wall [1]. There are two types of hemangioma; the capillary type is usually located on the skin, while cavernous hemangioma can be found in the visceral organs such as the liver, kidney and intestinal wall as well as on the skin, and in bone and muscle [1]. Cavernous hemangioma of the uterus is a very rare affliction and its exact incidence is not known. It may either be localized presenting as an endometrial polyp or as a uterine mass mimicking myoma, or as a diffuse mass in which most of the uterine wall is composed of enlarged vascular spaces replacing the normal myometrium [1-3]. Cavernous hemangioma of the uterus is usually asymptomatic, but can present with menometrorrhagia and infertility in gynecological practice, and intra or postpartum bleeding or thromboembolism in obstetric patients [1-4]. More seldom, diffuse cavernous hemangioma can be identified during routine antenatal ultrasonographic examination as the thickened uterine wall composed of cavernous, fluid-filled spaces with turbulent flow [2].

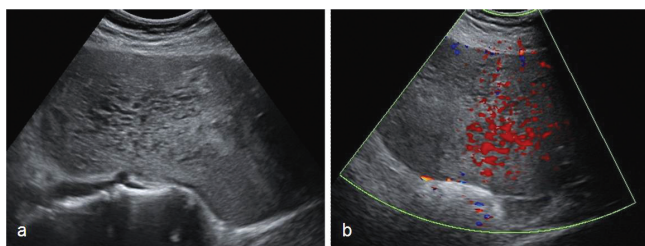
We present an antenatally diagnosed case of diffuse cavernous hemangioma in which the fetus was severely growth-restricted and Caesarean section was performed successfully without any intra or postpartum hemorrhage.

### Case Report

A 25-year-old nulliparous woman was referred to our clinic at 25 weeks' gestation due to fetal growth restriction. The patient's medical history was unremarkable except for the cutaneous hemangiomas located on the foot, clitoris and gluteal region. Ultrasonographic examination revealed severe fetal growth restriction with all of the biometric parameters consistent with 21 weeks of gestation. There were no congenital anomalies and amniotic volume index was 9 cm. Doppler examination of the bilateral uterine artery revealed an early diastolic notch with a pulsatility index (PI) of 1.74 and 1.79 at the right and left uterine arteries, respectively. The umbilical artery Doppler was normal (PI:0.96). The entire myometrium was diffusely thickened and was composed of numerous echolucent areas with a Swiss-cheese appearance (Figure 1 a-b). Color Doppler depicted a bidirectional flow and spectral Doppler showed a mixed arterial and venous pattern with low velocity (Figure 1 c-d). Based on the patient's



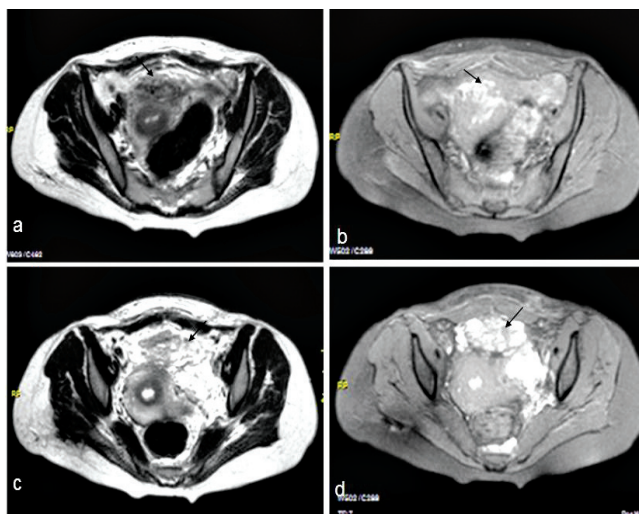
**Figure 1a.** Ultrasonographic examination at 25 weeks' gestation showing echolucent areas within myometrium (arrow). **Figure 1b.** Grey scale ultrasonography shows the diffusely thickened myometrium with numerous echolucent areas. **Figure 1c.** Color Doppler shows the vascularization in the echolucent areas. Normal placenta (P) is depicted near the myometrium. **Figure 1d.** Spectral Doppler showing arterial flow.



**Figure 2a.** Ultrasonographic examination one week after delivery showing echolucent areas within the myometrium. **Figure 2b.** Color Doppler showing vascular flow in the echolucent areas.

medical history, we considered that hemangioma was the most probable diagnosis. We did not want to perform another imaging modality such as magnetic resonance imaging (MRI) during pregnancy due to the potential harmful effect of contrast medium to the fetus.

The patient did not attend follow-up visits until she was referred to our unit with severe hypertension at 32 weeks' gestation. No proteinuria was detected in her urine analysis and alpha methyl dopa treatment was started with the aim to control maternal blood pressure. The fetal biometric parameters were consistent with 25 weeks of gestation and there was an hydramnios. Doppler measurements showed increased resistance in the umbilical artery (PI:1.67, >95 percentile) and low resistance in the middle cerebral artery (PI: 1.19, <2.5 percentile). At the 32<sup>nd</sup> week of gestation, Caesarean section was performed with an indication of fetal distress. The neonate weighed 635 g and had Apgar scores of 9 and 10 at the 1<sup>st</sup> and 5<sup>th</sup> minutes, respectively. The operation was completed without complications. The appearance of the uterus and myometrium was totally normal



**Figure 3a.** MRI imaging in axial plane one week after delivery. T2-weighted sequence showing the vasular lesion in myometrium (arrow). **Figure 3b.** Vascular lesion is demonstrated in fat suppressed T1-weighted sequence (arrow). **Figure 3c.** T2-weighted sequence showing the vascular lesion located at the left adnexal area extending to anterior of uterus and superior of bladder (arrow). **Figure 3d.** The same lesion is shown on fat suppressed T1-weighted sequence (arrow).

except for a hypervascular mass measuring 8x4 cm located on the anterior uterine wall just superior to the bladder. The patient's postoperative course was also unremarkable with no significant postpartum bleeding. Ultrasonography performed at the 1<sup>st</sup> and 8<sup>th</sup> postpartum weeks showed that enlarged vascular spaces within the myometrium persisted (Figure 2). MRI performed one week after delivery revealed hyperintense lesion within the myometrium suggesting cavernous hemangioma of the uterus in fat suppressed T1-weighted sequence (Figure 3a-b). Furthermore, T2-weighted sequences showed another hyperintense lesion with heterogenous contrast-enhancement also suggesting a hemangioma located in the left adnexal lodge (58x57 mm) extending to the anterior of the uterus and superior to the bladder (46 x 38 mm) and to the left of the vagina and vulva (53 x 28 mm) (Figure 3c-d).

## Discussion

Uterine cavernous hemangioma may be either congenital or acquired secondarily to curettage, pelvic surgery, endometrial carcinoma, trophoblastic disease or maternal ingestion of diethylstilbesterol [2]. A congenital form may be associated with hereditary syndromes such as Klippel-Trenauney-Weber or hereditary hemorrhagic telangiectasia [3,5]. Differential diagnosis of cavernous hemangioma involves wide-spread arteriovenous malformation, hydatiform mole and dilated lymphatics due to the congenital blockage of the lymph system in the pelvis. Arteriovenous (AV) malformation represents abnormal communication between arteries and veins in which intervening capillaries are absent and veins are arterialized [6]. It is not easy to differentiate AV malformation from hemangioma by ultrasound and color Doppler, since both of them are high flow vascular malformations and they cannot be differentiated on the basis of

mean vessel density, mean arterial peak flow velocity and mean resistive index values [7]. Paltiel et al. reported that only mean venous peak flow velocity was higher in AV malformation compared with hemangioma [7]. Clinical fetuses are also helpful in differential diagnosis, as AV malformation rarely appears before adolescence, while half of the hemangiomas are seen at birth and involute with age [8]. Our patient's history of multiple cutaneous hemangiomas led us to consider hemangioma to be the most probable diagnosis, since vascular lesions of the skin have been recognized as clues for the possible existence of hemangiomatosis syndromes and associated visceral hemangiomas [9]. We ruled out hydatiform mole as the Swiss cheese pattern involved only the uterus. Also, the diagnosis did not appear to be lymphatic dilatation, because the expected symptoms such as watery vaginal discharge or leg swelling were not present in our patient.

Cavernous hemangioma of the uterus is associated with several severe complications in pregnancy. Diffuse involvement of the uterus may result in profuse uterine bleeding necessitating hysterectomy, at the time of delivery or during postpartum period as late as 11 weeks after delivery [4,10,7]. However, many patients have had successful delivery and an uneventful postpartum course without excessive bleeding as with the case we present [11-13]. Cavernous hemangiomas may also be complicated by disseminated intravascular coagulation due to platelet entrapment by abnormally proliferating endothelium within the hemangiomas [1]. Bhavsar et al. reported a case in which a thrombosed cavernous hemangioma of the myometrium resulted in a fatal pulmonary embolism one week after delivery [1]. Furthermore, cavernous hemangioma has been suggested to lead to amniotic fluid embolism due to increase in the vascular cross-sectional area [14].

Even though the histopathological examination is the gold standard for confirming diagnosis, ultrasonography, Doppler and MRI have been used for the diagnosis in the literature. Arteriography and computerized tomography (CT) can also be helpful, however their usefulness is limited during pregnancy [10,7]. Characteristic ultrasonographic finding is defined as an extensive lesion involving the whole corpus with numerous echolucent cystic spaces replacing the uterine wall [14]. The previous reports showed that color Doppler was characterized with turbulent flow defined as 'wild' or 'red and blue', while power Doppler revealed slow flow in the affected area [14]. Similarly, in our case, bidirectional flow was observed in color Doppler, while there was mixed arterial and venous flow in spectral Doppler. To our knowledge, this is the second case that used MRI for confirmation of the diagnosis. Since we did not want to administer intravenous contrast medium during pregnancy because of the potential harmful effects to the fetus, we preferred to use MRI after delivery. MRI supported our diagnosis depicting the T1-hyperintense lesion within the myometrium. MRI was also beneficial for the detection of the other pelvic lesion compatible with hemangioma which was not identified on ultrasonography.

To the best of our knowledge, only nine antenatally diagnosed uterine diffuse cavernous hemangioma cases have been reported in the literature [5,6,11-17]. In the case we present, different from previous reports, there was severe fetal growth restriction due to uteroplacental insufficiency. There is no previous data indicating the association of uterine hemangioma with uteroplacental insufficiency. Maternal-fetal circulation is established by the trophoblastic invasion in which the uterine mucosa is eroded and

maternal spiral arteries are transformed into large diameter vessels of low resistance [18]. Since the development of this complex physiologic activity depends on the expression of many cellular and immunologic markers, the change in the microvasculature of uterus in diffuse hemangioma may interfere with the trophoblastic functions, eventually resulting in placental insufficiency. However, studies are needed to clarify whether hemangioma is the cause of fetal growth restriction or a coincidence.

In conclusion, we presented a rare case of diffuse cavernous hemangioma of the uterus which was detected antenatally by ultrasonographic examination. Since uterine hemangioma may result in serious complications such as thromboembolism or postpartum bleeding, sonographic diagnosis before delivery allows close follow-up during the second and third trimesters, close observation of delivery, and early intervention if postpartum bleeding occurs.

## References

- Bhavsar T, Wurzel J, Duker N. Myometrial cavernous hemangioma with pulmonary thromboembolism in a post-partum woman: a case report and review of the literature. *J Med Case Rep* 2012;6:397. doi: 10.1186/1752-1947-6-397.
- Sharma JB, Chanana C, Gupta SD, et al. Cavernous hemangiomatous polyp: an unusual case of perimenopausal bleeding. *Arch Gynecol Obstet* 2006;274:206-8. doi:10.1007/s00404-006-0161-z.
- Lee EJ, Kim SH, Kim YH. Uterine cavernous haemangioma in a post-menopausal woman: CT and MRI findings mimicking uterine myoma with degeneration. *Br J Radiol* 2011;84:e68-71. doi: 10.1259/bjr/56484373.
- Benjamin MA, Yaakub HR, Telesinghe PU, et al. A rare case of abnormal uterine bleeding caused by cavernous hemangioma: a case report. *J Med Case Rep* 2010;4:136. doi: 10.1186/1752-1947-4-136.
- Verheijen RH, van Rijen-de-Rooij HJ, van Zundert AA, et al. Pregnancy in a patient with Klippel-Trenaunay-Weber syndrome: a case report. *Eur J Obstet Gynecol Reprod Biol* 1989;33:89-94. doi: 10.1016/0028-2243(89)90083-X.
- Comstock CH, Monticello ML, Johnson TW, et al. Cavernous hemangioma: diffuse enlarged venous spaces within the myometrium in pregnancy. *Obstet Gynecol* 2005;106:1212-14. doi:10.1097.AOG.000016404.99506.C8.
- Paltiel HJ, Burrows PE, Kozakewich HP, Zurakowski D, Mulliken JB. Soft-tissue vascular anomalies: Utility of US for diagnosis. *Radiology* 2000;214:747-54.
- Hyodoh H, Hori M, Akiba H, et al. Peripheral vascular malformations: Imaging, treatment approaches, and therapeutic issues. *RadioGraphics* 2005;25:S159-71. doi: 10.1148/rg.25si055509
- Elsayes KM, Menias CO, Dillman JR, Platt JE, Willatt JM, Heiken JP. Vascular malformations and hemangiomatosis syndromes: Spectrum of imaging manifestations. *AJR* 2008;190:1291-9. doi: 10.2214/AJR.07.2779.
- Virk RK, Zhong J, Lu D. Diffuse cavernous hemangioma of the uterus in a pregnant woman: report of rare case and review of literature. *Arch Gynecol Obstet* 2009;279:603-5. doi: 10.1007/s00404-008-0764-7.
- Sütterlin MW, Müller T, Rehn M, Rempen A, Dietl J. Successful abdominal delivery in a woman with sonographic diagnosis of diffuse cavernous hemangioma of the uterus. *Am J Perinatol* 1998;15:423-25. doi:10.1055/s-2007-993969.
- Lotgering FK, Pijpers L, van Eijck J, Wallenburg HCS. Pregnancy in a patient with diffuse cavernous hemangioma of the uterus. *Am J*

- Obstet Gynecol 1989;160:628-30. doi:10.1016/S0002-9378(89)80044-4.
13. Weissman A, Talmon R, Jakobi P. Cavernous hemangioma of the uterus in a pregnant woman. *Obstet Gynecol* 1993;81:825-7.
  14. Thanner F, Suetterlin M, Kenn W, et al. Pregnancy-associated diffuse cavernous hemangioma of the uterus. *Acta Obstet Gynecol Scand* 2001;80:1150-1. doi: 10.1034/j.1600-0412.2001.801217.x
  15. Hadlock FP, Deter RL, Carpenter R, Park SK, Athey PA. Hypervascularity of the uterine wall during pregnancy: incidence, sonographic appearance, and obstetric implications. *J Clin Ultrasound* 1980;8:399-403. doi:10.1002/jcu.1870080502.
  16. Acevado Gallegos S, Gallardo Gaona JM, Velazquez Torres B, Espino I Sosa S, Santarrosa Pérez MA, Guzmán Huerta ME. Diffuse cavernous hemangioma of the uterus diagnosed during pregnancy. Case report. *Ginecol Obstet Mex* 2011;79:447-51.
  17. Richard DS, Cruz AC. Sonographic demonstration of wide-spread uterine angiomatosis in a pregnant patient with Klippel-Trenaunay-Weber Syndrome. *J Ultrasound Med* 1997;16:631-33.
  18. Bree AF, Siegfried E, Sotelo-Avila C, et al. Infantile hemangiomas: speculation on placental trophoblastic origin. *Arch Dermatol* 2001;137:573-7.