




Aydın Dental Journal

Journal homepage: <http://dergipark.ulakbim.gov.tr/adj>



TREATMENT OF SKELETAL CLASS II DIVISION II MALOCCLUSION WITH ACTIVATOR AND FIXED ORTHODONTIC APPLIANCES: A CASE REPORT

DergiPark
AKADEMİK

Sanaz SADRY PhD DDS¹, Muhammet GÜRÇAN PhD DDS¹, Elif SOLGUN DDS¹

ABSTRACT

The aim of this case report presents a male patient with skeletal Class II, dental Class II division II associated with deep bite treated by using functional appliance and fixed orthodontic treatment. A 15-year, 6-month-old boy presented to our clinic with the complaint of retrognathic mandible. In clinical and radiographic evaluation, skeletal class II and dental class II division II anomaly and increased overbite found. Treatment was started with activator functional appliance. After 10 months, the relationship between mandibular advancement and class I molar

and canine were achieved. 0.018 slot roth straightwire brackets were applied to the upper and lower teeth. Connecticut intrusion arc used for maxillary incisive teeth. Reverse curve arch wires applied to mandible. Class II elastics were used. Finally, in the case of dental class II division II, increased overbite was treated in 26 months with a good occlusion, normal overbite-overjet and achieved dental class I relationships.

Keywords: *Class II division 2, Deep-bite, Functional therapy, Connecticut intrusion arch (CIA)*

¹ *Istanbul Aydın University Faculty of Dentistry Department of Orthodontics*

İSKELETSEL SINIF II DİVİZYON II MALOKLUZYONUN HASTANIN AKTİVATÖR VE SABİT ORTODONTİ TEDAVİSİ: BİR VAKA RAPORU

Dr. Öğr. Üyesi Sanaz SADRY¹, Dr. Dt. Muhammet GÜRÇAN¹, Dt. Elif SOLGUN¹

ÖZ

Bu vaka raporunun amacı; iskeletsel II ve dişsel Sınıf II divizyon II derin örtülü kapanışı olan erkek hastanın fonksiyonel aparey ile sabit ortodontik tedavisini içeren olguyu sunmaktır. Kliniğimize 15 yıl 6 aylık erkek hasta alt çene geriliği şikayetiyle başvurdu. Yapılan klinik ve radyografik değerlendirmede iskeletsel sınıf II ve dişsel sınıf II divizyon II anomali, artmış overbite bulundu. Tedaviye fonksiyonel aparey olan aktivatör ile başlandı. 10 ay sonra mandibuler ilerletme ve sınıf I molar ve kanin ilişkisi sağlandı. Fonksiyonel

tedaviden sonra alt ve üst dişlere 0.018 slot roth straightwire braketler uygulandı. Daha sonra, Connecticut intruzyon arkı ile kesici dişlerin intruzyonu ve reverse curve arkı ile alt çene spee eğrisi düzeltildi. Son olarak sınıf II elastikler kullanıldı. Sonuçta, dişsel sınıf II divizyon II, artmış overbite olan vakada 26 aylık tedavi sonucunda dişsel sınıf I ilişkilerle birlikte normal overbite ve overjete sahip iyi bir okluzyon sağlanmıştır.

Anahtar Kelimeler: Sınıf II div II, Derin örtülü kapanış, fonksiyonel tedavi, Connecticut intruzyon arkı (CIA)

¹ İstanbul Aydın Üniversitesi Diş Hekimliği Fakültesi Ortodonti ABD

INTRODUCTION

Class II malocclusion is one of the most common problems seen in orthodontics¹. This malocclusion is described as a distal relationship of the mandible related to the maxilla with a combination of different dental and skeletal components which can influence facial aesthetics². Generally patients with skeletal Class II show mandibular retrusion with the upper maxilla normally positioned or retruded³. As a result of this, the correction of dental and jaw sagittal relationships should be accomplished by advancing the lower jaw. It has been advised that functional appliances that posture the mandible forward (i.e. bite jumping appliances) could be used to obtain a sagittal increase of the lower jaw⁴. Of the many malocclusions, Class II Division 2 malocclusions are the most challenging, and long period of treatment times (>36 months) contribute to an inferior result^{5,6}. The traditional treatment approaches involves headgear, functional appliances and/or orthognathic surgery. Functional orthopedic appliances are often used to treat Class II malocclusion originated from mandibular retrusion^{7,8}. Appliance choice can contain removable or fixed functional appliances according to the existing anteroposterior discrepancy, cooperation, and growth period of the patient.

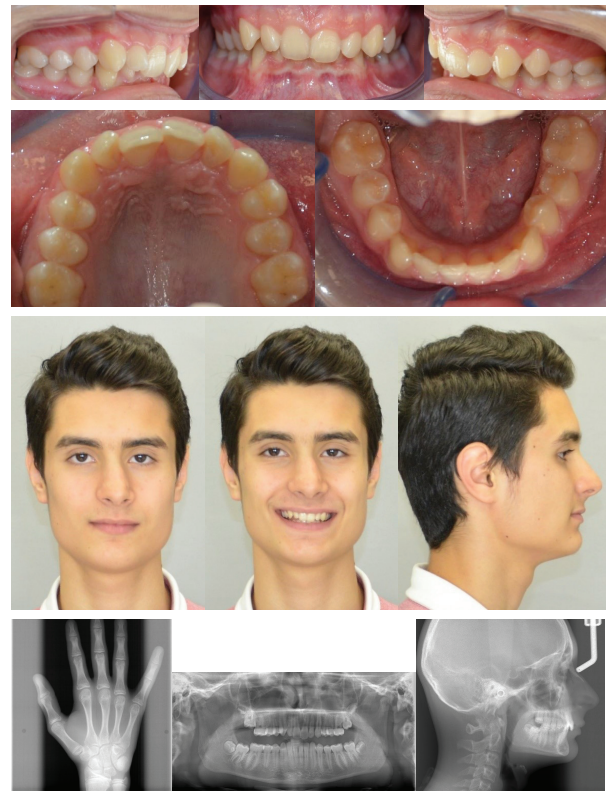


Figure 1 - Initial facial and intraoral photographs

CASE REPORT

A 15 years and 6 months male patient presented for initial examination at the orthodontic clinic in good general health and no history of serious illness or injury. The chief complaint of the patient was related to the fact that the upper incisors were malpositioned. The patient presented with an Angle Class II, Division II malocclusion, convex profile, 2 mm overjet and 6.5mm overbite, sharp retroclination of teeth 11,12, 21 and 22 (Fig.1) The hand wrist radiograph showed that the patient was postpeak skeletal stage (DP3U) and panoramic radiograph of the patient didn't show any caries or pathology (Fig.2). The side profile X-ray and cephalometric tracing showed: retruded and retroclined upper incisors ($1-NA=14^\circ$, $1/$

NA=0mm), normal positioned lower incisors (1-NB=21, IMPA=90), Class I skeletal pattern with mandibular retrognathie, ANB angle=5°, (SNA = 76° and SNB = 71°) and low mandibular growth in the vertical orientation (SN-GoGn=22°, FMA=12° and Y-axis=69°). A facial evaluation showed retruded lower lip and normal positioned upper lip. A treatment plan was established, starting with an activator functional appliance, with the aim to stimulate the growth of the mandible, which included an upper anterior screw for the correction of the retruded upper incisors. The monoblock appliance with anterior screw was employed with activation of 2/4 turn of the screw once a day and has an acrylic cap for the lower incisors to provide retroclination. The appliance was reactivated after the proclination of upper incisors and mandibular growth was stimulated after total 10 months of monoblock treatment with the correction of the molar and canine relationship and space for tooth alignment (Fig 3). After functional treatment fixed orthodontic treatment was started by applying 0.018 slot roth straight wire metal brackets to the lower and upper teeth. Both jaws were passed to 0.016 × 0.022 stainless steel arches in 7 months. Although the teeth were leveled a little overbite was reduced, and then the Connecticut intrusion arch was applied to the upper teeth and reverse curve arch wire applied to the lower teeth. In order to prevent protruding of the cutters and to prevent the wire from sliding forward, the arch wires are curled sharply from the distal of the molars. Class I molar and canine relationship were also achieved with class II elastics after intravenous incision. After ensuring that all the intended goals had been achieved, the fixed orthodontic appliance was removed and the retention phase begun. Fixed lingual retainers were bonded canine to canine on

upper and lower arch and essix retainers were applied (Fig 4). As a result of dental grade II subdivision, increased overbite in the case of 2 years and 2 months of treatment as a result of dental class I relationships with normal overbite and overjet has been achieved a good occlusion.

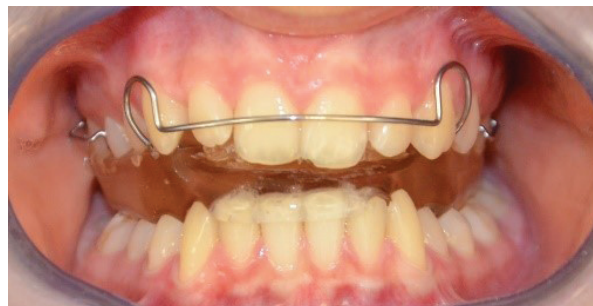

Figure 2: The Monoblock appliance and the reactivation after upper incisors proclination.

DISCUSSION

The Class II div II pattern of malocclusion has unique characteristics; such as severe anterior crowding, with retroclined upper central incisors/ lateral incisors and proclined upper lateral incisors/ canines, increased overbite, and retrognathic mandibula or decreased lower anterior face height 9. Treatment for Class II div II needs careful diagnosis and a treatment plan including esthetics, occlusion, and function. It is crucial to determine patient's facial profile, skeletal pattern, and severity of dental malocclusion in the treatment plan 10. Depending on the patient's age and growth potential, there are several options for treating this malocclusion, e.g., fixed and functional appliances, headgears, and orthognathic surgery. Activator is one of the most common used functional appliance for many years in the treatment of class II division II malocclusion with having a screw in the frontal area of the appliance for proclinations of retruded upper

incisors. Patient can wear appliance full time with little discomfort. The use of monoblock worked for forward placement of mandible as well as for correction of deep bite; acquiring Class I molar and canine relationship; obtaining root axial inclination; satisfactory overjet and overbite; accomplish good intercuspation; enhance facial profile by decreasing facial convexity and increasing anterior lower facial height were other treatment objectives completed.

In this case, comparison of pre-treatment and post-treatment lateral cephalogram showed SNA remained unchanged, and SNB increased by 75°. ANB angle reduced up to 1°. Retroclination of maxillary incisors is corrected and length of the mandible is increased by 6mm.

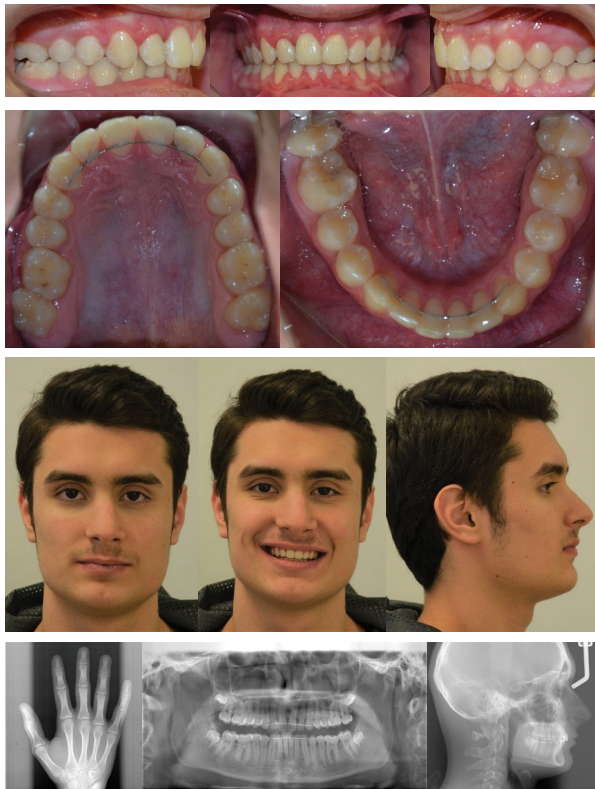


Figure 3: Final facial and intraoral photographs and final radiographs.

CONCLUSION

The result of this case report demonstrates that skeletal class II malocclusion on account of a retruded mandible can be successfully corrected with the help of growth modulation by means of activator therapy. It also makes better skeletal bases along with soft tissue profile and gives better lip competence. As each case distinguishes from one another because of growth variability orthodontist just cannot generalized the appliance therapy. It is very important to select the cases carefully because application of knowledge and skills and good patient cooperation ensures long term stable results.

Table 1: Changes of cephalometric measurements from pre-(T1) to post- (T2) treatment

Sagittal	NORMAL	T0	T1	T2
SNA	82° ± 2	76	76	76
SNB	80° ± 2	71	75	75
ANB	2° ± 2	5	1	1
N-A	0 ± 3	-3	-4	-4
N-PG	-4 ± 5	-8	-4	-5
Witts	-1 ± 3	3	1	1
SN-GOME	32° ± 7	22	23	23
FMA	25° ± 5	12	13	13
N-ME	114.4 ± 5	110	110	110
Ef.middle face (CO-A)	78	77	78	78
Ef.mand.(CO-GN)	95-97	98	107	104

REFERENCES

- [1] W. R. Proffit, H. W. Fields Jr., and L. J. Moray, "Prevalence of malocclusion and orthodontic treatment need in the United States: estimates from the NHANES-III survey," *The International Journal of Adult Orthodontics and Orthognathic Surgery*, vol. 13, no. 2, pp. 97–106, 1998.
- [2] M. Alarashi, L. Franchi, A. Marinelli, and E. Defraia, "Morphometric analysis of the transverse dentoskeletal features of class II malocclusion in the mixed dentition," *The Angle Orthodontist*, vol. 73, no. 1, pp. 21–25, 2003.
- [3] Martina R, Cioffi I, Galeotti A, et al. Efficacy of the Sander bitejumping appliance in growing patients with mandibular retrusion
- [4] Shen G, Hägg U, Darendeliler M. Skeletal effects of bite jumping therapy on the mandible - removable vs. fixed functional appliances. *Orthod Craniofac Res* 2005; 8: 2-10.
- [5] Knierim K, Roberts WE, Hartsfield JK Jr. Assessing treatment outcomes for a graduate orthodontics program: Follow-up study for the classes of 2001-2003. *Am J Orthod Dentofacial Orthop* 2006;130:648-655.
- [6] Pinskaya YB, Hsieh T-J, Roberts WE, Hartsfield JK Jr. Comprehensive clinical evaluation as an outcome assessment for a graduate orthodontics program. *Am J Orthod Dentofacial Orthop* 2004;126:533-543
- [7] C. Nelson, M. Harkness, and P. Herbison, "Mandibular changes during functional appliance treatment," *American Journal of Orthodontics and Dentofacial Orthopedics*, vol. 104, no. 2, pp. 153–161, 1993.
- [8] P. Cozza, T. Baccetti, L. Franchi, L. De Toffol, and J. A. McNamara Jr., "Mandibular changes produced by functional appliances in Class II malocclusion: a systematic review," *American Journal of Orthodontics and Dentofacial Orthopedics*, vol. 129, no. 5, pp. 599.e1–599.e12, 2006.
- [9] Garlapati Y, Jadav CL, Kolasani SR, Mummidi B. Management of sever class II division II malocclusion using simplified MPA – A case report. *APOS Trends Orthod* 2013;3:89-93.
- [10] Flavio U, Ravindra N. Treatment of Class II, Division 2 Malocclusion in Adults: Biomechanical Considerations. *Journal of Clinic Orthodontics* 2003;37(11):599-606.