





To cite this article: Utkan A, Cakici H, Dundar A, Ozkurt B. Metal head fatigue fracture and coin like metal corpora libera in two cases. Is the reason -3 size head usage? Turk J Clin Lab 2019; 10: 268-271.

■ Case Report

Metal head fatigue fracture and coin like metal corpora libera in two cases. Is the reason -3 size head usage?

İki Olguda Metal Baş Yorgunluk Kırığı ve para benzeri metal serbest cisim: neden -3 Baş Kullanımı mı?

Ali UTKAN¹ , Husamettin ÇAKICI² , Abdulrahim DUNDAR¹ , Bulent OZKURT^{1*} 

¹Universtiy of Health Sciences, Ankara Numune Training and Research Hospital, Department of Orthopaedics and Traumatology, Ankara/TURKEY

²Abant İzzet Baysal University, Department of Orthopaedics and Traumatology

Abstract

We report a very rare and extraordinary complication, metal head fatigue fracture at the site of the socket tip deep border and coin like metal corpora libera in two cases with metal on metal total hip prosthesis. Catastrophic wear at the site of the deep border of the collum socket and coin like loose body originating from the crom-cobalt head resulted with metallosis, osteolysis and failure. The outcomes of the revision operations were satisfactory and the patients returned to their daily activity without discomfort in their hip. Headwear is a well-known result of the metal on metal articulation and may present with instability, metallosis, pain and mechanical symptoms. These incidents might be important to investigate for tribological performance of hip implants in biotribology science. We believe -3 sized metal head usage might be the reason of this catastrophic complication their usage should be avoided in metal on metal arthroplasties.

Keywords: metal head; arthroplasty; fracture; dissociation.

Öz

Metal üzeri metal kalça protezi uygulamalarında çok nadir ve sıra dışı bir komplikasyon olan protez baş yuvasının ucunda oluşan yorgunluk kırığını sunmaktayız. Başın boyun yuvasının derin ucundaki katastrofik aşınması ve burada oluşan para benzeri serbest metal parça metallozis, osteoliz ve yetmezliğe neden olmuştur. Revizyon ameliyatı sonuçları tatminkar olmuş ve hastalar sorunsuzca günlük aktivitelerine dönmüşlerdir. Metal üzeri metal eklemlenmelerde başın aşınması iyi bilinen bir sonuçtur ve instabilite, metallozis, ağrı ve mekanik semptomlarla ortaya çıkabilir. Bu gibi vakalar biotribolojik olarak kalça implantlarının tribolojik performanslarının araştırılması için önemli olabilir. Bu katastrofik komplikasyonun nedeninin -3 metal baş kullanımı olduğuna ve metal üzeri metal protezlerde kullanılmaması gerektiğine inanıyoruz.

Anahtar Kelimeler: metal baş; artroplasti; kırık; ayrışma

Corresponding Author*: Bulent OZKURT, Universtiy of Health Sciences, Ankara Numune Training and Research Hospital, Department of Orthopaedics and Traumatology, Ankara/TURKEY

E-mail: drbulentozkurt@yahoo.com

ORCID: 0000-0002-6135-1870

Received: 21.03.2019 accepted: 08.04.2019

Doi: 10.18663/tjcl.542753

Introduction

There are numerous reports about the femoral component fractures occurred across the neck or in the stem portion of the implant after total hip arthroplasty (THA) [1]. Also there are many statements of ceramic head fractures in modular implants with ceramic heads [1]. This is the first report of a modular metal head fracture at the site of the socket tip deep border and coin like metal corpora libera due to catastrophic wear. The presentation of an unusual catastrophic wear with the head dissociation at the deep border of the flute of the head, in which the neck of the prosthesis is plugged in two Metal on Metal (MoM) arthroplasties is discussed. Publishing permission and informed consent forms were obtained from both patients.

Case 1

In July 2014, a 48-year-old female patient referred to hospital owing to concerns about increased hip pain and active hip motion limitation, after a total hip arthroplasty implantation five years previously. She declared that the initial results and function of the operation were satisfactory for four years. A progressive hip pain increasing with weight bearing and limping had initiated 10 months before the reference and four months later increasing groin pain and hip active motion limitation aroused.

The patient was an active teacher. She weighed 56 kg and was 167 cm tall. Neurovascular system examination was normal. She had a positive trendelenburg sign and antalgic gait. Although her active flexion was limited to 80° with 0° of rotation, passive ROM was unrestricted but painful at the end of the range with the exception of external rotation. External rotation was limited to 5°. Approximately 1 cm lower limb discrepancy was determined. A result of complete blood count and biochemistry was within normal range, except slightly high white blood cells. Erythrocyte sedimentation rate was 32mm/h, whereas C-reactive protein level was 3,7 mg/dl. Serum chromium, cobalt, and molybdenum levels were 0.77 ng/mL, 0.24 µg/L and 1.20 µg/L, respectively. Preoperative radiographs revealed an uncemented THA with the metal head to be got thinner asymmetrically and deformed and an acetabular component with loosening and severe periprosthetic osteolysis. Periprosthetic osteolysis was also determined around the proximal part of the femoral component. (Figure 1)

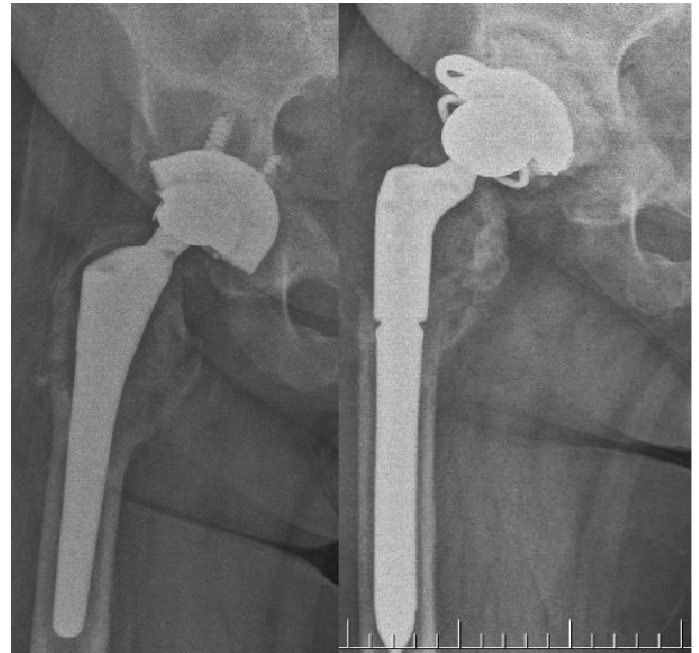

Figure 1: Preoperative and postoperative radiographs of the Case 1 revealing periprosthetic osteolysis and asymmetric thinning of the metal femoral head, also metal corpora libera originating from the metal head is lying adjacent to the lateral border of the head.

During the revision THA procedure significant metallosis and both acetabular and proximal femoral osteolysis was detected. (Figure 2) Hypertrophic tissue containing metal debris was removed, and synovectomy was performed as complete as possible. When we dislocated the hip joint we observed that there was severe asymmetrical wearing of the metal head exposing the deep border of the collum socket tip, and a coin like loose body originating from the chromium-cobalt head fits to the deep borders of the flute of the head in which the neck of the femoral prosthesis is plugged. The coin like loose body was floating free adjacent to the head laterally as seen on the preoperative radiographs. (Figure 3) After removal of the metal insert and the screws, the metal shell was easily removed from the osteolytic acetabulum (Figure 2). Gross bone loss detected in acetabulum. Although grossly stable, because of the significant bone loss proximally around the femoral component femoral bone-ingrowth was considered to be ineligible. After the joint debrided and lavaged with a pulstabil lavage system (Zimmer®, Warsaw, IN), the acetabular component was revised to a 54 mm cemented constrained polyethylene liner (BIOMET®, USA) after grafting with 150 cc allograft and metal cage implantation. Also, femoral component was revised to a modular, fully porous coated revision system with excellent distal fixation (ARCOS, BIOMET®, USA) composed of a stem with 16

mm diameter and 150 mm length and a proximal component with 16 mm diameter and 70 mm length. A standard 36 mm metal head was inserted. The functional and the radiological results of the revision operation are satisfactory to date from the point of both the patient and us. The patient returned to her daily activity without discomfort in the hip.

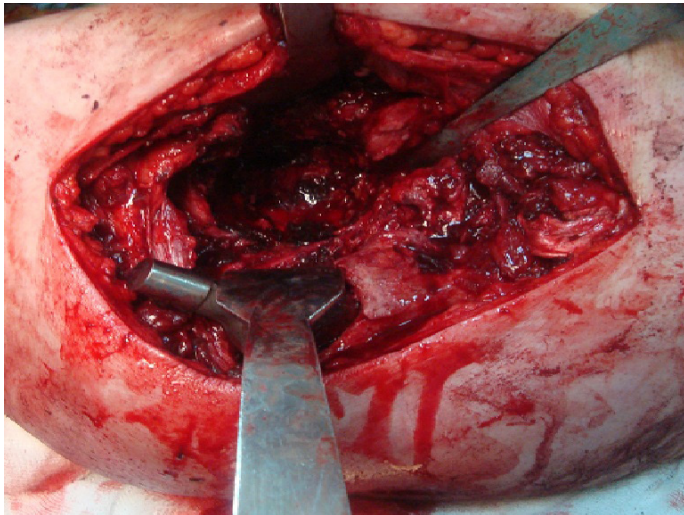


Figure 2: Intraoperative acetabular osteolysis and the metallosis.



Figure 3: Asymmetrical wear of the metal head and the coin like free fragment originating from the head.

Case 2

In May 2012, a 51-year-old male patient referred with progressive intermittent groin pain. He had a history of THA due to osteoarthritis related to bilaterally Perthes disease twelve years ago. He reported that the clinical results and function of the previous THA were satisfactory until March 2011, when he noticed an indefinite hip pain increasing during daily activity. He declared that the hip pain progressed rapidly and localized to groin.

The patient weighed 87 kg and was 178 cm tall. His systemic examination was normal. He had a positive trendelenburg sign and antalgic gait. The ROM of the hip was unrestricted but painful. Lower limb discrepancy was determined to be 1,5 cm. Results of complete blood count and biochemistry

was within normal range. Erythrocyte sedimentation rate was 13mm/h, whereas C-reactive protein level was 2,6 mg/dl. Serum chromium, cobalt, and molybdenum levels were 0.57 ng/mL, 0.34 µg/L and 1.76 µg/L, respectively. Preoperative radiographs revealed an uncemented THA with severe perioperative osteolysis around the acetabular component. (Figure 4)

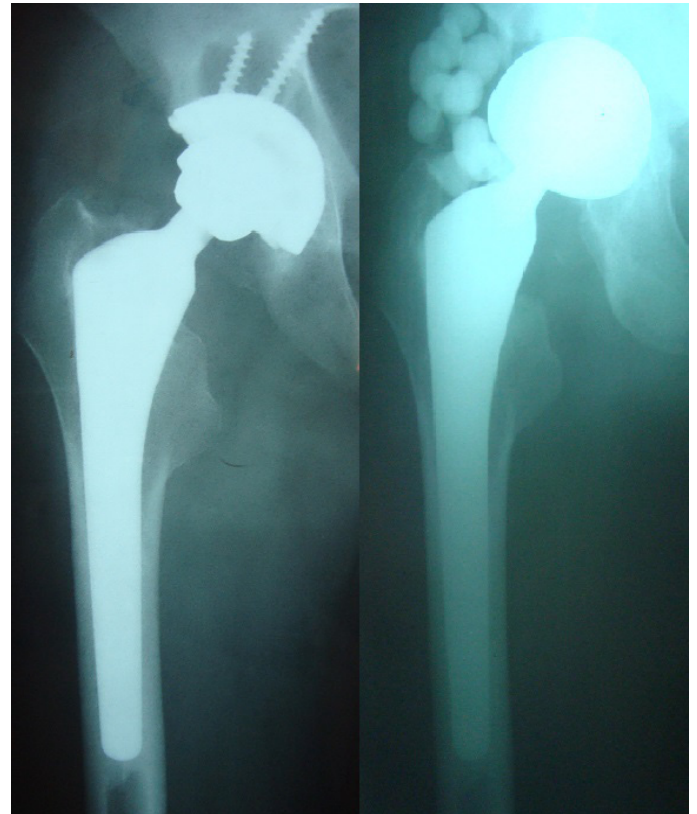

Figure 4: Preoperative and postoperative radiographs of the Case II revealing periprosthetic osteolysis.

During the revision THA procedure significant metallosis and peri-acetabular osteolysis was detected. Hypertrophic tissue containing metal debris and the synovium were removed. When we dislocated the hip joint we observed the dissociation of the metal head exposing the deep border of the colum socket tip, and a coin like loose body originating from the crom-cobalt head fits to the deep borders of the flute of the head in which the neck of the femoral prosthesis is plugged. The coin like loose body was residing in the deep space of the flute of the metal head. (Figure 5). After the removal of the acetabular component, joint debrided and lavaged, the femoral head was revised to a 56 mm bipolar head (BIOMET®, USA). The functional and the radiological results of the revision operation are satisfactory to date from the point of both the patient and us. The patient returned to her daily activity without discomfort in the hip.

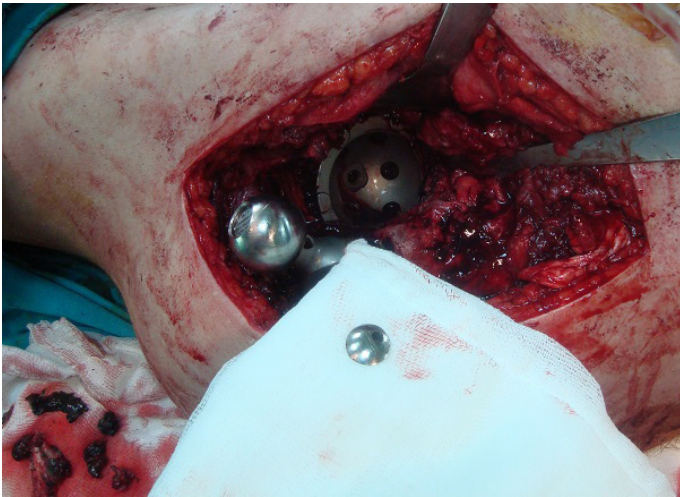

Figure 5: Intraoperative view of the metallozsis, the dissociation of the metal head and the coin like free fragment originating from the head.

Discussion

Metal on metal bearings were introduced in hip arthroplasty in order to overcome the problem of polyethylene wear and relevant complications [2,3], but total hip arthroplasty with metal on metal (MoM) bearing is still being discussed [3,4].

A comprehensive investigation and evolution on the subject of bearing surfaces including advancements in prosthesis wear properties is in progress. However, progressive wear of the components resulting in the failure of the implants is still present. Headwear is a well-known result of the MoM articulation and may present with instability, metallosis, pain and mechanical symptoms [5].

More than one million MoM arthroplasties were implanted worldwide till now [2]. Recent reports have recommended the discontinuance of MoM arthroplasties due to multiple side effects and complications [6]. Cobalt and chromium ion levels increase three to five times in MoM arthroplasties [2,6]. Patients can develop local reactions to the metal ions leading to pain, aseptic loosening, periprosthetic osteolysis and metal hypersensitivity [3,7]. A large number of adverse local tissue reactions associated with the metal debris generated from the bearing area or tapered junctions have been demonstrated [2,3,6]. Pseudotumors, aseptic lymphocyte-dominated vasculitis associated lesions (ALVAL) and squeaking are the miscellaneous concerns [2,3,6]. Nowadays there is no support for the advantage of MoM arthroplasties in the literature [2].

There are many reports about the fracture of the femoral components after total hip arthroplasty [1]. Also, there are numerous reports about the femoral head fractures in modular implants with ceramic heads [1]. Metal head fractures or dissociations are very rare. There is only one case report about the

fracture of the metal head in a non-modular femoral implant through the weld, which is known to be the site of the metal weakness, in the literature. But, to our knowledge there is no report about the modular head fracture due to catastrophic wear at the site of the collar socket tip deep border. These two cases are the first report on this subject. In both cases thinner head structure between the articular surface and the collar socket tip deep border associated with the implantation of -3 sized head and high activity level of the patients may be the probable cause of the head dissociation.

Conclusion

In conclusion, these two cases illustrate a very rare and extraordinary complication of MoM arthroplasties as catastrophic wear at the site of the deep border of the collar socket and coin like loose body originating from the chromium-cobalt head resulted with metallosis, osteolysis and failure and call attention to the possible head fracture risk of -3 head size use.

Declaration of conflict of interest

The authors received no financial support for the research and/or authorship of this article. There is no conflict of interest.

References

1. Giori N J. Unexpected finding of a fractured metal prosthetic femoral head in a nonmodular implant during revision total hip arthroplasty. *J Arthroplasty* 2010; 25: 13-15.
2. Lombardi AV Jr, Barrack RL, Berend KR, Cuckler JM, Jacobs JJ, Mont MA, Schmalzried TP. Algorithmic approach to diagnosis and management of metal-on-metal arthroplasty. *J Bone Joint Surg* 2012; 94: 14-18.
3. Gutman G, Hershkovich O, Amit Y, Israeli A. Catastrophic failure due to massive osteolysis of both acetabular and femoral component in a metal-on-metal hip arthroplasty: a demonstrative case report. *Eur J Orthop Surg Traumatol* 2013; 23: 225-28.
4. Shetty V, Shitole B, Shetty G, Thakur H, Bhandari M. Optimal bearing surfaces for total hip replacement in the young patient: a meta-analysis. *Int Orthop* 2011; 35: 1281-87.
5. Lanting BA, Springer BD. Catastrophic wear in total hip arthroplasty. Complete wear-through of a metal backed acetabular component: case report. *Orthop Clin N Am* 2012; 23 : 63-65.
6. Migaud H, Putman S, Combes A, Berton C, Bocquet D, Vasseur L, Girard J. Metal-on-metal bearing: Is the end of the line? We do not think so. *HSSJ* 2012; 8: 262-69.
7. Alaia MJ, Alan JD. Catastrophic failure of a metal-on-metal total hip arthroplasty secondary to metal inlay dissociation. *J Arthroplasty* 2011; 26: 1-5.