

## Amplatzer duct occluder II embedded by cook detachable coil like a sandwich to closure of residual patent ductus arteriosus

Rezidüel duktus arteriyozus kapatılması sırasında Cook detachable koil içine sandeviç gibi gömülen Amplatzer duktal oklüder II

Osman Başpınar<sup>1</sup>, Metin Kılıncı<sup>1</sup>, Ahmet İrdem<sup>1</sup>

<sup>1</sup>University of Gaziantep, Faculty of Medicine, Department of Pediatrics, Division of Pediatric Cardiology, Gaziantep

### Abstract

Transcatheter patent ductus arteriosus closure has developed standard clinical practice. We report a moderate patent ductus arteriosus in 10-year-old girl was closed with firstly Amplatzer duct occluder II and secondly the device was embedded by a Cook detachable coil because of ductal recanalization. This case report demonstrates that to apply this combination in children is feasible and safe.

**Keywords:** Amplatzer duct occluder II; Cook detachable coil; patent ductus arteriosus; recanalization

### Özet

Transkater patent duktus arteriyozus kapatılması standart bir klinik uygulamadır. Sunumumuzda 10 yaşında bir kız hastanın orta büyüklükteki patent duktus arteriyozusu önce Amplatzer duktal oklüder II kapatılmıştır sonrada rekanalizasyon nedeni ile cihaz Cook detachable koil içine gömülmüştür. Bu vaka sunumu çocuklarda bu kombinasyonun mümkün ve güvenli olduğunu göstermektedir.

**Anahtar kelimeler:** Amplatzer duktal oklüder II; Cook detachable koil; patent duktus arteriyozus; rekanalizasyon

### Introduction

Transcatheter closure of patent ductus arteriosus (PDA) has developed into standard clinical practice with different devices (1). The procedure has rare complications, one of which is residual shunt (2,3). We report a case where misjudgment of PDA size because of interesting early recanalization of the ductus. And so, both of the Amplatzer duct occluder II (ADO II, AGA Medical Corporation, Golden Valley, Minnesota) and Cook detachable coils (Cook Cardiology, Bloomington, Indiana) was used to achieve closure of the ductus.

### Clinical Presentation

A 10-years old asymptomatic girl was referred to our hospital with the diagnosis of PDA. Echocardiography suggested the presence of a moderate PDA. The right anterior oblique aortography was confirmed type A PDA, the pulmonary end 2.3 mm, the aortic end 12.5 mm and the length was 14 mm (Fig.1a). The shunt ratio was 1.5:1, the mean pulmonary artery pressure was 35 mmHg. ADO II device was selected according to device sizing recommendations based on the measured diameter and the ductal length from the pulmonary artery to the ampulla. The ductus was occluded with a 3 mm / 4 mm ADO II device with retrograde way. Control angiography demonstrated that the device was in correct position and there was a trivial residual leak (Fig.1b). Follow-up echocardiogram next day revealed moderate residual flow, but the occluder was still in correct position. The patient was not given any medical therapy

was not given to the patient. We decided to wait for thrombus formation around the device.

Four months later, the patient still had a large left to right shunt at the clinical and echocardiographic evaluation. The second angiography demonstrated a moderate shunt between the caudal wall of the PDA and the device because of possible early recanalization of ductus. The distance was 2.2 mm, but surprisingly the device was still in stable position (Fig. 2a). A big Cook detachable PDA coil (size 8 mm - 4 cm) was placed at the ductus with retrograde approach, proximal part of the device, 1.5 loop was placed at the before of ADO II device, and distal loops of coil was placed after of the ADO II device like a sandwich (Fig. 2b). Echocardiography 24 hours after the procedure revealed complete occlusion of the defect.

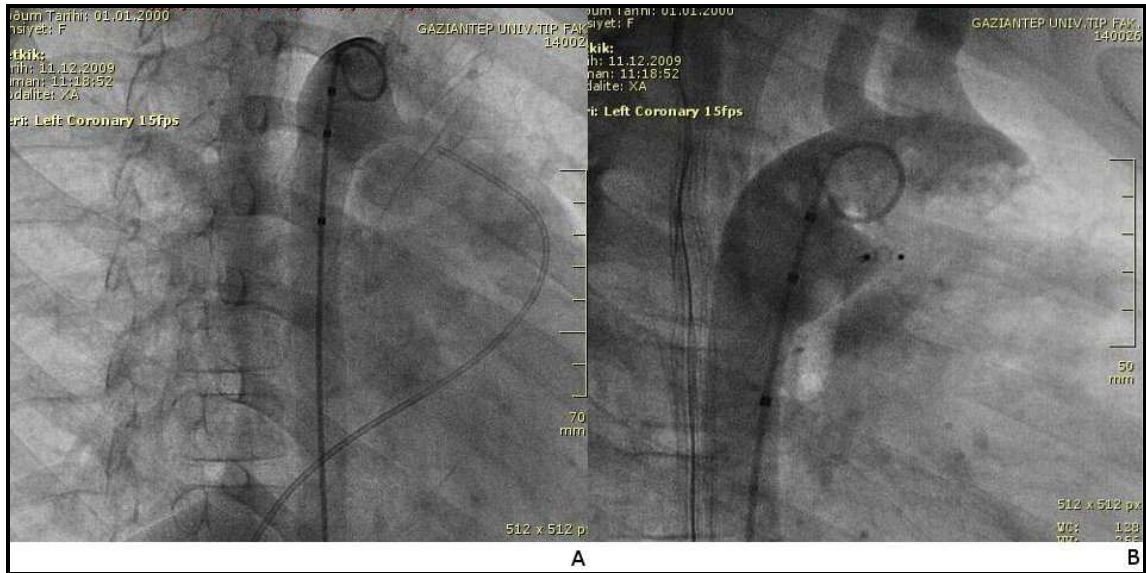
### Discussion

Transcatheter PDA closure is a safe and effective treatment. The choice of device and technique is determined by the cost, familiarity of the operator with the different approaches, and the anatomic characteristics of the PDA (4,5). Reopening of PDA after successful coil occlusion has been reported by Turner and Daniels et al. (2,6). Also, PDA is a labile vascular structure and can spasm, leading to rapid changes in size and difficulty in sizing of devices for closure. We hypothesize that the changes in size of the PDA was due to the possible recanalization or maybe due to spasm. Although ADO II device was in stable position, there was caudal leak at the distal part of the ADO II device.

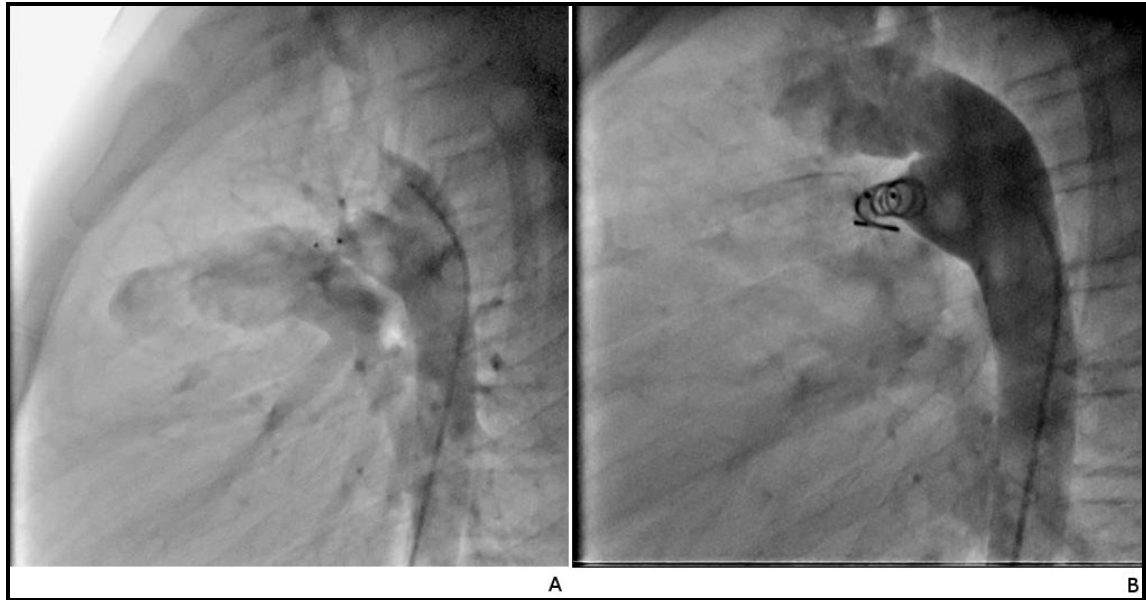**İletişim/Correspondence to:** Osman Başpınar, University of Gaziantep, Faculty of Medicine, Department of Pediatrics, Division of Pediatric Cardiology, Gaziantep, TURKEY  
Tel: +90 532 345 54 77 [osmanbaspinar@hotmail.com](mailto:osmanbaspinar@hotmail.com)

It might be difficult to advance the delivery catheter to the ideal point for its placement. In our case, to decrease the risk of migration, the ADO II device was passed with delivery catheter and embedded by Cook detachable coils. This is the second case that residual shunts after ADO II device closed with another coil. At the first case report, Nit-Occlud System (PFM, Cologne,

Germany) was used because of ADO II aortic retention disk kinking (7). This is the first ADO II and Cook detachable coil combination. This case report demonstrates that applying this combination in children is feasible and safe.



**Figure 1.** a) At the right anterior oblique view, aortogram demonstrating that type A patent ductus arteriosus, b) with closed a Amplatzer duct occluder type II.



**Figure 2.** a) At the lateral view, Amplatzer duct occluder II is still in stable position, but there was a moderate residual patent ductus arteriosus leak at the distal of the device. b) Amplatzer duct occluder II embedded by a big Cook detachable coil like a sandwich.

### References

1. Moore JW, Levi DS, Moore SD, Schneider DJ, Berdjis F. Interventional treatment of patent ductus arteriosus in 2004. *Catheter Cardiovasc Interv* 2005;64(1):91-101.
2. Turner DR, Forbes TJ, Epstein ML, Vincent JA. Early reopening and recanalization after successful coil occlusion of the patent ductus arteriosus. *Am Heart J* 2002;143(5):889-93.
3. Ovaert C, McCrindle BW, Nykanen D, Freedom RM, Benson LN. Transcatheter management of residual shunts after initial transcatheter closure of a patent arterial duct. *Can J Cardiol* 2003;19(13):1493-7.
4. Hofbeck M, Bartolomaeus G, Buheitel G, Esser R, Gravinghoff L, Hoffmann W, et al. Safety and efficacy of interventional occlusion of patent ductus arteriosus with detachable coils; a multicentre experience. *Eur J Pediatr* 2000;159(5):331-7.
5. Forsey J, Kenny D, Morgan G, Hayes A, Turner M, Tometzki A, et al. Early clinical experience with the new Amplatzer

- 
- ductal occluder II for closure of the persistent arterial duct. Catheter Cardiovasc Interv 2009;74(4):615-23.
6. Daniels CJ, Cassidy SC, Teske DW, Wheller JJ, Allen HD. Reopening after successful coil occlusion for patent ductus arteriosus. J Am Coll Cardiol 1998;31(2):444-50.
  7. Beck C, Laser KT, Haas NA. Failure of the Amplatzer Ductal Occluder II; Kinking of the aortic retention disk at 24 hours. Catheter Cardiovasc Interv 2010;75(7):1100-3.