

Kimura's disease an unusual cause of lymphadenopathy in a nephrotic syndrome child

Nefrotik sendromlu bir çocukta lenfadenopatinin olağandışı nedeni olarak Kimura hastalığı

Chenthilnathan Periasamy¹, Norzalina Zawawi², Md Salzihan Md Salleh², Baharudin Abdullah¹

¹Universiti Sains Malaysia, School of Medical Sciences, Department of Otolaryngology-Head and Neck Surgery, Kubang Kerian, Kelantan

²Universiti Sains Malaysia, School of Medical Sciences, Department of Pathology, Kubang Kerian, Kelantan

Abstract

Kimura's disease is a rare, benign, chronic inflammatory disorder of unknown etiology which is endemic in Orientals. The disease is characterized by a triad of painless subcutaneous nodule in the head and neck region, blood eosinophilia and elevated serum immunoglobulin E (IgE) levels. Kimura's disease has various synonyms such as eosinophilic lymphogranuloma, inflammatory angiomatous nodule and atypical pyogenic granuloma. Renal pathology such as nephrotic syndrome has been found to be associated with Kimura's disease which states a common etiopathogenesis between renal lesion and Kimura's disease. We present an eleven years old Malay boy with recurrent nephrotic syndrome presented with left post auricular swelling. The diagnosis was based on the characteristic histopathology findings after surgical biopsy as Kimura's disease.

Keywords: Immunoglobulin E; Kimura's disease; lymphadenopathy; nephrotic syndrome; peripheral eosinophilia

Özet

Kimura hastalığı, doğuda endemik olan etyolojisi bilinmeyen nadir, benign, kronik inflammatuar bir hastalıktır. Hastalık, baş ve boyun bölgesinde ağrısız subkütanöz nodül, eozinofili ve yüksek serum immunoglobulin E (IgE) düzeyleri üçlüsü ile karakterizedir. Kimura hastalığının, eozinofilik lenfogranuloma, inflammatuar anjiomatöz nodül ve atipik pyojenik granuloma gibi çeşitli sinonimleri vardır. Kimura hastalığı ve renal lezyon arasında ortak etyopatogenezi oluşturan nefrotik sendrom gibi renal patoloji Kimura hastalığı ile birlikte bulunur. Biz, sol kulak arkası şişliği olan tekrarlamalı nefrotik sendromlu 11 yaşında Malezya'lı bir erkek çocuğu sunuyoruz. Diyagnoz, cerrahi biyopsi sonrasındaki karakteristik histopatoloji bulgularına dayanarak Kimura hastalığı idi.

Anahtar kelimeler: Immunoglobulin E; Kimura hastalığı; lenfadenopati; nefrotik sendrom; periferik eozinofili

Introduction

Kimura's disease (KD) is a rare chronic inflammatory disease which was first described in China by Szeto in 1937, and later reported by Kimura in Japan 1948 (1). The etiology of KD is unknown and thought to be a disease that affected only Orientals but also occurs sporadically in Caucasians. Males are affected more than females and most cases occur in the second and third decades of life (1).

KD has a typical clinical presentation which is characterized by subcutaneous mass, mainly in the head and neck with regional lymphadenopathy, raised serum eosinophil counts and elevated serum immunoglobulin E (IgE) levels (2). Histologically, the lesions are characterized by proliferating blood vessels and eosinophilic infiltration (2).

Clinically, KD consists of painless large either solitary or multiple nodules in the subcutaneous of the head and neck mainly in the preauricular and submandibular region. It is a chronic benign disease which can be

misdiagnosed for malignant disease (3). KD seldom resolves spontaneously and malignant transformation has not been reported to date. However, early diagnosis of the disease could prevent unnecessary diagnostic procedure (4).

Renal involvement is the only systemic manifestation. Renal lesion such as proteinuria and nephrotic syndrome have been associated with Kimura's disease (5,6). A steroid-responsive nephrotic syndrome has shown reduction in the size of the subcutaneous mass with steroids implying a common etiopathogenesis of the renal lesion and Kimura's disease (7,8).

A definite diagnosis of KD is based on histological characteristics such as preserved nodal architecture, reactive germinal centre, eosinophil proliferation of post capillary venules which was different from the angiolymphoid hyperplasia with eosinophilia (9,10). This disease has predilection for Asian young male and may mimic neoplasm (9). This is the first reported case of Kimura's disease associated with nephrotic syndrome in a pediatric patient from our subcontinent.

İletişim/Correspondence to: Baharudin Abdullah, Department of Otolaryngology-Head and Neck Surgery, School of Medical Sciences, Universiti Sains Malaysia, 16150 Kubang Kerian, Kelantan, MALAYSIA
Tel: +6 0976 76416 baharudin@kb.usm.my

Received: 31.12.2011 **Accepted:** 05.02.2012
Geliş Tarihi: 31.12.2011 **Kabul Tarihi:** 05.02.2012

DOI: 10.5455/GMJ-30-2012-71
www.gantep.edu.tr/~tipdergi
ISSN 1300-0888

Case Report

An 11 years old Malay male child presented to Otorhinolaryngology clinic with the complaints of left post auricular swelling for the past two years. He was also diagnosed as nephrotic syndrome since the age of 2 years old and was under pediatric follow up. He has history of relapse episodes of nephrotic syndrome and was steroid dependant.

Initially, the swelling was small bead size located behind the ear and was asymptomatic. Suddenly, the swelling increased gradually to attain the present size in two years duration. There was no history of fall, trauma, infection or constitutional symptoms such as fever, night sweats, fatigue and loss of weight. The swelling was painless and no other systemic symptoms such as otalgia, otorrhea and no history of contact with pulmonary tuberculosis.

On clinical examination, he was averagely built and well nourished. There was a swelling measuring about 6x4 cm located at the left post auricular area. The swelling was firm, lobulated, non tender and displaced the pinna anteriorly. Furthermore, the swelling was not adhered to the mastoid region and had normal overlying skin. There were also enlarged and mobile lymph nodes at the left neck level II, III and V (the largest measuring 2x2 cm). Other systemic examination was unremarkable and there was no hepatosplenomegaly.

A full blood investigation was done and demonstrated a rise in white cell count of $19.5 \times 10^9/l$ with an increased differential count of 50% of eosinophils. His renal profile result was within normal limits and his urine analysis result was also normal.

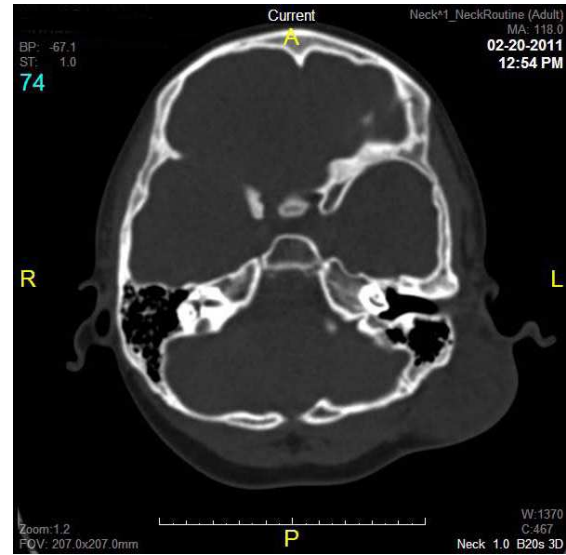


Figure 1. Axial view CT scan of neck shows a well defined heterogenous lesion at the left posterior auricular region.

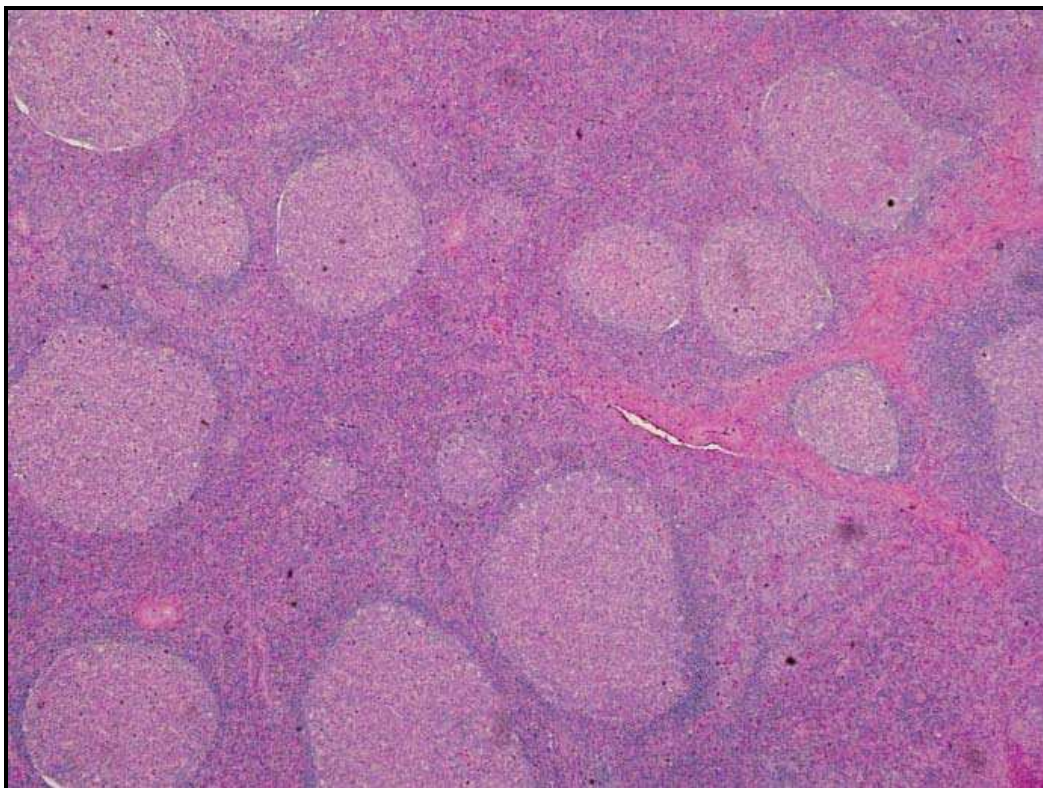


Figure 2. The lymph node exhibit reactive follicular hyperplasia which is composed of numerous and enlarged follicles in variable size and shape with prominent germinal centre. The mantle zone is well-demarcated.

The immunoglobulin (Ig) E concentration was markedly increased. Fine needle aspiration cytology showed reactive lymphoid hyperplasia.

CT scan from base of skull until the neck demonstrated a well defined mass at the left posterior auricular region measuring 2.8x5.0x4.9 cm. The mass was heterogeneously enhanced lesion extending from the level of upper border of left pinna till the lower border of left pinna (Figure1). The external auditory canal was

patent. It had poor fat plane with the underlying left sternocleidomastoid muscle but clear fat plane was seen with the left parotid gland. Both submandibular and parotid glands were normal bilaterally. The vocal cord was normal. No evidence of bony erosion was seen. The scan also showed multiple bilateral lymph nodes enlargement with the largest lymph node on the left posterior cervical region measuring 1.6x0.9 cm. No lytic or sclerotic bone lesion detected.

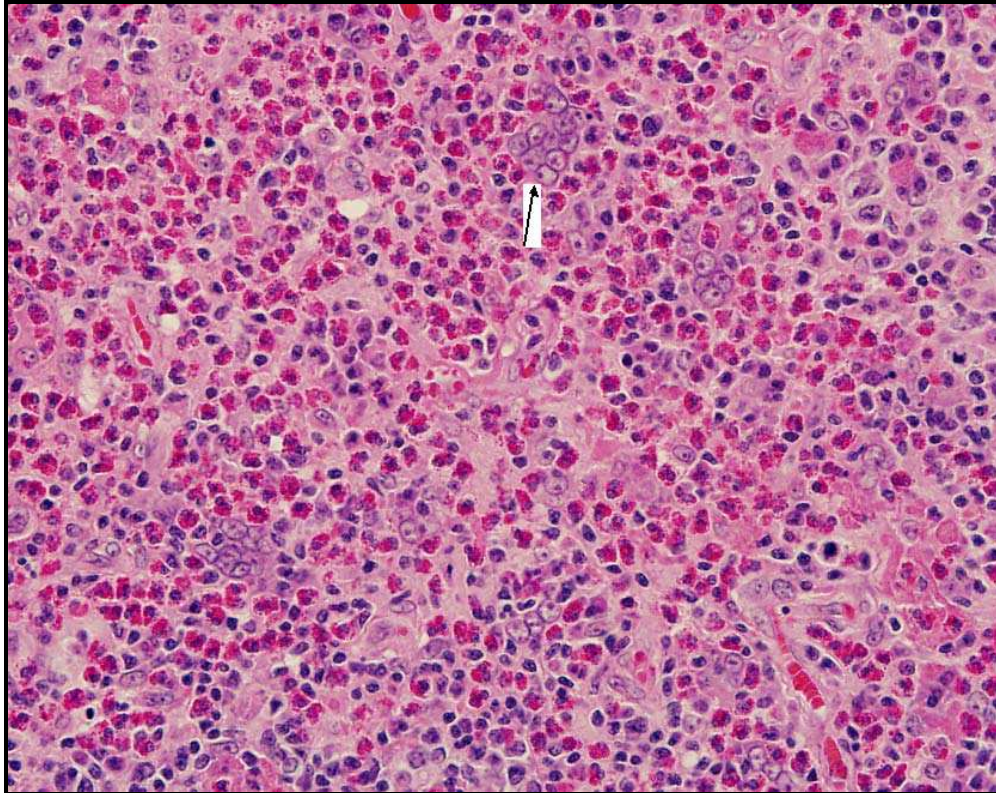


Figure 3. Polykaryocytes of Warthin-Finkeldey type are seen within the germinal centre. These cells are characterized by overlapping and grape-like arrangement of nuclei (arrow).

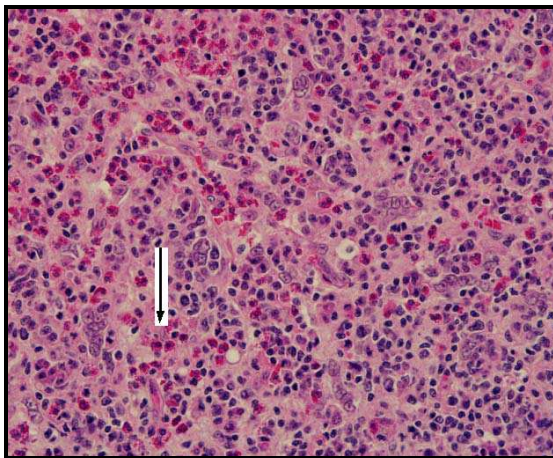


Figure 4. Diffuse eosinophilic infiltration (arrow-eosinophil).

The patient underwent excisional biopsy under general anesthesia. Intra-operatively the swelling was completely removed with no complication.

The histopathological report showed hyperplastic follicles with prominent germinal centers and abundant eosinophilia infiltration into the germinal centre with thin wall capillaries (Figures 2-4). There was diffuse and marked eosinophilic infiltration seen within the lymph nodes. Polykaryocytes were seen within the germinal centres. Eosinophilic microabscesses with vascular channels hyperplasia were also present. These findings were consistent with Kimura's disease. The biopsy did not reveal any malignant cells. Serological tests for human immunodeficiency virus, *Toxoplasma gondii*, Rubella, *Cytomegalovirus*, Filariasis, *Trichinella spiralis*, *Toxacara canis* and *Trypanosoma cruzi* were negative.

Discussion

Kimura's disease is now well known as one of the benign cause of painless localized lymphadenopathy in Asians and is apparent at any age but has mostly been reported in the second and third decades of life. The disease involves subcutaneous tissues, major salivary gland, lymph nodes mainly in the head and neck region (3). The most common clinical features of Kimura's disease are painless unilateral soft-tissue mass, blood eosinophilia and an increased level of serum IgE (1-3). KD has predilection for the scalp and the periauricular area, but less commonly seen at axillary, inguinal and epitrochlear lymph nodes (11).

KD is a distinct reactive process. It may mimic an inflammatory or neoplastic lesion (12). KD has a high frequency of an association with nephrotic syndrome. Reported cases of nephrotic syndrome and KD commonly seen in adult, but only 5 children was mentioned (13). The renal involvement is proliferative glomerulonephritis and marginal proliferative glomerulonephritis which also caused nephrotic syndrome in up to 60% of patients (14).

The etiology of KD is unknown. The postulated causes are trauma, autoimmune reaction and allergic reaction to parasite, virus, fungus or toxin. The presence of peripheral eosinophilia and an increased IgE level suggest an abnormal T-cell stimulation to a hypersensitivity reaction. The pathophysiology of KD could be a disturbance in the production of eosinophils and IgE which is an interaction between type 1 and 2 T helper cells (14). KD and renal lesion have an association in the form of proteinuria and nephrotic syndrome. The elevated serum IgE, lymph node proliferation and eosinophilia could all account for glomerulopathy. IgE deposits into glomerular capillary will cause epithelial damage in renal glomerular resulting in proteinuria (14). Proteinuria can occur either simultaneously or months following the onset of the tumor. A number of glomerular lesions on renal biopsy have shown that membranous glomerulonephritis is the commonest one. It has been proposed that a common etiological factor such as a viral infection or toxin could alter T-cell immunoregulation or induce an IgE mediated type-1 hypersensitivity reaction, resulting in the release of lymphokines producing both the proteinuria and timorous aggregation of lymphocytes and eosinophils (15).

Histologically, lymphoid follicles and abundant eosinophilic infiltration are characteristic features (Fig. 4). Absence of epithelial endothelial cells in the blood vessels and infiltrating the follicular germinal centers are well distinguished between Kimura's disease and angiolymphoid hyperplasia with eosinophilia (ALHE). ALHE affects all races, causes more superficial dermal involvement and systemic manifestations are uncommon (15). Several diseases may mimic KD and the differential diagnosis should include ALHE, tuberculosis, hamartoma and epithelioid hemangioma.

Computed tomography (CT) scan has been useful in delineating the lesion from the surrounding structures and also to note the extent of the lesion before any surgical procedure. Histopathology by surgical biopsy is the best mean of diagnosis with support of blood investigation.

If these mass are left untreated, they tend to slowly enlarge and become disfiguring, as seen in our patient. The prognosis of KD is good and no malignant transformation has been reported. There have been reports of recurrence in 15 to 40% of cases even after surgical excision which can be due to poor demarcation of tumor borders of KD and adjunctive frozen section may be useful (16).

Management option ranges from conservative observation for asymptomatic patients to surgical excision, steroid therapy or radiotherapy for symptomatic patients. Surgical excision of the lesion is the first line therapy but relapses are frequent. Systemic corticotherapy with prednisolone is given for relapsing forms and cases with renal involvement. There is risk of relapse when treatment is withdrawn. Radiation therapy is stated for lesions refractory to steroid therapy or when surgery is not possible.

In conclusion, Kimura disease is a rare indolent, chronic inflammatory benign disorder characterized by soft tissue tumor like lesion with lymphadenopathy in head and neck region. KD mimics a number of benign and neoplastic diseases of head and neck region which poses a diagnostic challenge in their management. It has high affinity and association with nephrotic syndrome. KD should be considered in the differential diagnosis of patient with any head and neck mass, peripheral hypereosinophilia and an underlying renal pathology.

The above patient with post auricular mass with nephrotic syndrome responded well with steroid treatment and still under Otorhinolaryngology clinic follow-up. Surgery is still the treatment of choice as it can be both diagnostic and therapeutic as compared with other modalities.

References

1. Goldenberg D, Gatot A, Barki Y, Leiberman A, Fliss DM. Computerized tomographic and ultrasonographic features of Kimura's disease. *J Laryngol Otol* 1997;111(4):389-91.
2. Kung IT, Gibson JB, Bannatyne PM. Kimura's disease: a clinico-pathological study of 21 cases and its distinction from angiolymphoid hyperplasia with eosinophilia. *Pathology* 1984;16(1):39-44.
3. Ranka SR, Rajput A, Kantharia CV. Kimura's disease. A Case Report. *Indian J Otolaryngol Head Neck Surg* 2004;56(1):43-5.
4. Yuen HW, Goh YH, Low WK, Lim-Tan SK. Kimura's disease: a diagnostic and therapeutic challenge. *Singapore Med J* 2005;46(4):179-83.
5. Matsuda O, Makiguchi K, Ishibashi K, Chida Y, Ida T, Matsuda K, et al. Long-term effects of steroid treatment on nephrotic syndrome associated with Kimura's disease and a review of the literature. *Clin Nephrol* 1992;37(3):119-23.
6. Yamada A, Mitsuhashi K, Miyakawa Y, Kosaka K, Takehara K, Iijima M, et al. Membranous glomerulonephritis associated with eosinophilic lymphfolliculosis of the skin (Kimura's disease): report of a case and review of the literature. *Clin Nephrol* 1982;18(4):211-5.

7. Whelan TV, Maher JF, Kragel P, Dysart N, Dannenhoffer R, Prager L. Nephrotic syndrome associated with Kimura's disease. *Am J Kidney Dis* 1988;11(4):353-6.
8. Atar S, Oberman AS, Ben-Izhak O, Flatau E. Recurrent nephrotic syndrome associated with Kimura's disease in a young non-Oriental male. *Nephron* 1994;68(2):259-61.
9. Chen H, Thompson LD, Aguilera NS, Abbondanzo SL. Kimura disease: a clinicopathologic study of 21 cases. *Am J Surg Pathol* 2004;28(4):505-13.
10. Kuo TT, Shih LY, Chan HL. Kimura's disease. Involvement of regional lymph nodes and distinction from angiolymphoid hyperplasia with eosinophilia. *Am J Surg Pathol* 1988;12(11):843-54.
11. Gumbs MA, Pai NB, Saraiya RJ, Rubinstein J, Vythilingam L, Choi YJ. Kimura's disease: A case report and literature review. *J Surg Oncol* 1999;70(3):190-3.
12. Deshpande AH, Nayak S, Munshi MM, Bobhate SK. Kimura's disease. Diagnosis by aspiration cytology. *Acta Cytol* 2002;46(2):357-63.
13. Chartapisak W, Opastirakul S. Steroid-resistant nephrotic syndrome associated with Kimura's Disease. *Am J Nephrol* 2002;22(4):381-4.
14. Asma A, Maizatun AA. Kimura's disease: an unusual cause of cervical tumor. *Med J Malaysia* 2005;60(3):373-6.
15. Sud K, Saha T, Das A, Kakkar N, Jha V, Kohli HS, et al. Kimura's disease and minimal-change nephrotic syndrome. *Nephrol Dial Transplant* 1996;11(7):1349-51.
16. Shahrul H, Baharudin A, Effat O. Kimura's disease in Malay patients. *Med J Malaysia* 2007;62(3):263-4.