

Comparison of 4% icodextrin and auto-crosslinked hyaluronic acid gel in terms of efficacy and cost effectivity in preventing postoperative abdominal adhesions

Ameliyat sonrası abdominal yapışıklıkların önlenmesinde %4 icodextrin ile auto-crosslinked hyaluronic asit jel'in etkinlik ve maliyet yönünden karşılaştırılması

İlyas Başkonuş¹, Göktürk Maralcan¹, Avni Gökcalp¹, Ersin Borazan¹, Hüseyin Ağtaş¹

¹University of Gaziantep, Faculty of Medicine, Department of General Surgery, Gaziantep

Abstract

This experimental study was designed to compare the effects and costs of 4% icodextrin and hyaluronic acid in intraabdominal adhesion formation in rats. This study included 30 healthy Wistar albino rats, each weighing 250-300 gr. Following cecal-ileal abrasion to rats in each group, the following treatments were applied: Group 1 (control, n:10) 5 ml saline irrigation; Group 2 (n:10) 5 ml 4% icodextrin solution; Group 3 (n:10) 3 ml auto-crosslinked hyaluronic acid gel. After 14 days, following a second operation, adhesion intensity scoring, histopathological assessment (inflammation, fibrosis) and costs were compared between groups. The lowest postoperative adhesion intensity score was found in the group 3 and the highest score was found in the group 1 (p=0.028). Group 3 had a non-significantly lower adhesion intensity score than group 2 (p>0.05). In terms of inflammation and fibrosis, group 2 had the lowest score, but there were no significant differences between all the groups (p>0.05). In terms of cost, 4% icodextrin is less expensive than hyaluronic acid. The results demonstrated that both hyaluronic acid and 4% icodextrin are similarly effective in reducing postoperative intraabdominal adhesions. In addition, 4% icodextrin is more cost-effective, which can be an advantage for clinical studies.

Keywords: Adhesion; costs; hyaluronic acid; icodextrin.

Özet

Bu deneysel çalışmada intraabdominal yapışıklıkta %4 icodextrin ve hyaluronik asitin etkinliği ve maliyetinin karşılaştırılması planlandı. Bu çalışmaya her biri 250-300 gr. 30 sağlıklı Wistar albino ratlar alındı. Her grupta ratlara çekal-ileal abrazyonu takiben: Grup1 (kontrol n:10) 5 ml saline irrigasyon; Grup 2 (n:10) 5 ml %4 icodextrin solüsyonu; grup 3 (n:10) 3ml auto-crosslinked hyaluronik asit jel uygulandı. 14 gün sonra ikinci bir ameliyatı takiben gruplar arasında yapışıklık skorlaması, histopatolojik değerlendirme (inflamasyon, fibrozis) ve maliyetler karşılaştırıldı. En düşük ameliyat sonrası yapışıklık skorlaması Grup 3'te, en yüksek grup 1'de bulundu (p:0.028). Grup 3, grup 2'den belirgin olmayacak şekilde daha düşük yapışıklık skorlamasına sahipti (p>0.05). İnflamasyon ve fibrozis açısından grup 2 en düşük skora sahipti. Ancak tüm gruplar arasında anlamlı farklılık yoktu (p>0.05). Maliyet yönünden %4 icodextrin hyaluronik asitten daha ucuzdu. Bulgular hem hyaluronik asit hem de icodextrinin ameliyat sonrası intraabdominal yapışıklıkları azaltmada benzer etkinlikte olduğunu gösterdi. Ek olarak %4 icodextrinin klinik çalışmalar için avantajlı olabilecek şekilde maliyeti daha düşüktü.

Anahtar kelimeler: Adezyon; icodextrin; hyaluronik asit; maliyet.

Introduction

Postoperative adhesion is diagnosed in many cases. Many researchers have investigated the reasons and means of preventing intraabdominal adhesions which cause many morbidities. After abdominal operations, the probability of developing intraabdominal adhesions varies between 67-93% (1,2).

In intraabdominal operations, appropriate surgical technique, minimally invasive surgery, less trauma on tissues, extensive drying and prevention of warming and minimum usage of sutures can be effective in preventing abdominal adhesions. In addition to these precautions, there are many studies of suitable pharmacologic agents as heparin, aprotinin, colchicine, cellulose, gelatin. Despite many previous studies, there is no standard method to prevent postoperative intraabdominal adhesions (3).

Many studies have investigated the use of adhesion barriers. One new product intended to function as an

anti-adhesive barrier is auto-crosslink (its molecules are activated with each other) 100% pure hyaluronic acid gel (HA). It is stated that application of this gel prevents adhesion of damaged tissues by physical differentiation during the peritoneal healing phase. Also, by day 7 postoperatively, it is absorbed by reabsorption in the peritoneal cavity and by day 28 it is completely biodegraded from the body (4-6). The efficiency of HA in prevention of intraabdominal adhesions has been shown by clinical and experimental studies (4,7-10). However, the high cost of the product remains a potential consideration.

One of the polymeric solution 4% icodextrin (ID) also prevents adhesion formation. The icodextrin functions by temporarily separating peritoneal surfaces through hydroflotation. It persists for several days in the peritoneal cavity and is slowly absorbed by the lymphatic system into the systemic circulation, where it is broken down by amylase and metabolized to glucose (11). Several experimental and clinical studies have demonstrated the efficacy of ID in reducing postsurgical adhesion formation (11-15). In addition to these positive findings, the cheapness of the product is an advantage.

İletişim/Correspondence to: Ersin Borazan, University of Gaziantep, Faculty of Medicine, Department of General Surgery, Gaziantep TURKEY
Tel: + 90 342 360 3928 ersinborazan@hotmail.com

Received: 31.07.2012 **Accepted:** 12.11.2012
Geliş Tarihi: 31.07.2012 **Kabul Tarihi:** 12.11.2012

DOI: 10.5455/GMJ-30-2012-119
www.gantep.edu.tr/~tipdergi
ISSN 1300-0888

Despite their advantages, these products are relatively expensive in many countries, and so the availability of cheaper products is of great importance.

The aim of this study is to compare the use of ID and HA in terms of their efficiency and economic costs.

Material and Methods

This study was performed in the Animal Research Laboratory of Gaziantep University. Approval was obtained from the Animal Experiments Local Ethical Committee of Gaziantep University before the study (07.12.2009/ No:12.2009-14). A total of 30 male Wistar-Albino rats (average weight 250-300gr) were included in the study. Animals were kept in cages under standard laboratory conditions with a balanced pellet diet and sufficient water. After adaptation, they were randomly assigned into one of three groups. The surgical procedures were performed under semi-sterile conditions. For anesthesia, the animals received 30mg/kg of ketamine hydrochloride (Ketalar®) intraperitoneally and intramuscular 10 mg/kg of xylazine (Rompun®).

Formation of Adhesions

The abdomen was cut via a midline incision. The cecum and ileum protruded through the incision and were each abraded over a total area of 5 cm² using a toothbrush. Following the cecum-ileum abrasion, animals were divided into three groups and were administered 5 ml saline irrigation (group 1, control), 5 ml ID (group 2, Adept®) or 3 ml HA (group 3, Hyalobarrier gel®) into the peritoneal cavity. The abdomen was then closed by a running suture of 3/0 polypropylene.

Evaluation of Adhesion Formation

After 14 days, rats were sacrificed by cervical dislocation. The abdominal wound was opened with a reversed U-shape incision. We used a scoring system to evaluate adhesions. Evaluation was carried out by two independent observers. Peritoneal adhesion was recorded according to the Mazuji classification (16). The extent of the adhesions was scored according to the chart presented in Table 1. All the data for each animal were recorded on special cards.

Table 1. Adhesion grades according to Mazuji classification.

Adhesion Grade	Description of grade
0	No adhesion
1	Very small, irregular adhesion
2	Easily separable medium intensity adhesion
3	Intense, not easily separable regular adhesion
4	Very intense, not easily separable, homogeneous adhesion

Histopathological Examination

Adhesion-carrying tissues were excised en bloc and fixed in 10% formaldehyde, then embedded in paraffin wax. Sections 5µm thick were stained with hematoxylin and eosin, and the structure of the adhesions was examined by light microscopy. The samples were evaluated blindly by the same pathologist to evaluate the

presence of inflammation and fibrosis (Score 0: absent, mild. Score 1: moderate, severe).

Cost Analysis

The cost of %4 icodextrin was based on the cost of 1500 ml Adept® solution. Similarly, the cost of 3 ml auto-crosslinked hyaluronic acid gel was based on the cost of 10ml hyalobarrier gel®. The costs of group 2 and group 3 were compared.

Statistical Analysis

Analysis of Variance (ANOVA) and chi-square test were used to compare the formation of adhesions among the groups. Inflammation and fibrosis were assessed with the chi-square test. Statistical analysis was planned to compare the costs between the groups.

Results

No animals died during the study and there was no incidence of intraabdominal abscess.

Adhesions

Adhesions occurred between the abdominal visceral organs and incision. The brushed caecum - ileum wall were mostly effected. In addition, there were also adhesions to incision among the omentum, small intestine and liver. Adhesion grades of the groups are presented in Table 2. According to ANOVA test, there were significant differences in adhesion grades between groups (p=0.034). There were no grades 3 and 4 adhesions within groups 2 and 3. In comparing adhesion grades, a significant difference was found between group 1 (Fig.1) and group 3 (Fig.2) (p=0.028). Similarly, a significant difference was found between group 1 and group 2 (p=0.049). Although adhesion formation scoring was higher in group 2 than group 3, the difference was non-significant (p>0.05). In addition, with Chi-square test performed between the group 2 and group 3, there was no statistical difference (p>0.05) by the means of scores of adhesion grades. Then the control group compared with group 2 and group 3 in the same manner, using Chi-Square test. There was statistically difference between the control group and other two groups (p<0.05).

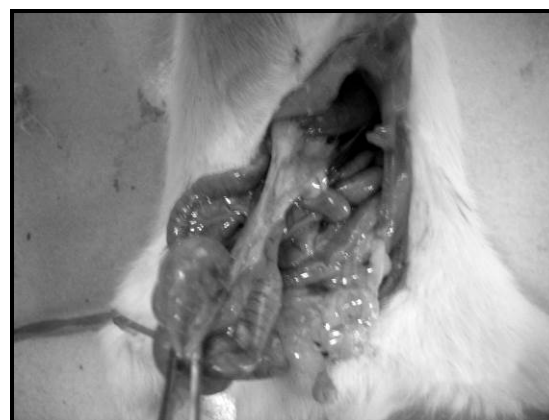

Figure 1. The view of adhesion formation from a Group 1 rat.

Table 2. Results of adhesion grade according to the groups.

Adhesion Grade	Group 1 (control) n=10	Group 2 (icodextrin) n=10	Group 3 (hyaluronic acid) n=10
0	1	2	2
1	1	4	5
2	5	4	3
3	2	0	0
4	1	0	0

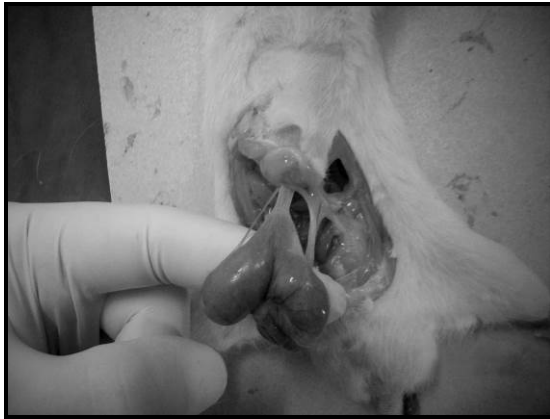

Figure 2. The view of adhesion formation from a group 3 rat.

Histopathology

The histological findings of adhesions did not differ significantly between the control group and treatment groups with respect to fibrosis and inflammation ($p>0.05$). Group 1 showed the highest scores for inflammation and group 3 showed the lowest scores for inflammation. Moreover, there was no significant difference between groups 2 and 3 ($p>0.05$). Medium-high scores for fibrosis were higher in group 1 (Fig.3) than in groups 2 (Fig.4) and 3, which had the same fibrosis scores. However, differences among the groups were non-significant (Table 3).

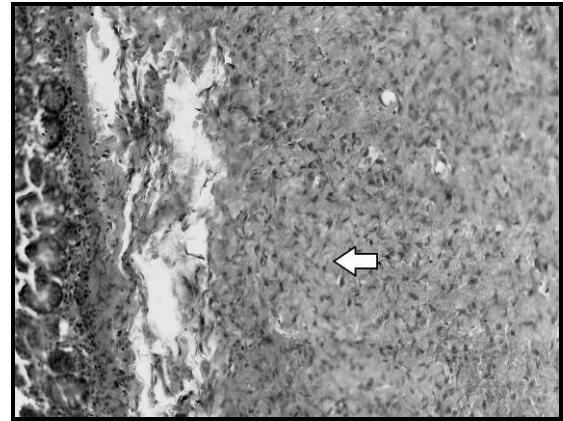


Figure 3. The histological view of fibrosis from a group 1 rat.

Table 3. Histopathological scores for fibrosis and inflammation.

Groups	Inflammation*		Fibrosis**	
	Score 0	Score 1	Score 0	Score 1
Group 1 (control)	4	6	4	6
Group 2 (icodextrin)	7	3	7	3
Group 3 (hyaluronic acid)	8	2	7	3

*Inflammation: Score 0= absent, mild. Score 1= moderate, severe. **Fibrosis: Score 0 = absent, mild. Score 1= moderate, severe.

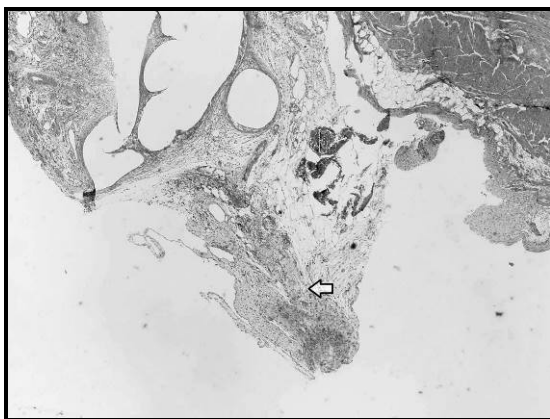


Figure 4. The histological view of fibrosis from group 2 rat.

Cost Analysis

As only the expense of the antiadhesive product considered, the approximate cost was 0.66 USD in a group 2 rat and 99 USD in a group 3 rat. The calculations were made basing the costs of 1500 ml

Adept solution (\$200 USD-March 2010) and 20 packs of 10 ml Hyalobarrier gel (\$6600 USD-March 2010). Hereby there was no statistically meaningful difference between ID and HA groups wise preventing intraabdominal adhesions, the cheaper one was preferred without performing statistical comparison.

Discussion

Intraabdominal adhesion is a clinical complication that causes serious morbidities such as infertility, chronic pelvic pain and intestinal injuries. Some of these problems may entail re-operation. It was indicated that abdominal adhesions formed after secondary laparotomy extended the laparoscopy, complicated the exploration and increased the possibility of iatrogenic intestinal diseases (17,18). It was reported that, in general surgery, 1% of all attempts and 3% of laparotomies are caused by peritoneal adhesions (19). This rate is higher in gynecological and pelvic operations. The incidence of intestinal obstruction varies between 0.3% and 10.7% in patients who underwent intraabdominal operations. The gynecological results of intraabdominal adhesions include infertility (%15-20), chronic pelvic pain,

dyspareunia and ectopic pregnancy. Further, it is known that in reoperations, there is increased risk of bleeding and injury of adjacent organs (20). The secondary problems of intraabdominal adhesions formed after laparotomy may cause to economical costs (17,18). This study determined that the control group irrigated with SF showed more significant adhesion scores than the ID and HA groups. Despite many previous studies, there is no standard method to prevent postoperative intraabdominal adhesions. In addition to the importance

of operation technique, some other materials are also used to prevent the intraabdominal adhesions. Macromolecular solutions and mechanical tools may be effective to separate the traumatized surfaces within 5-7 days, which is the most critical period of the peritoneal healing phase. ID and HA are used in the present study. Previous clinical and experimental studies showed the efficiency of HA and ID in the prevention of intraabdominal adhesions (Table 4).

Table 4. Comparison of some experimental and clinical studies to evaluate intraabdominal adhesions.

Rodgers²¹, 2003	Experimental	48 rabbits	ID	Ringer's lactate	NS
Müller¹⁴, 2003	Experimental	60 rabbits	ID↓, PL↓	Ringer's lactate	S
Mais⁴, 2006	Clinical	52 human	HA↓	Sham group	NS
Baca¹⁵, 2007	Experimental	60 rats	ID↓	Isotonic saline	S
Brown¹¹, 2007	Clinical	402 human	ID↓	Ringer's lactate	S
Binda⁹, 2009	Experimental	88 mice	HA↓, hypothermia↓, PL↓	Sham group	S
Present study	Experimental	30 rats	ID↓, HA↓	Isotonic saline	S

ID: Icodextrin, PL: phospholipid, HA: Hyaluronic Acid, NS: Not significant S: Significant, ↓: Lower adhesion formation

Rodgers (21) found no significant difference between ID and Ringer's lactate used in rabbits that underwent intestinal anastomosis. Müller et al (15) showed that, in rabbits, phospholipids and ID reduced intraabdominal adhesions significantly compared to Ringer's lactate. Shamiyehi et al (8) generated serosal defects on four separate areas in the intraabdominal cavity of pigs and observed that HA significantly reduced the adhesions. Baca et al (16) indicated that, in rats that underwent colon anastomosis, ID and Seprafilm groups showed reduced adhesion scores compared to the control group. It was shown that hyaluronic acid barriers could reduce adhesions by up to 50% after abdominopelvic operations (5). Hyaluronic acid-phosphate buffered normal saline solution used intra-operatively, especially in gynecologic surgeries, was examined in multi-centric studies and was found to be effective in the prevention of adhesions (22). Many recent studies reported that bioresorbable membrane (Seprafilm®) composed of hyaluronic acid and carboxymethyl-cellulose was effective and reliable in preventing adhesions (23).

In the present study, macroscopic examination indicated that adhesions and adhesion grades were significantly lower in the ID and HA groups than the control group. Although the ID group had higher adhesion intensity score than the HA group, no statistically significant difference was found between these two groups. The critical period for adhesion formation is the peritoneal healing phase that lasts approximately one week (21,22,23). During this phase, HA remains in the peritoneal cavity for 7 days while ID remains for just 4 days (4-10,12), which may be the reason for higher adhesion intensity observed in the ID group, despite not being statistically significant.

Intraabdominal adhesions also increase financial costs. A previous study showed that secondary hospitalization and operations due to intraabdominal adhesions entailed additional costs of 1.2 billion dollars in the USA during 1988 (24). Treatment costs for such cases remain high.

In this study, the calculation method used in rats were administered to human clinically: To maximize its effect, it is suggested that 20 ml/kg ID is administered intraperitoneally after the intraoperative lavage and operation (21). Conduction of 100 ml peritoneal lavage per 30 min during the operation and post-operative administration of 1000 ml to the peritoneal cavity is suggested for the clinical use of ID (9,10,12). To prevent intraabdominal adhesions, it is necessary to use 1500 ml ID for an adult patient undergoing an abdominal operation. The price of 1500 ml ID is \$200USD for March-2010. Therefore, the case will cost approximately 200\$.

For clinical use, it would be useful to apply 10 ml of HA in 1-2 mm thickness to each of the 100-150 cm² areas likely to form adhesion (9). HA is available in 10 ml packages, each costing \$330USD (March 2010). To estimate the abdominal cavity area of an adult patient, if the abdominal cavity is considered as a cylinder with an average radius of 12.5 cm and height of 25 cm, then the area of this cylinder is approximately 3,000 cm². Accordingly, if the HA is used as an adhesion preventive barrier to cover all sides of the abdominal cavity of an adult patient, then 20 packs of 10 ml HA will be required (since 10 ml is used for each 150 cm²). Therefore, this case would cost approximately 20×\$330USD = \$6600USD.

This study showed that the cost of using ID was considerably lower than that of HA. Based on the above cost estimates, the cost of HA would be 20 pieces × \$330USD = \$6600USD for 200ml, compared with an estimated cost for ID of 1 piece × \$200USD = \$200USD for 1500 ml. It is seen that there is a considerable cost difference between the two products when used for the prevention of intraabdominal adhesion.

ID has the advantages of low cost and easily application. The most important disadvantage of the HA and other hyaluronic acid adhesion barriers is their relatively high cost. Despite the lack of studies on this issue, total

operation cost constitutes an additional burden, considering that 3-4 packages of HA may be required for each patient.

In conclusion, it was observed that the HA and ID are effective in the prevention of intraabdominal adhesions. Their effect is much alike. Our results match those of previous studies. We are of the opinion that ID is advantageous as it is cost-effective, easily applicable and it does not extend the period in either laparotomy or laparoscopy operations.

Despite the findings of existing studies, further studies are required to find the ideal adhesion preventive barrier.

Acknowledgement

The authors thank to Assistant Professor Tuba Direkçi, Dept of Economics, for her help in statistics of the manuscript.

References

1. Li TC, Cooke ID. The value of an absorbable adhesions barrier, interceded in the prevention of adhesions reformation following microsurgical adhesiolysis. *Br J Obstet Gynaecol* 1994;101:335-9.
2. Liakakos T, Thomakos N, Fine PM, Dervenis C, Young RL. Peritoneal adhesions: etiology, pathophysiology, and clinical significance. *Dig Surg* 2001;18:260-73.
3. Hye SA, Hyuk JL, Moon WY, Sang HJ, Tae SH, Woo HK and et al. Efficacy of an injectable thermosensitive gel on postoperative adhesion in rat model. *J Korean Surg Soc* 2010; 79: 239-245.
4. Mais V, Bracco GL, Litta P, Gargiulo T, Melis GB. Reduction of postoperative adhesions with an auto-crosslinked hyaluronan gel in gynaecological laparoscopic surgery: a blinded, controlled, randomized, multicentre study. *Hum Reprod*. 2006;21:1248-54.
5. Becker JM, Dayton MT, Fazio VW, Beck DE, Stryker SJ, Wexner SD, et al. Prevention of postoperative abdominal adhesions by a sodium hyaluronate-based bioresorbable membrane: a prospective, randomized, double-blind multicenter study. *J Am Coll Surg* 1996;183:297-306.
6. Salum MR, Lam DT, Wexner SD, Pikarsky A, Baig MK, Weiss EG, et al. Does limited placement of bioresorbable membrane of modified sodium hyaluronate and carboxymethylcellulose (Seprafilm®) have possible short-term beneficial impact? *Dis Colon Rectum*. 2001;44:706-12.
7. Guida M, Acunzo G, Di Spiezio Sardo A, Bifulco G, Piccoli R, Pellicano M, et al. Effectiveness of auto-crosslinked hyaluronic acid gel in the prevention of intrauterine adhesions after hysteroscopic surgery: a prospective, randomized, controlled study. *Hum Reprod* 2004;19:1461-1464.
8. Shamiyehi A, Danis J, Benkö L, Vattay P, Röth E, Tulipan L, et al. Effect of hyaluron derivate gel in prevention of postsurgical peritoneal adhesions-an experimental study in pigs. *Hepatogastroenterology* 2007;54:1121-4.
9. Binda MM, Koninckx PR. Hyperoxia and prevention of adhesion formation: a laparoscopic mouse model for open surgery. *BJOG* 2010;117:331-9.
10. Binda MM, Koninckx PR. Prevention of adhesion formation in a laparoscopic mouse model should combine local treatment with peritoneal cavity conditioning. *Hum Reprod* 2009;24:1473-9.
11. Brown CB, Luciano AA, Martin D, Peers E, Scrimgeour A, diZerega GS; Adept Adhesion Reduction Group. Adept (icodextrin 4% solution) reduces adhesions after laparoscopic surgery for adhesiolysis: a double-blind, randomized, controlled study. *Fertil Steril* 2007;88:1413-26.
12. Menzies D, Pascual MH, Walz MK, Duron JJ, Tonelli F, Crowe A, et al. Use of icodextrin 4% solution in the prevention of adhesion formation following general surgery: from the multicentre ARIEL Registry. *Ann R Coll Surg Engl* 2006;88:375-82.
13. Kössi J, Grönlund S, Uotila-Nieminen M, Crowe A, Knight A, Keranen U. The effect of 4% icodextrin solution on adhesiolysis surgery time at the Hartmann's reversal: a pilot, multicentre, randomized control trial vs lactated Ringer's solution *Colorectal Dis*. 2009;11:168-72.
14. Müller SA, Treutner KH, Anurov M, Titkova S, Oettinger AP, Schumpelick V. Experimental evaluation of phospholipids and icodextrin in re-formation of peritoneal adhesions. *Br J Surg* 2003;90:1604-7.
15. Baca B, Boler DE, Onur E, Akca O, Hamzaoglu I, Karahasanoglu T, et al. Icodextrin and Seprafilm do not interfere with colonic anastomosis in rats. *Eur Surg Res* 2007;39:318-23.
16. Mazuji MK, Kalambaheti K, Pawar B. Prevention of adhesions with polyvinylpyrrolidone. *Arch Surg* 1964;89:1011-5.
17. Coleman MG, McLain AD, Moran BJ. Impact of previous surgery on time taken for incision and division of adhesions during laparotomy. *Dis Colon Rectum* 2000;43:1297-9.
18. Van Der Krabben AA, Dijkstra FR, Nieuwenhuijzen M, Reijnen MM, Schaapveld M, Van Goor H. Morbidity and mortality of inadvertent enterotomy during adhesiotomy. *Br J Surg* 2000;87:467-71.
19. Parlak M. İnce Barsak Hastalıkları. In: Kalaycı G. Genel Cerrahi.1st ed. İstanbul: Nobel Tıp Kitabevleri; 2002:1299-1319.
20. Tito WA, Sarr MG. Intestinal obstructions. In: Zuidema GD, Nyhus LM, editors. *Schakelford's Surgery of Alimentary Tract*. WB Saunders. 1996;5:375-416.
21. Rodgers KE, Verco SJS, DiZerega GS. Effects of intraperitoneal 4% icodextrin solution on the healing of bowel anastomoses and laparotomy incisions in rabbits. *Colorectal Disease* 2003;5:324-30.
22. Diamond MP. Reduction of de novo postsurgical adhesions by intraoperative precoating with Sepracoat (HAL-C) solution: A prospective, randomized, blinded, placebo-controlled multicenter study. The Sepracoat Adhesion Study Group. *Fertil Steril* 1998;69:1067-74.
23. Baptista ML, Bonsack ME, Delaney JP. Seprafilm reduces adhesions to polypropylene mesh. *Surgery*. 2000;128:86-92.
24. Fox Ray NF, Larsen JW, Stillman RJ, Jacobs RJ. Economic impact of hospitalizations for lower abdominal adhesiolysis in the United States in 1988. *Surg Gynecol Obstet* 1993;176:271-6.