

# Thymic mucoepidermoid carcinoma: A case report

## Timik mukoepidermoid karsinoma: Olgu sunumu

Göktan Temiz<sup>1</sup>, Özgür Ömer Yıldız<sup>2</sup>, Ömer Cenap Gülyüz<sup>3</sup>, Nurettin Karaoğlanoğlu<sup>2</sup>

<sup>1</sup> Department of Thoracic Surgery, Adana City Education and Research Hospital, Adana, Turkey

<sup>2</sup> Department of Thoracic Surgery, Yıldırım Beyazıt University, Faculty of Medicine Ankara Bilkent City Hospital, Ankara, Turkey

<sup>3</sup> Department of Thoracic Surgery, Adiyaman University Education and Research Hospital, Adiyaman, Turkey

ORCID ID of the author(s)

GT: 0000-0002-8025-5315  
ÖÖY: 0000-0001-7314-3131  
ÖCG: 0000-0001-8528-5567  
NK: 0000-0003-2827-6044

### Abstract

Mucoepidermoid carcinoma of the thymus is a rare malignant neoplasm of the anterior mediastinum. There are less than 30 cases described in the English literature. We report a case of a 77-year-old man with right chest pain. Thorax CT scan showed a lobulated cystic mass having a focal solid portion with direct invasion of the adjacent pericardium in the anterior mediastinum. He underwent surgical resection for his anterior mediastinal mass via right thoracoscopic surgery without any complication. He had an uneventful recovery and was discharged on the sixth postoperative day.

**Keywords:** Thymus, Mucoepidermoid carcinoma, Mediastinum

### Öz

Timik mukoepidermoid karsinoma, anterior mediastende izlenen nadir bir malignitedir. Literatürde açıklanan 30'dan az vaka mevcuttur. Bizim olgumuz; sağ göğüs ağrısı olan, toraks BT'de anterior mediastende komşu perikardın direkt invazyonu ile fokal bir solid kısma sahip lobüle kistik kitle tespit edilen 77 yaşında bir erkek hastaydı. Anterior mediastinal kitlesi için herhangi bir komplikasyon olmaksızın sağ torakoskopik cerrahi ile rezeksiyon uygulandı. Sorunsuz bir iyileşme sürecinden sonra postoperatif altıncı günde taburcu edildi.

**Anahtar kelimeler:** Timus, Mukoepidermoid karsinoma, Mediastinum

### Introduction

Mucoepidermoid carcinoma is a rare tumor of the lung, which arises from the minor salivary glands in the tracheo-bronchial tree. Thymic carcinomas are unusual malignant neoplasms that have wide variety of morphologic appearances. Mucoepidermoid carcinomas of the thymus are extremely rare malignant mediastinal neoplasms and account for 2% of thymic carcinomas [1,2]. We report a case of mucoepidermoid carcinoma of the thymus with radiologic and histologic findings.

Corresponding author / Sorumlu yazar:  
Özgür Ömer Yıldız

Address / Adres: Yıldırım Beyazıt Üniversitesi,  
Tıp Fakültesi, Ankara Bilkent Şehir Hastanesi,  
Göğüs Cerrahisi Anabilim Dalı, Ankara, Türkiye  
e-Mail: dr.ooyildiz@gmail.com

Informed Consent: The authors stated that the written consent was obtained from the patient presented with images in the study.

Hasta Onamı: Yazar çalışmada görüntüleri sunulan hastadan yazılı onam alındığını ifade etmiştir.

Conflict of Interest: No conflict of interest was declared by the authors.

Çıkar Çatışması: Yazarlar çıkar çatışması bildirmemişlerdir.

Financial Disclosure: The authors declared that this study has received no financial support.

Finansal Destek: Yazarlar bu çalışma için finansal destek almadıklarını beyan etmişlerdir.

Published: 7/18/2019

Yayın Tarihi: 18.07.2019

Copyright © 2019 The Author(s)

Published by JOSAM

This is an open access article distributed under the terms of the Creative Commons Attribution-Non Commercial-NoDerivatives License 4.0 (CC BY-NC-ND 4.0) where it is permissible to download, share, remix, transform, and build upon the work provided it is properly cited. The work cannot be used commercially without permission from the journal.



## Case presentation

In this case, a 77-year-old male, admitted to our hospital complaining of right chest pain was reported. The physical examination and laboratory studies were unremarkable. A 50x40 mm-sized lobulated cystic mass with focal heterogeneously solid portion in the anterior mediastinum was observed with thorax computed tomography (CT) scan of the chest (Figure 1). The patient did not show a mass with typical manifestations of myasthenia gravis. He had not ptosis and progressive muscle weakness. On thorax CT images, tumor was observed to adhere to the pericardium and infiltrated it (Figure 2). Neither pericardial/pleural effusion nor enlarged lymph nodes were detected.

Thorax CT guided fine needle biopsy of the anterior mediastinal mass was not performed. Thymectomy and resection of the adherent tissues were performed with the right videothoroscopic surgery. There were no intraoperative complications. Grossly, resected tumor measured 5x4 cm in size. It was a solid gray-red well-circumscribed mass with cystic compartments. Under the microscopical examination, mucous lake surrounded with atypical squamous epithelium and cylindric mucinous epithelium was seen in the thymus (Figure 3). Tumor has low mitotic activity without necrosis. Immunohistochemically, the epidermoid cells of the tumor were positive to pan-CK and p63 (Figure 4). The mucus-secreting cells are demonstrated by staining with mucicarmine (Figure 5). This part of tumor was diagnosed as low-grade mucoepidermoid carcinoma of the thymus according to the histopathological criteria of WHO classification [3].

Postoperative period was uneventful. Chemotherapy and radiotherapy of the main tumor bed were performed on the patient. Since there was a possibility of tumor metastasis to another anatomical location, the patient was referred to a whole body positron emission tomography positron emission tomography-computed tomography (PET-CT) study to search for the potentially secondary tumor, but there was not observed any abnormality. The fiberoptic bronchoscopy did not identify. Endobronchial lesion is located in tracheobronchial tree. So, the sign of the mucoepidermoid carcinoma of the lung was not detected. The patient was on regular follow-up for 4 months after discharging from hospital. He had remained asymptomatic, and there was no evidence of tumor recurrence during the period of postoperative follow-up. Informed patient consent was obtained for all procedures.

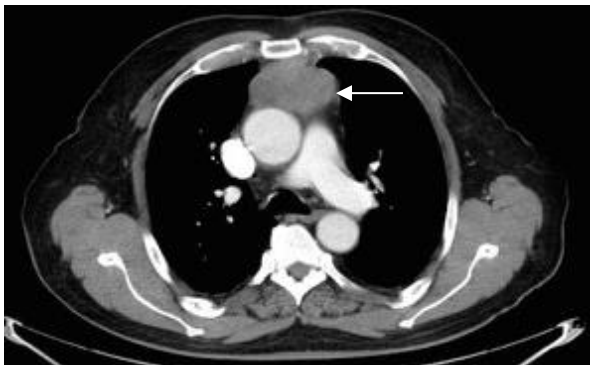


Figure 1: Computed tomography image of the patient showing a well-defined anterior mediastinal mass (arrow) within the thymus area

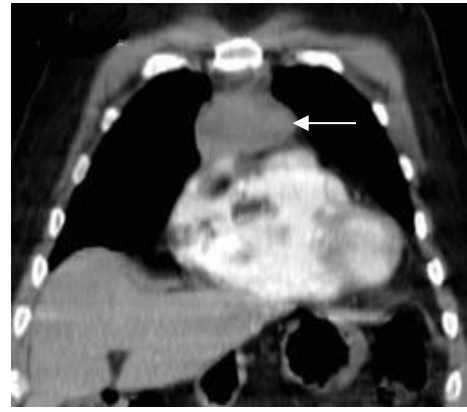

Figure 2: Computed tomography image of the patient showing the mass (arrow) in contact with the pericardium

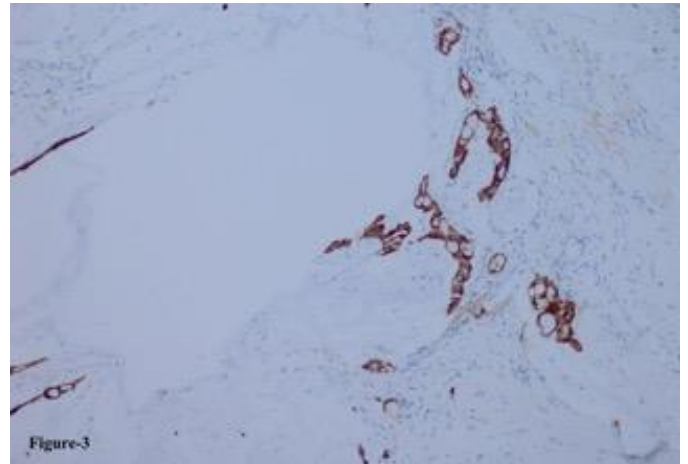


Figure 3: Mucous lake surrounding by atypical cylindric mucous epithelium and focal squamous epithelium (HE stain: x200)

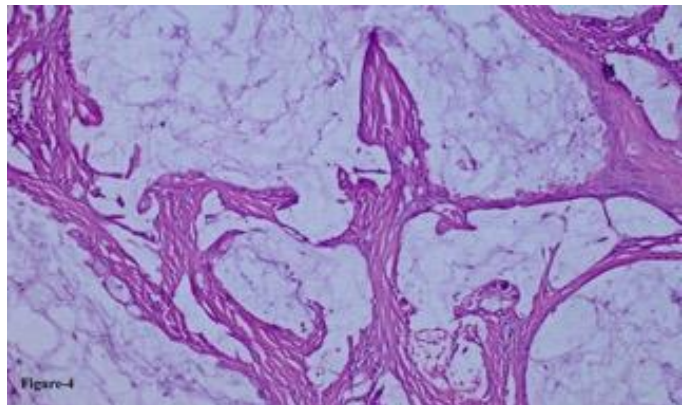


Figure 4: Atypical epithelial cells with pan-CK (+) staining surrounding mucous lake. (pan-CK stain: x200)

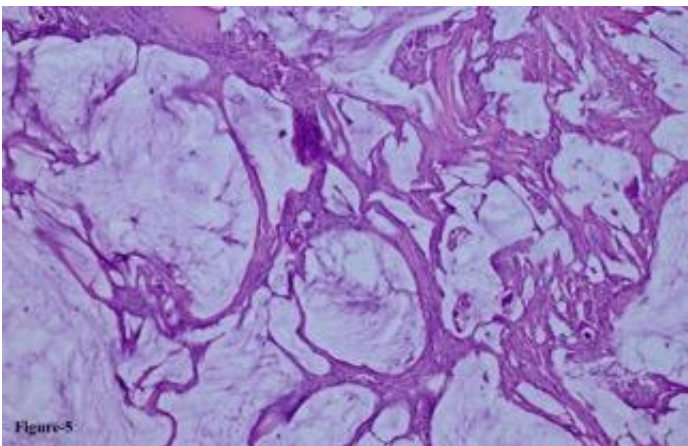


Figure 5: Mucicarmine (+) staining of the tumor. (Mucicarmine stain: x100)

## Discussion

Thymic carcinoma is a rare neoplasm of the thymus, and unlike a thymoma, it exhibits malignant features of obvious cytologic atypia, having a more aggressive propensity for early local invasion and wide spread metastases. It includes the following subtypes: Squamous cell carcinoma, lymphoepithelioma-like carcinoma, neuroendocrine carcinoma, adenosquamous carcinoma, clear cell carcinoma, papillary carcinoma, basaloid carcinoma, sarcomatoid carcinoma, and mucoepidermoid carcinoma [4,5]. The most common histologic type is squamous cell carcinoma, usually occurring in middle-aged men [6,7]. Our case was old-aged.

The prognosis of thymic carcinoma is poor because of early metastatic involvement of the pleura, lungs, lymph nodes of the mediastinum, bone and liver [8,9]. In our case, there was only pericardial invasion and the tumor was in pathological stage III according to the staging system of Masaoka. Thus, the present tumor was judged to be potentially completely resectable. Local recurrences and distant metastases are frequent, occurring at 35% and 50%, respectively. The overall survival rate at 5 years for thymic carcinoma is reported to be approximately 35% [6,7]. Thymic carcinomas have been roughly classified as either low or high-grade malignancy [6]. The low-grade tumors with relatively favorable prognoses include squamous cell carcinoma, mucoepidermoid carcinoma and basaloid carcinoma, whereas the high-grade tumors include the others with poor prognosis. Although it appears that mucoepidermoid carcinoma of the thymus is extremely rare, its histological characteristics have been well analyzed: It is composed of variably sized cysts, lobules, sheets and nests of such tumor cells as epidermoid cells, mucus-secreting cells, and occasionally intermediate type cells in a variable admixture [10,11]. In our case, similar histological and gross features were observed, and this tumor was finally diagnosed as mucoepidermoid carcinoma of the thymus. As described above, thymic mucoepidermoid carcinoma is generally considered to be a low-grade malignancy with a good prognosis [6].

The well-differentiated type, in which mitosis was virtually absent, was not fatal, while the poorly differentiated type was clinically aggressive enough to threaten life, and cellular atypia, mitosis, necrosis, and predominance of an epidermoid component were often observed. The present primary tumor regarded as the poorly-differentiated type because of the mitosis and cellular atypia. Accurate histologic subtyping, namely tumor differentiation as well as clinical staging are highly recommended for the diagnosis and treatment of this disease. Especially, when the tumor is anatomically located in contact with the pleura cavity, more accurate and careful staging may be clinically necessary in the long-term follow-up. If complete resection is possible, this type of tumor should be removed by surgery, as with other types of thymic carcinoma. Complete resection was performed in our case. Takahashi et al [12] reported that in a limited early stage of thymic carcinoma, surgical resection was adequate for treatment, although the rate of complete resection is only 20–35% [7,13,14]. However, if the tumor is advanced or recurrent, a multimodality approach, including surgical resection, radiation, chemotherapy, or a combination selected [14,15]. In our case, after surgery,

multimodal therapy including chemotherapy and radiotherapy were performed.

In conclusion, we here in described a rare case of thymic mucoepidermoid carcinoma undergoing multimodality treatment, including surgical resection, irradiation and chemotherapy. Although clinical aspects of this disease are little known, it was assumed that such aggressive therapy contributed to long-term survival.

## References

- Colby T, Koss M, Travis W. Tumors of salivary gland type. In: Tumors of the Lower Respiratory Tract. Atlas of Tumor Pathology; third series, fascicle 13. Washington, DC: Armed Forces Institute of Pathology; 1995.pp.65–89.
- Jung KJ, Lee KS, Han JH, Kim JG, Kim TS, Kim EA. Malignant thymic epithelial tumors: CT-pathologic correlation. *Am J Roentgenol.* 2001;176:433–9.
- Goode RK, El-Naggar AK. Mucoepidermoid carcinoma. In WHO classification of head and neck tumors. Edited by Barnes L, Eveson JW, Reichart P, Sidransky D. Lyon: IARC Press; 2005.pp.219-220.
- Rosai J. Histological typing of tumors of the thymus. Second edition. Heidelberg: Springer-Verlag, 1999.pp.13–15.
- Ritter JH, Wick MR. Primary carcinomas of the thymus gland. *Semin Diagn Pathol.* 1999;16:18–31.
- Suster S, Rosai J. Thymic carcinoma. A clinicopathologic study of 60 cases. *Cancer.* 1991;67:1025–32.
- Hsu CP, Chen CY, Chen CL, et al. Thymic carcinoma. Ten years experience in twenty patients. *J Thorac Cardiovasc Surg.* 1994;107:615–20.
- Wick MR, Scheithauer BW, Weiland LH, Bernatz PE. Primary thymic carcinomas. *Am J Surg Pathol.* 1982;6:613–30.
- Hartmann CA, Roth C, Minck C, Niedobitek G. Thymic carcinoma. Report of five cases and review of the literature. *J Cancer Res Clin Oncol.* 1990;116:69–82.
- Moran CA, Suster S. Mucoepidermoid carcinomas of the thymus. A clinicopathologic study of six cases. *Am J Surg Pathol.* 1995;19:826–34.
- Nonaka D, Klimstra D, Rosai J. Thymic mucoepidermoid carcinomas: a clinicopathologic study of 10 cases and review of the literature. *Am J Surg Pathol.* 2004;28:1526–31.
- Takahashi K, Yoshida J, Nishimura M, Nagai K. Thymic carcinoma. Outcome of treatment including surgical resection. *Jpn J Thorac Cardiovasc Surg.* 2000;48:494–8.
- Yano T, Hara N, Ichinose Y, Asoh H, Yokoyama H, Ohta M. Treatment and prognosis of primary thymic carcinoma. *J Surg Oncol.* 1993;52:255–8.
- Hernandez-Ilizaliturri FJ, Tan D, Cipolla D, Connolly G, Debb G, Ramnath N. Multimodality therapy for thymic carcinoma (TCA): results of a 30-year single-institution experience. *Am J Clin Oncol.* 2004;27:68–72.
- Lucchi M, Mussi A, Basolo F, Ambrogi MC, Fontanini G, Angeletti CA. The multimodality treatment of thymic carcinoma. *Eur J Cardiothorac Surg.* 2001;19:566–9.

The National Library of Medicine (NLM) citation style guide is used in this paper.

Suggested citation: Patrias K. Citing medicine: the NLM style guide for authors, editors, and publishers [Internet]. 2nd ed. Wendling DL, technical editor. Bethesda (MD): National Library of Medicine (US); 2007-[updated 2015 Oct 2; cited Year Month Day]. Available from: <http://www.nlm.nih.gov/citingmedicine>