

A Quadricuspid Aortic Valve with Mild Aortic Regurgitation



Hafif Aort Yetersizliğinin Eşlik Ettiği Quadriküspid Aort Kapak

Yusuf Karavelioğlu¹, İsmail Ekinözü¹, Mücahit Yetim¹, Macit Kalçık¹

¹ University of Hitit, Faculty of Medicine, Department of Cardiology, Çorum, Turkey

A 21-year-old male was admitted to our outpatient clinic with atypical chest pain. He had no history of cardiovascular disease. Physical examination revealed 2/4 diastolic murmur along the right sternal border, and his electrocardiogram was normal. Transthoracic echocardiography revealed mild aortic regurgitation in the parasternal long-axis view. Transaortic gradients were within the normal limits. However, in the parasternal short-axis view, a quadricuspid aortic valve was visualized. Transesophageal echocardiography (TEE) was subsequently performed that confirmed the presence of type A quadricuspid aortic valve according to the Hurwitz–Roberts classification with four equal-sized cusps and mild aortic regurgitation⁽¹⁾ (Figure 1). There was no other concomitant congenital malformation, which could be detected by TEE. Because his chest pain was atypical and the stress test provided negative results for ischemia, coronary angiography was not performed.

A quadricuspid aortic valve is a very rarely diagnosed congenital malformation because most patients are asymptomatic and have normally functioning valves. In symptomatic cases, aortic regurgitation is a more frequent presentation than aortic stenosis⁽²⁾. Despite usually appearing as an isolated congenital anomaly, it may be associated with other congenital malformations, with the most common malformation being coronary artery anomalies⁽³⁾. Clinical follow-up should be performed for these patients to detect the onset or worsening of symptoms and to enable appropriate therapeutic intervention.

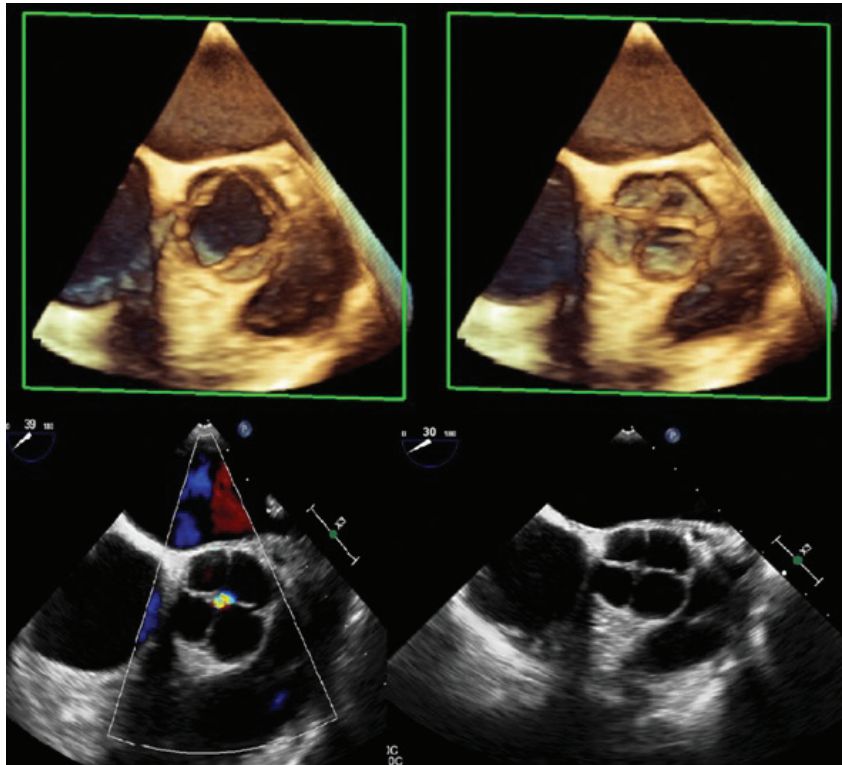


Figure 1. Two-dimensional and real-time three-dimensional transesophageal echocardiography demonstrating a quadricuspid aortic valve with four equal-sized cusps and mild aortic regurgitation.

Cite this article as: Karavelioğlu Y, Ekinözü İ, Yetim M, Kalçık M. A quadricuspid aortic valve with mild aortic regurgitation. Koşuyolu Heart J 2019;22(2):139-40.

Correspondence

Yusuf Karavelioğlu

E-mail: drcomtr@gmail.com

Submitted: 16.03.2019

Accepted: 16.05.2019

© Copyright 2019 by Koşuyolu Heart Journal. Available on-line at www.kosuyoluheartjournal.com

REFERENCES

1. Hurwitz LE, Roberts WC. Quadricuspid semilunar valve. *Am J Cardiol* 1973;31:623e626.
2. Gouveia S, Martins JD, Costa G, Paramés F, Freitas I, Rebelo M, et al. Quadricuspid aortic valve-10-year case series and literature review (in Portuguese). *Rev Port Cardiol* 2011;30:849-54.
3. Tutarel O. The quadricuspid aortic valve: a comprehensive review. *J Heart Valve Dis* 2004;13:534-7.