

# Clinical Course Of A Death From Ranolazine Overdose: A Case Report

Mehmet Ali Yavuz<sup>1</sup>, Ramazan Asoglu<sup>2</sup>

<sup>1</sup>Gaziantep Nizip Government Hospital

<sup>2</sup>Adiyaman University, Faculty of Medicine

## Abstract

**Introduction:** Ranolazine is a new medication for angina pectoris. It is usually used for refractory angina pectoris. Ranolazine overdose may cause some serious effects on heart like other cardiac medications.

**Case Report:** We report the case of a 21-year-old girl was brought to the emergency department because of an attempt to commit suicide with a large number of Ranolazine tablets. She went into the coma and was unresponsive to verbal and painful stimuli after two hours of admission. There was no pathological findings on brain computed tomography (CT) and Magnetic Resonance Imaging (MRI). The QT interval was 420 msec and more extended than previous measurements. The patient had three episodes of polymorphic nonsustained ventricular tachycardia (NSVT). Despite the amiodarone treatment, the NSVT evolved to polymorphic sustained ventricular tachycardia (Torsade de Pointes; TdP) and Ventricular fibrillation (VF). The patient underwent CPR and accepted as death end of the resuscitation due to asystole on the ECG.

**Conclusion:** Ranolazine overdose is known that may cause some serious ECG changes and seizures. But suddenly entering a coma and death has never been reported with ranolazine intoxication in literature.

**Keywords:** Ranolazine overdose, Death, Torsades De Pointes

## Introduction

Ranolazine is an anti-anginal and anti-ischemic medication. It was approved for the treatment of chronic, stable angina by the Food and Drug Administration (FDA) in 2006. It improves exercise performance and prevents the symptoms of myocardial ischemia during exercise in patients with chronic angina<sup>1</sup>. Ranolazine is a safe drug, but it can cause side effects at higher dosages. Common side effects include nausea, constipation, dizziness and prolonged QT (QTc) intervals in a dose dependent manner. It has also been reported that ranolazine can cause seizures<sup>2</sup>.

In this report, we presented a case with high dose ranolazine usage that was related to new onset convulsions and QT interval changes, and ultimately, to death due to ventricular arrhythmia.

## Case Report

A 21-year-old woman was brought to the emergency department by her family. She had attempted to commit suicide by ingesting a large number of ranolazine tablets one hour prior

to her admission. She had no history of medical problems and was not taking any medications. On admission, the patient had dysarthria and dysmetria; otherwise, her neurological examination was normal except that she was disoriented to time, place and person and had difficulties in following commands. The patient's vital signs were within the normal range. Her electrocardiogram (ECG) showed that her heart was in a sinus rhythm, and that her QT interval was nearly normal (Figure 1) [heart rate (HR) = 92 beats per minute (bpm); QT interval = 360 milliseconds (msec); cQT = 446 msec with Bazett's formula]. A venous blood sample was collected, and ranitidine [50 milligrams (mg)] and omeprazole (40 mg) were administered as a slow intravenous injection to protect the stomach. A nasogastric tube was inserted, and gastric lavage was performed by passing water through the tube. After completion of the gastric lavage, 100 grams of activated charcoal was administered through the nasogastric tube. The results of blood chemistry studies, including liver function tests, blood glucose level test, and urea, creatinine and serum electrolytes levels [Sodium (Na), Potassium (K), Magnesium, Calcium (Ca) and Chloride (Cl)] were within reference ranges. A complete blood count, arterial blood gas test and troponin I test were also within reference ranges. Two hours after admission,

**Corresponding Author:** Mehmet Ali Yavuz **e-mail:** m.yavuzali@gmail.com

**Received:** 20.08.2019 • **Accepted:** 19.05.2020

**DOI:**10.33706/jemcr.607486

©Copyright 2020 by Emergency Physicians Association of Turkey - Available online at www.jemcr.com

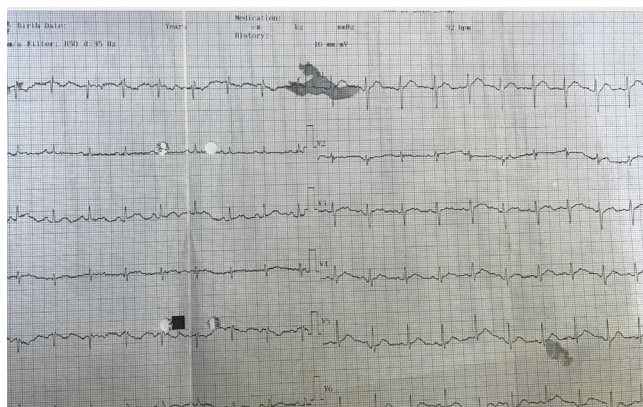


Figure-1

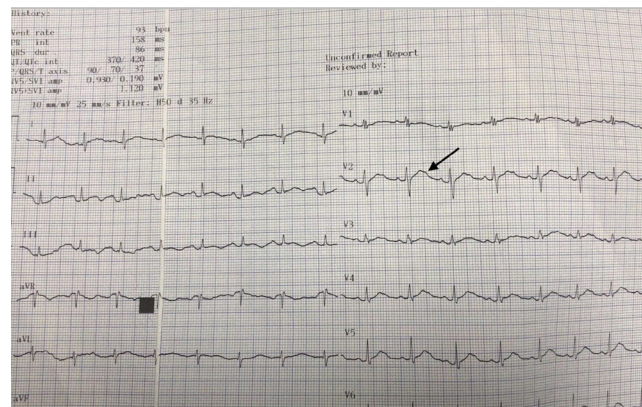


Figure-2

she was unresponsive to verbal and painful stimuli. The patient was intubated due to respiratory failure. The ECG was repeated two hours after the first ECG; the QT interval was 420 msec and was more extended than in the first ECG (Figure 2) (HR = 93 bpm, QT interval = 420 msec, cQT = 523 msec with Bazet's formula). A computed tomography scan (CT) and magnetic resonance imaging (MRI) were performed on the brain, and there were no pathological findings.

The patient had two episodes of generalized tonic-clonic convulsions within a short time period—two hours after admission. Diazepam was given as an intravenous 45 mg bolus for convulsions, and the patient was admitted to the intensive care unit (ICU) for closer monitoring. The patient developed three episodes of polymorphic nonsustained ventricular tachycardia (NSVT) six hours after admission to the ICU; therefore, continuous intravenous amiodarone was administered. Despite the amiodarone, the NSVT evolved to polymorphic sustained ventricular tachycardia (Torsades de Pointes, TdP) that required a 300 Joules (J) cardiac defibrillation. TdP evolved to resistance ventricular fibrillation (VF) after the cardiac defibrillation. Resistance VF continued against the 360 J defibrillation, and cardiopulmonary resuscitation (CPR) was started. Atropine, adrenaline and magnesium were administered during CPR. Asystole was observed during CPR. The patient underwent CPR for 95 minutes and was declared dead at the end of the resuscitation due to asystole on the ECG.

During the autopsy, medicine tablet particles were found in the stomach contents. Also, 38 nanograms per milliliter (ng/ml) diazepam, 27 ng/ml atropine, 121 ng/ml metoclopramide and 477 ng/ml ranitidine were detected in the blood due to medications which were administered during treatment and resuscitation. The forensic medicine department reported that the cause of death was medicine intoxication (no medication name was specified). We interviewed the laboratory manager for forensic medicine and confirmed that ranolazine was not among routine medications they look for in samples in the forensic laboratory. This told us

that the tablets in the stomach contents were ranolazine, and that they caused cardiac arrest due to overdose.

## Discussion

Ranolazine is a new anti-ischemic medication recommended in patients with stable angina. Ranolazine significantly improves exercise duration, time to angina and time to ST-segment depression either as monotherapy or in combination with anti-anginal medications (e.g., amlodipine, atenolol and diltiazem). Ranolazine interrupts the pathophysiology of myocardial ischemia and prevents diastolic failure by inhibiting the myocardial late inward sodium current related to ischemia. Thus, ranolazine could increase the diastolic myocardial oxygen supply during ischemia<sup>1, 3</sup>.

A combination assessment of ranolazine in stable angina (CARISA) trial studied the role of ranolazine on angina frequency and revealed a significant reduction in mean angina attacks each week. The same trial also reported significant increases in treadmill exercise performance and significant decreases in angina frequency and nitroglycerin consumption<sup>4</sup>. Ranolazine is widely metabolized primarily through the cytochrome P450 3A4 (CYP3A4) pathway with a small amount (5 percent) excreted unchanged in the urine, and it is contraindicated in patients with hepatic and severe renal impairment, those with QTc prolongation or those who are using drugs known to prolong the QT interval<sup>5</sup>.

The most common adverse effects reported in clinical studies include dizziness, constipation, nausea, hypotension and headache along with post-marketing reports of angioedema, ataxia, and Torsade de Pointes. Dizziness and nausea are the most common reasons for discontinuation of ranolazine. Also, postural hypotension and syncope developed in healthy volunteers with higher doses and without cardiac arrhythmias or QT prolongation<sup>4, 6</sup>. Kalra et al. reported that ranolazine caused myoclonus and hallucinations<sup>7</sup>. Our patient had a generalized tonic-clonic convul-

sion, which might be related to ranolazine blockage of the sodium (Na) channel in the brain.

Ranolazine increases the action potential duration and therefore prolongs QT intervals in a dose dependent manner<sup>1</sup>. Another study reported that ranolazine is associated with TdP, which is related to the QT interval prolongation usually due to the inhibition of the rapid outward potassium currents (IKr)<sup>8</sup>. We assumed that cardiac arrhythmia developed due to potassium channel blockage as a result of a ranolazine overdose in the patient. Also, T-wave notching has been observed at high ranolazine concentrations in the plasma, and our patient's last ECG showed T-wave notching (Figure 2, black arrow)<sup>9</sup>.

## Conclusion

In this case report, we presented an overdose of ranolazine that was related to convulsions and TdP. The QT interval was associated with malignant arrhythmias such as TdP and VF. TdP evolved to resistive ventricular fibrillation and then to asystole in the patient.

To our knowledge, suddenly total loss of consciousness(-coma) and death from ranolazine intoxication has never been reported. Because fatal ECG and consciousness changes were observed in our patient, we recommend that an ECG should be acquired at baseline with close follow-up for at least 24 hours in the ICU to assess the QT and vital sign changes in patients who are suspected of ranolazine overdoses.

## CONFLICT OF INTEREST

We declare that there is no conflict of interest.

## References

1. Chaitman BR, Skettino SL, Parker JO, Hanley P, Meluzin J, Kuch J, Pepine CJ, Wang W, Nelson JJ, Hebert DA, Wolff AA. Anti-ischemic effects and long-term survival during ranolazine monotherapy in patients with chronic severe angina. *Journal of the American College of Cardiology* 2004 Apr 21;43(8):1375-82.
2. Akil N, Bottei E, Kamath S. Ranolazine overdose-induced seizures. *The American journal of emergency medicine* 2015 Dec 1;33(12):1843-5.
3. Sossalla S, Wagner S, Rasenack EC, Ruff H, Weber SL, Schön-dube FA, Tirilomis T, Tenderich G, Hasenfuss G, Belardinelli L, Maier LS. Ranolazine improves diastolic dysfunction in isolated myocardium from failing human hearts—role of late sodium current and intracellular ion accumulation. *Journal of molecular and cellular cardiology* 2008 Jul 1;45(1):32-43.
4. Chaitman BR, Pepine CJ, Parker JO, Skopal J, Chumakova G, Kuch J, Wang W, Skettino SL, Wolff AA, Combination Assessment of Ranolazine In Stable Angina (CARISA) Investigators. Effects of ranolazine with atenolol, amlodipine, or diltiazem on exercise tolerance and angina frequency in patients with severe chronic angina: a randomized controlled trial. *Jama* 2004 Jan 21;291(3):309-16.
5. Abdallah H, Jerling M. Effect of hepatic impairment on the multiple-dose pharmacokinetics of ranolazine sustained-release tablets. *The Journal of Clinical Pharmacology* 2005 Jul 1;45(7):802-9.
6. Stone PH, Gratsiansky NA, Blokhin A, Huang IZ, Meng L, ERICA Investigators. Antianginal efficacy of ranolazine when added to treatment with amlodipine: the ERICA (Efficacy of Ranolazine in Chronic Angina) trial. *Journal of the American College of Cardiology* 2006 Aug 1;48(3):566-75.
7. Kalra SS, Arora Z, Nielsen C. Ranolazine and Hallucinations. *Journal of Medical Cases* 2017 Mar 5;8(3):90-2.
8. Morrow DA, Scirica BM, Karwadowska-Prokopczuk E, Murphy SA, Budaj A, Varshavsky S, Wolff AA, Skene A, McCabe CH, Braunwald E, MERLIN-TIMI 36 Trial Investigators. Effects of ranolazine on recurrent cardiovascular events in patients with non-ST-elevation acute coronary syndromes: the MERLIN-TIMI 36 randomized trial. *Jama* 2007 Apr 25;297(16):1775-83.
9. Chaitman BR. Efficacy and safety of a metabolic modulator drug in chronic stable angina: review of evidence from clinical trials. *Journal of cardiovascular pharmacology and therapeutics* 2004 Mar;9(1\_suppl): S47-64.

