

A Case of Bardet Biedl Syndrome

Hakan UZUN¹, Kubilay AR², Alev AKTAŞ¹, Mustafa BAK²

¹Department of Pediatrics, Duzce University, Faculty of Medicine, Duzce, Turkey, ² Dr Behcet Uz Children Hospital, İzmir, Turkey

SUMMARY

Bardet Biedl syndrome is a rare autosomal recessive condition with a wide spectrum of clinical features. The accepted major criteria for diagnosis include retinal dystrophy, obesity, polydactyl, male hypogonadism, mental retardation and renal dysfunction. We presented an 11 years old boy patient exhibiting characteristic features of this syndrome. In the light of this case, the literature about Bardet Biedl syndrome was reviewed.

Key Words: Bardet Biedl syndrome, child

Bardet Biedl Sendromlu Bir Olgu

ÖZET

Bardet Biedl sendromu, geniş klinik yelpazesi olan otozomal resesif geçişli nadir bir durumdur. Retinal distrofi, obezite, polidaktili, erkek hipogonadizmi, mental retardasyon ve renal fonksiyon kaybı, tanı için kabul edilen major kriterleri oluşturur. Bu sendromun karakteristik özelliklerini gösteren 11 yaşında bir erkek çocuk sunduk. Bu sendrom doğrultusunda Bardet Biedl sendromu ile ilgili literatürler de gözden geçirildi.

Anahtar Kelimeler: Bardet Biedl sendromu, çocuk

INTRODUCTION

Bardet-Biedl syndrome (BBS [MIM 209900]) is a rare autosomal recessive disorder. BBS was first described by Bardet and Biedl in the 1920 (1). The principal manifestations are rod-cone dystrophy (Retinitis pigmentosa), postaxial polydactyly, central obesity, mental retardation, hypogonadism, and renal dysfunction. Other features not always present include hepatic fibrosis, diabetes mellitus, neurological, speech and language deficits, behavioral traits, facial dysmorphism, dental anomalies and developmental delay (2,3). We presented here a case of BBS which is rarely seen.

CASE REPORT

An 11 years old boy was admitted to our hospital with the complaints of loss of vision, speech deficit, learning difficulty, poor balance, and ataxic gait. He was the seventh child of healthy consanguineous parents (second-degree relatives). His oldest two brothers had died (one at

the age of 1 and, the other at 3 months old) and the etiologies of their deaths are unknown.

On physical examination he had facial dysmorphism, he weighed 46 kg, his height was 134 cm and body mass index (BMI) was 25.6. Exotropia, horizontal nystagmus, rod-cone dystrophy (atypical retinitis pigmentosa) in his left eye was noticed on ophthalmologic examination. Neurological examination showed signs of ataxia, poor coordination, dysmetria, dysdiadochokinesia and intentional tremor, and, maldescended testes were detected on genital examination, his penis was small and buried in adipose tissue (Figure 1). He had a postaxial polydactyly on the left foot (Figure 2). He had mild mental retardation.

Laboratory analyses including complete blood count, urinalysis, biochemical and thyroid hormone parameters, transthoracic echocardiography as well as magnetic resonance imaging (MRI) scans of brain and hypophysis were normal. Renal ultrasonography revealed few renal parenchymal cysts of 7-12 mm diameter bilaterally.

Table 1. Modified diagnostic criteria and clinical manifestation in case.

Primary Features	Case
Rod-cone Dystrophy	+
Polydactyly	+
Obesity	+
Learning Disabilities	+
Hypogonadism in males	+
Renal Anomalies	+
Secondary Features	
Speech disorder/Delay	+
Strabismus/cataracts/astigmatism	+
Brachydactyly/syndactyly	-
Developmental delay	-
Nephrogenic diabetes insipidus	-
Ataxia/poor coordination/inbalance	+
Mild spasticity	-
Diabetes mellitus	-
Dental crowding/hypodontia/small roots	-
Left ventricular hypertrophy/congenital heart disease	-
Hepatic fibrosis	-

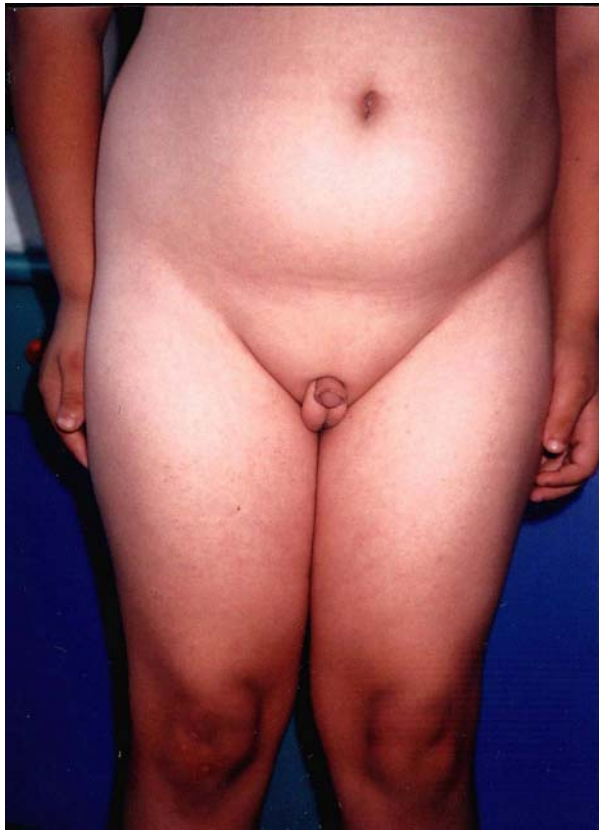


Figure 1: Maldescended testes and small penis buried in adipose tissue

DISCUSSION

The syndrome was described by Bardet Biedl in the 1920. It was later erroneously coupled with another disorder described by Laurence and

Moon, and was consequently referred to as Laurence- Moon-Biedl syndrome. BBS is distinguished from the much rarer Laurence-Moon syndrome, in which retinal pigmentary degeneration, mental retardation and hypogonadism occur in conjunction with progressive spastic paraparesis and distal muscle weakness, but without polydactyly (4,5).

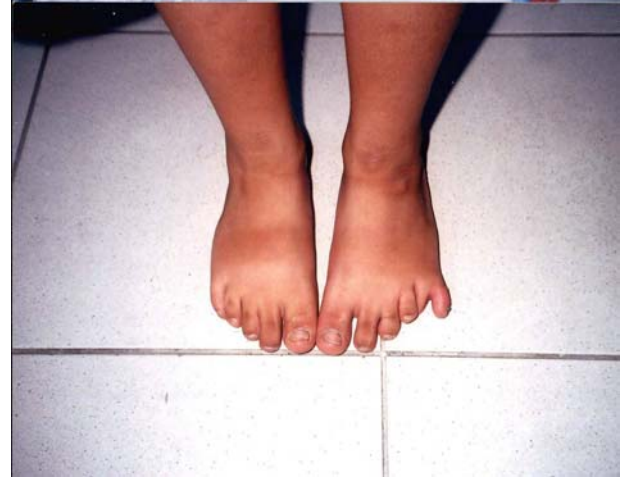

Figure 2: Extra digit on the patient's left foot.

The prevalence of BBS is 1:160000 in Europe and North America (6), although higher incidence has been reported in the isolated populations of Newfoundland [1:13000 (2)] and Kuwait [1:17000 (7)].

Obesity, mainly of the trunk is one of the most common features in BBS. It develops in early childhood and is aggravated with age. Ocular manifestations are also common and become apparent between the ages of 4 and 10 years. Hypogonadism in affected males is common. Most affected men have small external genitalia with primary testicular failure. Postaxial polydactyly is one of the earliest and most common manifestations of BBS. Renal failure is the major cause of morbidity and early mortality in BBS. A wide range of renal abnormalities has been described (chronic renal failure, parenchymal cysts, calyceal clubbing, fetal lobulation, scarring, unilateral agenesis, dysplastic kidneys, renal calculi, vesicoureterix reflux). Despite the presence of underlying renal malformations, only a small number of patients were symptomatic at the time of the survey. Mild to moderate mental retardation and learning difficulties are additional features of the syndrome (2,3). In 1999, modified diagnostic criteria were defined after a study conducted in England in 109 BBS patients (3). Patients who had 4 primary characteristics or 3 primary and 2 secondary

criteria were identified as BBS (Table 1). Our case had the entire primary and 3 of the secondary diagnostic criteria.

BBS is an autosomal recessive disorder characterized by non-allelic heterogeneity. Genetic analysis has mapped the disease to several independent loci, all of which produce similar phenotypes. Linkage analysis studies have so far identified eight distinct loci responsible for the syndrome [BBS1:11q13 (8), BBS2:16q21(9), BBS3:3p13-p12(10), BBS4:15q22-3q23(11), BBS5:2q31(12), BBS6: 20p12(13), BBS7: 4q27(14), BBS8: 14q32.11(15)]. Six genes associated with BBS have been identified, but their sequences have not illuminated the molecular and cellular etiology of the disease. The most plausible hypothesis regarding a shared function for BBS proteins is that they assist microtubule-related transport and cellular organization processes, in particular relating to ciliary/flagellar and centrosomal activities. This hypothesis is supported by several studies using different model organisms (15,16,17). Some of the phenotypes exhibited by BBS proteins, including retinal degeneration, skeletal anomalies and renal cysts/malformations bear resemblance to human diseases associated with abnormal cilia function (15,18).

Further larger scale studies should be conducted in order to understand the exact pathogenesis of this syndrome. We presented here a rare syndrome. In the light of this case, the literature about BBS was reviewed.

Correspondence:

Hakan Uzun

Department of Pediatric,

Duzce University, Faculty of Medicine,

Konuralp/ Duzce, Turkey.

Telephone: 0380- 5412151-2016

Fax: 0380-5414105

e-mail: *Uzunhakan2003@yahoo.com*

REFERENCES

1. Bardet G. Sur un syndrome d'obésité infantile avec polydactyly et rétinite pigmentaire. Thesis, University of Paris, France, 1920.
2. Green JS, Parfrey PS, Harnett JD, Farid NR, Cramer BC, Johnson G, et al. The cardinal manifestations of Bardet-Biedl syndrome, a form of Laurence-Moon-Biedl syndrome. *N Engl J Med* 321:1002-1009,1989.
3. Beales PL, Elcioglu N, Woolf AS, Parker D, Flinter FA. New criteria for improved diagnosis of Bardet-Biedl syndrome: results of a population survey. *J Med Genet* 36:437-446,1999
4. Laurence JZ, Moon RC. Four cases of retinitis pigmentosa occurring in the same family, and accompanied by general imperfections of development. *Obes Res* 3:32-41,1995
5. Schathat AP, Maumenee IH. Bardet-Biedl syndrome and related disorders. *Arch Ophthal* 100:285-288,1982
6. Croft JB, Morrell D, Chase CL and Swift M. Obesity in heterozygous carriers of the gene for the Bardet-Biedl syndrome. *Am J Med Genet* 55:12-15,1995
7. Farag, T.I. and Teebi, A.S Highbincidence of Bardet Biedl syndrome among the Bedouin. *Clin Genet* 36:463-464,1989
8. Mykytyn, K, Nishimura DY, Searby CC, Shastri M, Yen H, Beck JS, et al. Identification of the gene (BBS1) most commonly involved in Bardet-Biedl syndrome, a complex human obesity syndrome. *Nature Genet* 31:435-438,2002
9. Nishimura DY, Searby CC, Carmi R, Elbedour K, Van Maldergem L, Fulton AB, et al. Positional cloning of a novel gene on chromosome 16q causing Bardet-Biedl syndrome (BBS2). *Hum Molec Genet* 10:865-874, 2001
10. Pasqualato S, Renault L, Cherfils J: Arf, Arl, Arp and Sar proteins: a family of GTP-Binding proteins with a structural device for 'front-back' communication. *EMBO Rep* 3:1035-1041, 2002
11. Mykytyn K, Braun T, Carmi R, Haider NB, Searsby CC, Shastri M, et al. Identification of the gene that when mutated, causes the human obesity syndrome BBS4. *Nature Genet* 28:188-191, 2001
12. Young TL, Penney L, Woods MO, Parfrey PS, Gren JS, Hefferton D, et al. A fifth locus for Bardet-Biedl syndrome maps to chromosome 2q31. *Am J Hum Genet* 64:900-4,1999
13. Katsanis N, Beales PL, Woods MO, Lewis RA, Green JS, Parfrey PS, et al. Mutations in MKKS cause obesity, retinal dystrophy and renal malformations associated with Bardet-Biedl syndrome. *Nat Genet* 26:67-70, 2000
14. Badono JL, Ansley SJ, Leitch CC, Lewis RA, Lupski JR, Katsanis N. Identification of a novel Bardet-Biedl syndrome protein, BBS7, that shares structural features with BBS1 and BBS2. *Am J Hum Genet* 72:650-658, 2003
15. Ansley SJ, Badano JL, Blacque OE, Hill J, Hoskins BE, Leitch CC, et al. Basal body dysfunction is a likely cause of pleiotropic

- Bardet-Biedl syndrome. *Nature* 425:628-633, 2003
16. Li JB, Gerdes JM, Haycraft CJ, Fan Y, Teslovich TM, May-Simera H, et al. Comparative genomics identifies a flagellar and basal body proteome that includes the BBS5 human disease gene. *Cell* 117:541-552,2004
 17. Blacque OE, Reardon MJ, Li C, McCarthy J, Mahjoub MR, Ansley S, et al. Loss of *C. elegans* BBS-7 and BBS-8 protein function results in cilia defects and compromised intraflagellar transport. *Genes Dev* 18:1630-1642, 2004
 18. Pazour GJ, Rosenbaum JL. Intraflagellar transport and cilia-dependent diseases. *Trends Cell Biol* 12:551–555, 2000