

Journal of Pediatric Sciences

Role of post-operative radiation therapy in single brain metastasis from clear cell sarcoma in children: a case report with systemic review

Fadoua Rais, Naoual Benhmidou, Ghizlane Rais, Hasnaa Loughlimi, Maghous Abdelhak, Khadija Bellahammou, Fadila Kouhen, Jihan Aarab, Sanaa Elmejjoui, Tayeb Kibdani, Hanan Elkacemi, Nouredine Benjaafar

Journal of Pediatric Sciences 2016;8:e261

DOI: <http://dx.doi.org/10.17334/jps.87709>

How to cite this article:

Rais F, Benhmidou N, Rais G, Loughlimi H, Abdelhak M, Bellahammou K, Kouhen F, Aarab J, Elmejjoui S, Kibdani T, Elkacemi H, Benjaafar N. Role of post-operative radiation therapy in single brain metastasis from clear cell sarcoma in children: a case report with systemic review. Journal of Pediatric Sciences. 2016;8:e261

CASE REPORT

Role of post-operative radiation therapy in single brain metastasis from clear cell sarcoma in children: a case report with systemic review

Fadoua Rais¹, Naoual Benhmidou¹, Ghizlane Rais¹, Hasnaa Loughlimi¹, Maghous Abdelhak¹,
Khadija Bellahammou², Fadila Kouhen¹, Jihan Aarab¹, Sanaa Elmejjoui¹, Tayeb Kebdani¹,
Hanan Elkacemi¹, Noureddine Benjaafar¹.

¹Department of Radiotherapy, National Institute of Oncology, Mohammed V University;

²Department of Oncology, National Institute of Oncology, Rabat, Morocco

Abstract:

Brain metastasis is relatively uncommon in children with solid tumors. Less than 4.5% of children with solid tumors will develop parenchymal intracranial metastasis, whereas brain relapse of clear cell sarcoma of the kidney occurs in about 5% of cases during the follow-up. The prognosis of patient with relapsed clear cell sarcoma of the kidney (CCSK) is generally reserved with a 5-year event-free survival of 18%, and a 5-year overall survival of 26% in one of the largest series. However, several cases of solitary brain metastasis were successfully managed by a multimodality aggressive approach including radiation therapy, with long term survivals reported in the literature data. Because of the relative rarity of this particular entity, information regarding management and prognosis are still missing. Through the report of a rare case of a young child with isolated cerebellar relapse of CCSK treated by a multimodality approach with a summary literature review, we try to emphasize the role of post-operative radiation therapy in the management of this rare entity.

Keywords: Pediatric, Clear cell sarcoma, Kidney, Brain metastasis, radiation therapy.

Corresponding author: Fadoua Rais, Resident on Radiation Therapy, National Institute of Oncology, Mohamed V University in Rabat. Morocco
e-mail: fadouarais@gmail.com

Introduction

Brain metastasis is a common oncologic problem in adults but is relatively uncommon in children with solid tumors. In fact, approximately 25–35% of all adult cancer patients with solid tumors will develop parenchymal intracranial metastasis whereas only 2.5% to 4.5% of children will do [1- 5]. Brain metastasis of clear cell sarcoma of the kidney occurs in less than 5% of cases during the follow-up [6, 7]. Because of the relative rarity of this particular entity, information regarding management and prognosis are still missing. Trough the report of

a new case of infratentorial single metastasis of clear cell sarcoma of the kidney in a young child, we try to illuminate the role and modalities of radiation therapy in the management of this rare entity.

Case report

A 2-year-old boy was evaluated on October 2011 for a 1-month history of abdominal distention with swelling of the left lumbar fossa. Abdominal ultrasound objectified a large renal mass, measuring 14 cm in diameter well limited

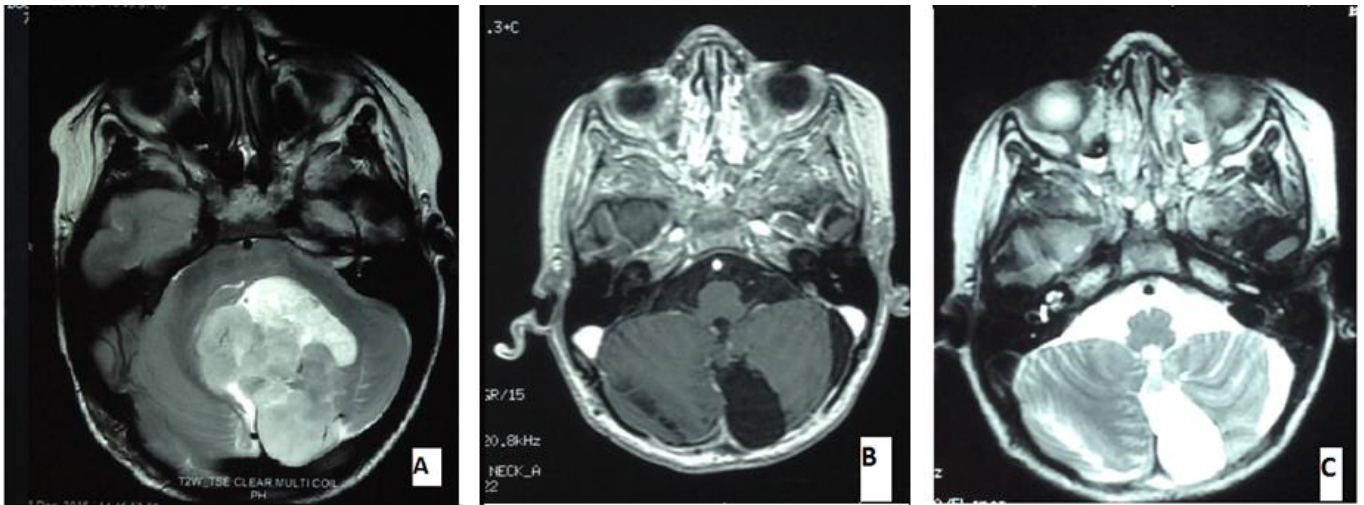


Figure 1. (A) MRI- CT Scan of the brain demonstrating a posterior fossa (Vermian) expansive process, with mass effect on V4. (B, C) Fluid cavity of left cerebellar hemisphere with T1 hypointense and T2 hyperintense signal, not enhanced after gadolinium injection, measuring 24x20 mm corresponding to postoperative modifications and without sign of residual tumor.

associated with renal hilum and para aortic lymph nodes. Metastatic workup revealed an isolated metastatic lesion of the left iliac bone. A diagnosis of metastatic Wilms tumor was retained on the basis of clinical and radiological features. Patient received neoadjuvant chemotherapy according to the SIOP protocol 93-01 and then a resection of the abdominal mass was achieved. A definitive diagnosis of clear cell sarcoma of the kidney (CCSK) was established on histological findings. Post-operatively, he benefited from a risk- adapted chemotherapy (consisting in 34 weeks of chemotherapy according to the protocol ICED: ifosfamide, carboplatine, etoposide and doxorubicine) and radiation therapy to the iliac bone at the dose of 14.4 Gy in 8 fractions. Eleven months after the diagnosis, he completed his treatment with no evidence of abdominal disease and stabilization of the metastatic bone lesion. A regular monitoring was done without signs of relapse until October 2015, where the child experienced a cerebellar syndrome with loss of balance, incoordination and vomiting. A brain MRI objectified a solitary cerebellar mass without sign of any other lesion in the complementary metastatic workup (Fig 1). He subsequently underwent a gross total resection of

the mass with histological confirmation of the diagnosis of a single brain metastasis of CCSK.

Postoperative chemotherapy (based on carboplatin and etoposide) and radiation of the posterior fossa to the dose of 30 Gy in 15 fractions and 20 Gy in 10 fractions to the tumor bed were implemented (Fig 2). Currently, the child is alive in complete remission 9 months after the brain relapse (Five years after the original cancer diagnosis).

Discussion

Clear cell sarcoma of the kidney (CCSK) is an uncommon pediatric renal malignancy, representing about 3% of renal tumors in childhood. It is known for its predilection to spread to bone, but it also metastasizes to other sites including the brain in approximately 4% of cases [6, 8]. The most recent reports from the International Society for Pediatric Oncology (SIOP) and the National Wilms Tumor Study Group (NWTSG) suggest an elevation of the incidence of brain metastasis of CCSK, surpassing that of bone involvement. That fact is probably due to the use of more efficient chemotherapy regimens allowing better tumor control rates at sites outside the blood-brain

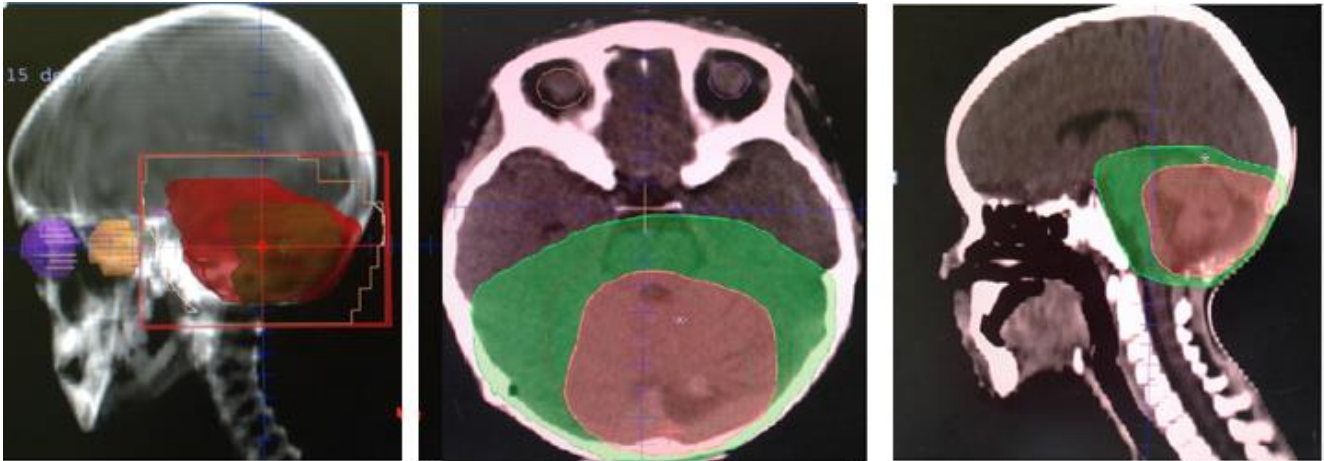


Figure 2. External beam conformal radiotherapy targeting the posterior fossa and the tumor bed by 4 oblique and 1 posterior fields

barrier, therefore selecting the brain as the first site of recurrence [7, 9 and 10]. CCSK differ from Wilms tumors (WT) by their higher rate of relapses (16%), later occurrence, and higher proportion of bone and brain metastases [7, 11].

Brain is an uncommon site of metastasis in children with a diagnosis of sarcoma or kidney tumors and is most often associated with concurrent distant disease, as in our case. In a retrospective series of 611 children treated at the Iowa University, Paulino et al reported 30 cases (4.9%) of brain metastasis from several primaries : sarcoma, neuroblastoma and only 1 case of metastatic Wilms tumor (WT) (1% of all WT registered), whereas no case of CCSK was noted over an extended period of 35 years [5].

Solitary posterior fossa metastasis is even rarer. Few cases were reported in the literature. In the series from Paulino et al, frontal lobe was the most common site of solitary metastasis, whereas cerebellar lesion was noted in only 2 cases (6%). In the two cases, the infratentorial metastasis was revealed by a cerebellar syndrome with loss of balance, incoordination and vomiting such as in our case [5].

Radulescu et al. reported a multicenter retrospective series of 8 children with recurrent CCSK involving the brain [8]. The recurrence occurred with a median time of 24.5 months (12 to 53 months), 4 of the patients relapsed with a single metastasis (none of them in the posterior

fossa) and 4 with multiple metastases. All patients received a combination of surgery and chemotherapy. RT was administered in all 6 surviving patients (post-operatively in 5 cases). Among these patients, 3 received WB radiation with a boost to the tumor and 3 received focal brain radiation. The total dose to the tumor ranged from 30 to 55 Gy. All patients who received RT achieved a complete response and were alive without evidence of disease with a median time after diagnosis of brain metastasis of 30 months (range from 24 to 71 months). The long-term survivor (about 6 years) in this report received focal RT to the tumor bed at the dose of 45Gy after gross total resection and achieved a durable complete response [8].

Gooskens et al. reported a series of 37 relapse among 237 CCSK treated on the SIOP and AIEOP (Associazione Italiana Ematologia Oncologia Pediatrica) trials, where 13 cases were located only in the brain. Successful salvage treatment, including complete resection, post-operative RT and chemotherapy (with stem cell transplant in one case), was reported in 3 cases with a median complete remission time of 58 months after brain relapse [7].

Because of the small number of patients in these series, no consistent conclusions regarding the relative contributions of surgery, chemotherapy and RT to the treatment of brain metastasis of CCSK can be established. Also optimal doses and fields of RT cannot be discerned [7,8].

Moreover, there is no standard RT regimen for brain metastasis in children. Several protocols of external beam RT (volumes, doses and fractionations) were reported in the literature.

The volumes irradiated encountered: [5, 8]

-Whole brain (WB) irradiation with or without a boost to the tumor or the tumor bed.

-Partial brain irradiation: with irradiation of the tumor or tumor bed (in supratentorial lesions) or of the posterior fossa (in infra-tentorial lesions).

- Cranio-spinal irradiation: in some cases with spread to the CSF.

The most prescribed dose of RT to the WB is 30 Gy with several fractionations used (10, 15 or 20 fractions). Doses ranged from 9 Gy in 3 fx to 50 Gy in 25 fx. A supplement of dose to the gross tumor volume (GTV) of 20 Gy and to the tumor bed of 6 to 20 Gy was delivered in several cases. However, in the cases of cranio-spinal irradiation the dose was 35 Gy in 14 fractions. Nevertheless, RT dose was not a significant prognostic factor for survival in the series reported by Paulino et al [5, 8].

The optimal treatment for children presenting with brain metastasis is also not clearly defined in the literature. Patients treated with RT for brain metastasis seem to have a better freedom from neurologic progression rate than those who did not receive RT [5]. In Paulino et al report, the best prognosis was noted in patients with post-operative RT (median survival of 8 months), followed by that noted in patients who received RT alone or with chemotherapy (median survival ranged from 4 to 6 months). On multivariate analysis, only the use of RT was found to positively impact brain progression free survival (9 months with RT Vs 2 months without RT) [5].

Patients with solitary brain metastasis are the best candidates for long-term survival, so it seems reasonable that a multimodality approach including resection, postoperative RT, and chemotherapy with or without stem cell rescue be offered to this subset of patients especially in cases with good performance status. In fact,

among 9 cases of long-term survivors with brain metastasis (5 to 11 years after diagnosis of brain metastasis) reported in the literature, 8 have solitary intra-cranial lesion. Multi-modality treatment was achieved in almost all these cases, with RT done in 8 cases, post-operatively in 6 cases and exclusively in 2 other cases [4, 5, 12-17]. Our patient benefited from multi-modality treatment including complete resection, post-operative radiotherapy and chemotherapy and still alive without evidence of disease.

Also, enhancing local brain control by post-operative RT seems to play a primordial role in the consolidation of a second complete remission (CR). In fact, Gooskens et al reported in their series a second CR in about half of patients but more than two-third of them subsequently developed a second recurrence, indicating that consolidation of a second CR seems to be a challenge in relapsed CCSK patients [7].

Despite the dramatically improvement in prognosis of patients with CCSK due to treatment intensification (especially by the use of doxorubicin) with an overall survival of 69%, the prognosis remains poor in metastatic sitting. In fact, in one of the largest series of 351 cases of CCSK, the specific-survival rate in patients receiving doxorubicin reaches more than 97 % in stage I while it still less than 50% in few patients with metastatic disease (stage IV) [15,16]. In addition, the 5-year event-free survival after relapse was estimated at 18%, and the 5-year overall survival at 26% in a recent large combined series of relapsed CCSK treated in SIOP and AIEOP study [7].

Conclusion

Clinicians should be aware of the likelihood of brain metastases during the monitoring of patients treated for CCSK. Brain imaging (CT and/or MRI scans) might be considered in selected cases of patients with neurologic symptoms. Intensive treatment including at best post-operative RT aiming for local brain control would be of great benefit to enhance neurologic progression free survival.

References

1. Posner JB. Brain metastases: A clinician's view. In: Weiss L, Gilbert HA, Posner JB, editors. Brain metastases. Boston: GK Hall, 1980: p. 2–29.
2. Boring CC, Squires TS, Tong T. Cancer Stat 1992;42:19–38.
3. Tasmiroglu E, Patchell RA. Cerebral metastases in childhood malignancies. Acta Neurochir 1997;139:182–187.
4. Bouffet E, Doumi N, Thiesse P, et al. Brain metastases in children with solid tumors. Cancer 1997;79:403–410.
5. Arnold C, Paulino, Thanh X, Nguyen, Jerry L, Barker: Brain metastasis in children with sarcoma, neuroblastoma, and wilms' tumor, Int. J. Radiation Oncology Biol. Phys., 2003; 57:177–183.
6. Pedram Argani et al. Clear Cell Sarcoma of the Kidney: A Review of 351 Cases From the National Wilms Tumor Study Group Pathology Center. The American Journal of Surgical Pathology 2000;24: 4–18,.
7. Gooskens S L et al. Treatment and outcome of patients with relapsed clear cell sarcoma of the kidney: a combined SIOP and AIEOP study. British Journal of Cancer 2014; 111, 227–233.
8. Radulescu V C. et al. Treatment of Recurrent Clear Cell Sarcoma of the Kidney With Brain Metastasis. Pediatr Blood Cancer 2008;50:246–249.
9. Seibel NL, Sun J, Anderson JR, et al. Outcome of clear cell sarcoma of the kidney (CCSK) treated on the National Wilms Tumor Study-5 (NWTS). Proc Am Soc Clin Oncol 2006;24:502S.
10. Furtwangler R, Reighard H, Beier R, et al. Clear-cell sarcoma (CCSK) of the kidney-results of the SIOP 93-01/GPOH trial. Pediatr Blood Cancer 2005;45:423.
11. Hempel L, Sauerbrey A, Zintl F, et al. Successful management of a child with clear cell sarcoma of the kidney (CCSK) and multifocal bone metastases at diagnosis. Med Pediatr Oncol 2003; 41:97–99.
12. Marina NM, Pratt CB, Shema SJ, et al. Brain metastases in osteosarcoma: Report of a long-term survivor and review of the St. Jude Children's Research Hospital experience. Cancer 1993;71:3656–3660.
13. Parasuraman S, Langston J, Rao BK, et al. Brain metastases in pediatric Ewing's sarcoma and rhabdomyosarcoma: The St. Jude Children's Research Hospital experience. J Pediatr Hematol Oncol 1999;21:370–377.
14. Lowis SP, Foot A, Gerrard MP, et al. Central nervous system metastasis in Wilms' tumor: A review of three consecutive United Kingdom trials. Cancer 1998;83:2023–2029.
15. Wexler LH, DeLaney TF, Saris S, et al. Long-term survival after central nervous system relapse in a patient with osteosarcoma. Cancer 1993;72:1203–1208.
16. Wronski M, Arbit E, Burt M, et al. Resection of brain metastases from sarcoma. Ann Surg Oncol 1995;2:392–399.
17. Deutsch M, Orlando S, Wollman M. Radiotherapy for metastases to the brain in children. Med Pediatr Oncol 2002;39:60–62.