

Case Report / Olgu Sunusu**Pseudoventricular tachycardia****Psödoventriküler taşikardi**Murat Ayan¹, Inan Beydilli², Kerem Ozbek³, Ahmet Inanir⁴, Durdane Bekar⁵**ÖZET**

Tremor klinik uygulamada elektrokardiyografik artefaktların sık sebeplerinden biridir. Bizim olgumuzda 64 yaşında erkek hasta yakınları tarafından acil servisimize bayıla yazma, baş dönmesi ve kusma yakınması ile getirildi. Hastanın bilinci açık ancak huzursuz görünümde idi. Fizik muayenesi ellerde kaba tremor dışında tamamen normal idi. İlk değerlendirmenin ardından çekilen 12 derivasyonlu EKG de polimorfik ventriküler taşikardi ile uyumlu görünüm tespit edildi. EKG ayrıntılı olarak değerlendirildiğinde derivasyon II de ritmin sinüs ritmi olduğu görüldü. Hastanın baş dönmesi, bayıla yazma ve kusma yakınması tekrar değerlendirildiğinde hasta periferik vertigo olarak değerlendirildi. Acil servis gibi yoğun ve hekimlerin hızlı karar vermesi gerektiği alanlarda hekimler EKG değerlendirirken artefaktlar gibi tanıyı zorlaştırabilecek nedenleri de göz önünde bulundurmalıdır. Böylelikle hastalar gereksiz tedavi ve girişimlere maruz kalmazlar.

Anahtar kelimeler: Psödoventriküler taşikardi, Parkinson Hastalığı, EKG

ABSTRACT

Body tremor is the most common cause resulting in electrocardiographic artifact in clinical practice. In our case 64-year-old male patient was brought by the relatives of our emergency department with complaints of dizziness, pre syncope and vomiting. This patient was conscious but in a restless view. Physical examination was completely normal except coarse tremor in the hands. After first evaluation, 12 lead ECG was performed. The ECG may be compatible with the appearance of polymorphic ventricular tachycardia was detected. In Carefully re-evaluation of ECG, rhythm of DII derivation, were found to be normal. Reevaluated in terms of dizziness, near syncope and vomiting the patient was diagnosed with peripheral vertigo. However, intensive and a needed to decide quickly areas such as emergency room, evaluation of ECG should be able to distinguish between artifacts carefully and physicians should consider situations that may cause artifacts. Thus, patients do not expose to unnecessary treatment and invasive proceed.

Key words: Pseudoventricular tachycardia , Parkinson Disease, ECG

¹ Department of Emergency Medicine, Gaziosmanpaşa University, Faculty of Medicine Tokat, Turkey

² Department of Emergency Medicine, Education and Research Hospital, Kayseri, Turkey

³ Department of Cardiology Gaziosmanpaşa University, Faculty of Medicine Tokat, Turkey

⁴ Department of Physical therapy, Gaziosmanpaşa University, Faculty of Medicine Tokat, Turkey

⁵ Department of Neurology, Gaziosmanpaşa University, Faculty of Medicine Tokat, Turkey

Corresponding Author:
Dr. Murat AYAN
Gaziosmanpaşa University,
Faculty of Medicine
Department of Emergency
Medicine Tokat

Phone:
+90 356 212 95 00 /3420

Mobile Phone:
+90 505 795 41 54

E-mail:
ayan421975@windowlive.com

Başvuru Tarihi/Received :
25-09-2011
Kabul Tarihi/Accepted:
26-12-2011

Introduction

Artifacts on electrocardiograms, even experienced cardiologists or electrophysiologists could be mis-interpreted as ventricular tachycardia (VT) (1). Artifacts on the ECG can interpret in favor ventricular tachycardia by emergency medicine physicians, especially needed to decide to intervene in cases of emergency. Patients who have electrocardiographic artifacts recognized as VT may be subjected to a variety of unnecessary diagnostic or therapeutic procedures, including prescription of anti-arrhythmic drugs, direct-current cardioversion, cardiac catheterization and even implantation of cardiac devices (1). Body tremor is the most common cause resulting in electrocardiographic artifact in clinical practice (2). We report a case of a pseudo ventricular tachycardia due to tremor, patient with admitted to the emergency department with dizziness, near syncope and vomiting complaint.

Case

64-year-old male patient was brought by the relatives of our emergency department with complaints of new onset dizziness, near syncope and vomiting. He was conscious but in a restless view. His vital signs were stable. Physical examination was completely normal except coarse tremor in the hands. After first evaluation, 12 lead ECG was performed. The ECG may be compatible with the appearance of polymorphic ventricular tachycardia was detected (Fig 1). Cardiology consultation was requested and amiodarone infusion was planned to start. In Carefully re-evaluation of ECG, rhythm of DII derivation, were found to be normal (Fig 2). Repeated ECGs obtained during the tremor-free period were normal. In his medical history learned that has a Parkinson disease since 15 year. The patient re-evaluated in terms of dizziness, near syncope and vomiting. The patient was diagnosed with peripheral vertigo. After the symptomatic treatment, the patient showed complete recovery.

Discussion

Artifacts on electrocardiograms may be misdiagnosed as various kinds of cardiac arrhythmias (1). Body tremor is the most common cause resulting in electrocardiographic artifact in clinical practice (2). These electrocardiographic changes may cause unnecessary panic and increase the use of healthcare resources (3). ECG evaluation of hemodynamically stable patients, such as the tremors external physical factors should be considered that can cause artifacts (4). When ventricular arrhythmias are detected in patients without clinical signs compatible, physicians should be considered these artifacts (5). Some authors defined some criteria for differentiation of tremor-induced pseudo-VT (6). One of this criteria is; in tremor induced pseudo-VT, one of the frontal leads (leads I, II, and III) may present with sinus rhythm with normal P, QRS, and T waves ("Sinus" sign) this is because one of upper limbs may be free from tremor in certain patients. In our case in ECG derivation (DII) presents sinus rhythm. This case high lights the importance of correlating ECG findings with history and clinical examination and of using 12 lead ECGs for rhythm interpretation especially to confirm consistence of arrhythmias in all leads.

Conclusion

In elderly patients with dizziness, syncope and vomiting like non-specific symptoms, an emergency physician should keep in mind that it may be based on cardiac or neurological factors. Initial assessments, should be obtained 12 lead ECG which can be accessed quickly and easily. However, intensive and a needed to decide quickly areas such as emergency room, evaluation of ECG should be able to distinguish between artifacts carefully and physicians should consider situations that may cause artifacts. Thus, patients do not exposed to unnecessary treatment and invasive proceed

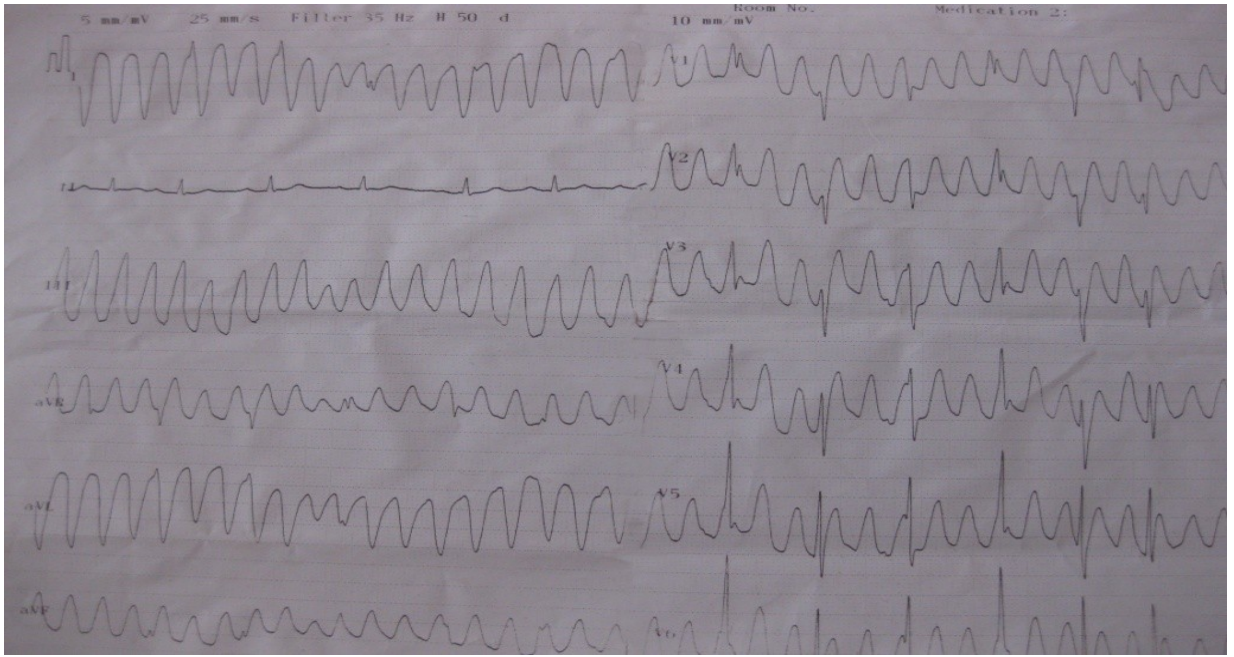


Figure 1.

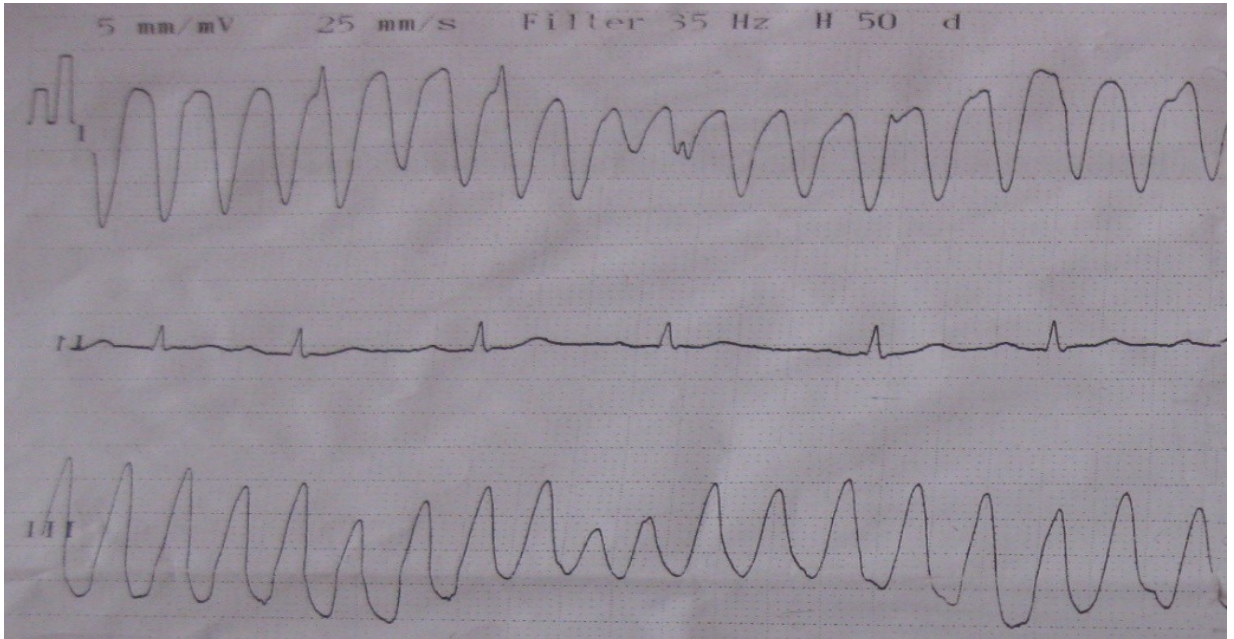


Figure 2.

References

1. Knight BP, Pelosi F, Michaud GF, Strickberger SA, Morady F. Clinical consequences of electrocardiographic artifact mimicking ventricular tachycardia. *N Engl J Med.* 1999;341:1270-1274
2. Krasnow AZ, Bloomfield DK. Artifacts in portable electrocardiographic monitoring. *Am Heart J.* 1976;91:349-357
3. Littmann L, Monroe MH. Electrocardiographic artifact. *N Engl J Med.* 2000;342:590-591; author reply 592
4. Srikureja W, Darbar D, Reeder GS. Tremor-induced ECG artifact mimicking ventricular tachycardia. *Circulation* 2000;12;102(11):1337-8
5. Jafary FH. The "incidental" episode of ventricular fibrillation: a case report. *J Med Case Reports.* 2007;30;1:72)
6. Huang CY, Shan DE, Lai CH, Fong MC, Huang PS, Huang HH, Lin SJ, Chiang CE. An accurate electrocardiographic algorithm for differentiation of tremor-induced pseudo-ventricular tachycardia and true ventricular tachycardia. *Int J Cardiol.* 2006;111:163-165