

Sağ Common ve Sol İnternal Karotis Arter Stenozu

Right Common Carotid and Left Internal Carotid Artery Stenosis

Mehmet Salih Aydın¹, Ekrem Karakas²

¹Harran Üniversitesi, Faculty of Medicine, Department of Cardiovascular Surgery, Sanliurfa, TURKEY

²Harran Üniversitesi, Faculty of Medicine, Department of Radiology, Sanliurfa, TURKEY

Yazışma adresi: Mehmet Salih AYDIN, Kalp Damar Cerrahisi Anabilim Dalı, Harran Üniversitesi Tıp Fakültesi Yenişehir Kampüsü 63000, Şanlıurfa Tel: 0414-3182393, Faks no: 0414-3182393, E-mail: drmsalihaydin@gmail.com

Geliş tarihi / Received: 15.03.2013

Kabul tarihi / Accepted: 05.06.2013

Özet: Bu görüntü sunumunda sağ common karotis ve sol internal karotis arteri tam tıkalı koroner arter hastalıklı hastayı sunduk.

Abstract: In this image, we present coronary artery disease patient with Right Common Carotis and Left Internal Carotis Artery Stenosis.

A 61-year-old male patient was admitted with chest pain and dispne of two-days history. . On physical examination his blood pressure, heart rate, and axillary temperature were 135/80 mmHg, 96 beats/min, and 37.4 °C, respectively. Cardiac auscultation showed reduced heart sounds without any murmur but carotid artery murmur was heard. A 12-lead electrocardiogram revealed reduced QRS amplitude (<10 mm) in both extremity and precordial leads,. Coronary angiography revealed critical coronary artery stenosis. . Then carotid and vertebral ultrasound fallowing MRI (Magnetic Resonans İmaging) angiography showed that total occlusion of Right Common Carotis and Left İnternal Carotis Artery (Figure 1). Carotid artery disease has been found in half of patients of coronary artery disease (1). Therefore, any system with symptoms due to atherosclerosis patients atherosclerosis in other locations must be checked and noninvasive methods for this purpose as the more common used (2). The intersting point of this case patient patient hasnt any cerebrovascular events with these lesions. In conclusion carotid artery disease in elder patients with coronary artery disease should not be forgotten.

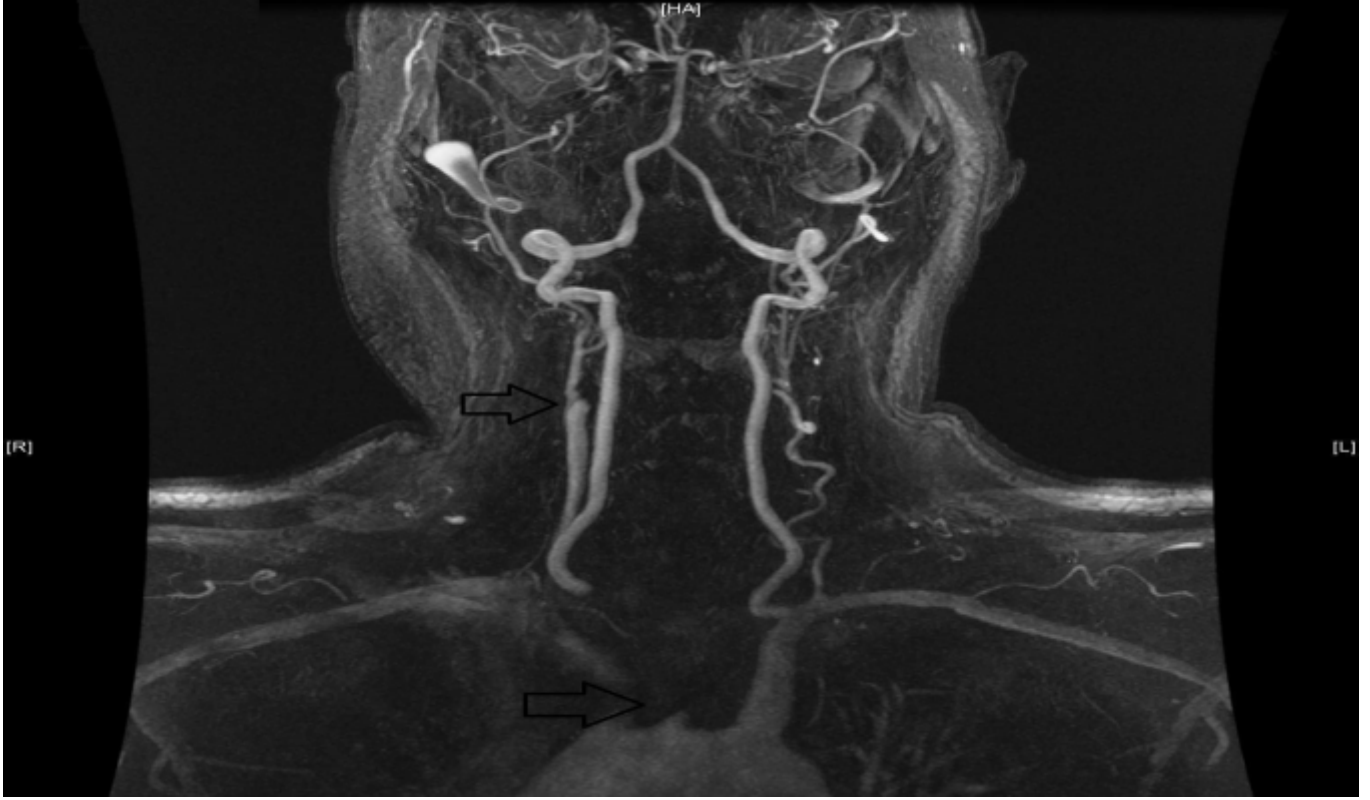


Figure 1: Total occlusion of right common and left internal carotid artery stenosis

Yazarlarla ilgili bildirilmesi gereken konular (Conflict of interest statement) : Yok (None)

References

1) Yapıcı F, Gürer O, Enç Y, Çınar B, Güney MR, Yapıcı N et al. Combined Surgery For Coronary And Carotid Artery Disease: Management And Results Turkish J Thorac Cardiovasc Surg 2002;10:229-34.

2) Köksal C, Sarıkaya S, Özcan V, Zengin M. Vascular Surgery Concomittant To The Coronary Revascularization. Cerrahpaşa J Med 2003;34:127-31.