

# The Rupture Of A Renal Hydatid Cyst Into The Renal Pelvis: Macroscopic Hydatiduria

Halil CIFTCI MD<sup>1</sup>, Abdullah OZGONUL MD<sup>2</sup>, Murat Savas, MD<sup>1</sup>, Ayhan VERIT MD<sup>1</sup>, Ercan Yeni, MD<sup>1</sup>  
Harran University Medical School, Depts. of Surgery<sup>2</sup> and Urology<sup>1</sup>, Tr-63100 Sanliurfa TURKEY

## Abstract

Cyst hydatid disease is a parasitic infestation caused by *Taenia echinococcus*, seen most often in sheep-rearing areas. We presented a woman with renal hydatid cysts with symptoms of ureteral colic and appearance of grape-like material in her urine. Hydatid disease can also be presented with ureteral colic and should be considered in differential diagnosis.

**Key words:** Hydatid disease, Renal hydatid cyst, renal colic, ureteral colic, hydatiduria

## Renal Pelvise Yırtılan Renal Hidatik Kist: Makroskobik Hidatüri

### Özet

Kist hidatik etkeni *Taenia echinococcus* adlı bir parazit olup özellikle koyun yetiştirilen bölgelerde sık görülmektedir. Biz kliniğimize renal kolik yakınması ile gelen ve idrarında parazit yumurtaları görülen bir olguyu sunduk. Kist hidatik bir çok klinik tanyla ortaya çıktığı gibi üreteral koliklerin ayırıcı tamsında düşünülmelidir.

**Anahtar kelimeler:** Kist hidatik,renal kist hidatik, renal kolik, üreteral kolik, hidatüri.

## Introduction

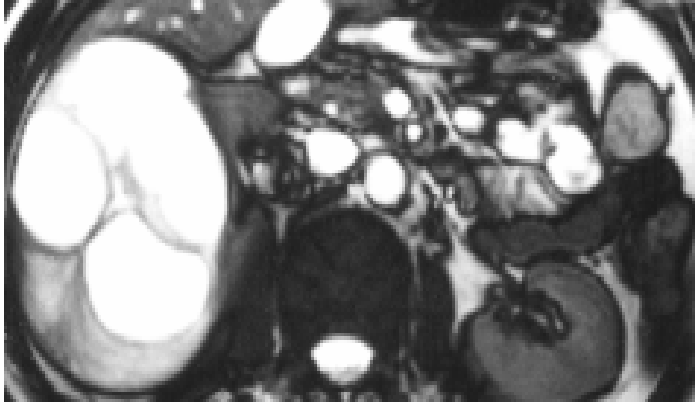
Cyst hydatid disease is a parasitic infestation, widely distributed zoonosis caused by the larval stage of *Taenia echinococcus* (tapeworm), seen most often in sheep-rearing areas and endemic in parts of Africa, Latin America, Mediterranean and Turkey especially southeast region. Humans are the end or accidental intermediate hosts. The larval forms penetrate the intestinal mucosa, migrate into the blood and lymphatic stream, and transported most often to the liver, lungs and brain however Hydatid disease of the urinary tract is uncommon accounting for only 2 % of all such cases (1-2). Renal hydatid cysts usually reside asymptomatic for years. Opening of renal hydatid cyst into renal pelvis and collecting system results in acute renal colic and hydatiduria. However, most of the hydatiduria cases do not have renal colic (3). Hydatiduria is urinary excretion of microscopic scolexes or macroscopic membranes and / or daughter cysts. We are presenting a uncommon case with complaints of renal and ureteral colic secondary to opening of hydatid cyst into renal pelvis and urinary excretion of daughter cyst.

### Case report

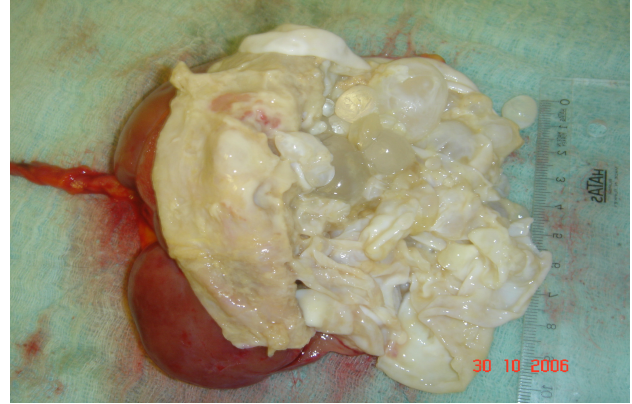Forty six year old women patient administered our clinic with complaints of right renal and ureteral colic and occasional appearance of grape-like material in urine. Medical history was insignificant apart from the diagnoses of renal cyst two years

previously by radiology, however she did not admit to the further evaluation. A random urine sample of the patient found to contain ruptured cysts. The patient was evaluated radiologically by plain radiography, ultrasonography and computerize tomography. No calcification or urolithiasis was seen in renal and ureteral lodges by plain radiography. Ultrasonography demonstrated a multicystic lesion of 9 cm x 7cm x 6cm size containing daughter cysts and multiple septations. Computerize tomography showed a lesion containing solid and cystic compartments, originating from upper and middle pole and traversing to renal pelvis (Fig.1). Other abdominal organs were evaluated and appearing normal. Based on history of passing of grape-like material in urine and complex cystic lesion in kidney, diagnosis of primary renal hydatid cyst was made. The patient underwent successful right nephrectomy. Prior to operation patient received a 3 week course of albendazole (15mg/kg per day) and continued for two cycles postoperatively. Macroscopic examination of the specimen by vertical excision revealed that the cysts opened to renal pelvis and daughter cysts were found in renal pelvis (Fig.2).

**Fig 1.**



**Fig 2.**



**Fig 1.** Contrast-enhanced abdominal CT image multicystic lesion.

**Fig 2.** Macroscopy of renal specimen. Daughter cysts opened to renal pelvis as grape like macroscopy.

### Conclusions

Hydatid disease often appears by slowly growing cystic mass. Symptoms develop when the cyst enlarges sufficiently to be a space occupying mass. Cysts may be single or multiple, uni- or multiloculated, and thin or thick walled. The diagnosis of hydatid cyst relies on serologic tests and imaging techniques. ultrasonography, computerized tomography, and magnetic resonance. Presence of daughter cysts, membrane detachment and wall calcifications and hydatiduria are specific signs and facilitate differential diagnosis. However, hydatid cysts in unusual localizations with simple cyst appearance may cause serious diagnostic problems (4). The disease may also mimic benign or malignant tumors, single or multiple metastases, abscesses, empyemas, infarcts, and other lesions (5). Renal hydatid cysts may be seen primarily or may be due to direct invasion from neighborin organs like spleen and liver. Renal hydatid cysts are usually solitary and located in upper or lower poles of kidney. The middle portion of kidney is not frequently involved. Renal hydatid cyst may present as nonspecific symptoms. Like renal mass, hematuria, dysuria, pyuria, renal and ureteral colic, persistent fever, urolithiasis or hypertension, though it may be also be asymptomatic (6). However, spontaneous or traumatic rupture of renal hydatid cyst into renal pelvis results in urinary excretion of daughter cysts. This finding is accepted to be pathognomonic for renal hydatid disease (7-9). Urinary passage of daughter cysts is a rare dramatic presentation (10-11). In general, surgery is the

preferred type of treatment in renal hydatid cysts. However, there are also some cases in literature that have healed only by medical (albendazole) treatment (10). Renal conservative surgery is possible even for large lesions. Cystectomy is the simplest technique and can be followed safely by pedicled omentoplasty to treat residual cavity. Nephrectomy is also electively performed for large lesions when the cyst causes tissue damage by pressure atrophy and in cases with evident communication with the urinary tract (hydatiduria). In conclusion, despite its rarity, hydatid disease should be considered in the differential diagnosis of space-occupying lesions of the urinary tract. In endemic countries, hydatid disease can also present with renal and ureteral colic and should be considered in differential diagnosis.

### References

1. Johnson WD, Johnson CW, Lowe FC. Parasitic disease of the genitourinary system. In: Walsh PC, Retik AB, Vaughan ED, Wein AJ editors Campbell's Urology, 8<sup>th</sup> ed. Philadelphia: Saunders press; 1992. p 743-95.
2. McGreevy PC, Nelson GS. Larval cestode infections. In: Strickland GT editor. Hunter's Tropical Medicine, 7th ed. Philadelphia: Saunders Press; 1991.
3. Unsal A, Cimentepe E, Dilmen, Yenidunya S, Saglam S. An unusual cause of renal colic: hydatiduria. Int J Urol 2001;8:319-21.

4. Engin G, Acunas B, Rozanes I, Acunas G. Hydatid disease with unusual localization. *Eur Radiol* 2000;10:1904-12.
5. Reeder MP. The radiology of tropical disease with epidemiological, pathological and clinical correlation. Baltimore: Williams and Wilkins,; 1981.
6. Tuzun M, Hekimoglu B. Various locations of cystic and alveolar hydatid disease: CT appearances. *J Comput Assist tomogr* 2001;25:81-7.
7. Angulo JC, Lera R, Santana A, Sanches-Chapado M. Hydatid renal abcess: a report of two cases. *BJU Int* 1993;83:1065-66.
8. Gogus C, Safak M, Baltacı S, Turkolmez K. Isolated renal hydatidosis: Experience with 20 cases. *J Urol* 2003;169:186-89.
9. Pedrosa I, Saiz A, Arrazola L, Ferreiros J, Pedrosa CS. Hydatid disease: Radiologic and pathologic features and complications. *Radio Graphics* 2000;20:795-817
10. Odev K, Kilinc M, Arslan A, Aygun E, Gungor S, Durak AC, et al. Renal hydatidosis cyst and the evaluation of their radiologic images. *Eur Urol* 1996;30:40-9.
11. Loiwal V, Gupta P. Hydatiduria. *Indian Pediatr* 2000;37:111-2.

**Corresponding Address:**

Dr. Ayhan Verit  
Harran University, Medical School  
Arastirma ve uygulama hastanesi  
Tr-63100 Sanliurfa TURKEY

**Tel** : 90 414 316 8821

**Fax** : 90 414 315 1181

**e-mail** : averit@harran.edu.tr