

## A CASE OF GANGLIONEUROMA

Dr. Cengiz Erçin<sup>1</sup>, Dr. Kadriye Yıldız<sup>2</sup>, Dr. Konuralp İlbay<sup>3</sup>, Dr. Gökhan Harova<sup>1</sup>, Dr. Ethem Alhan<sup>4</sup><sup>1</sup>From Kocaeli University Faculty of Medicine, Department of Pathology and <sup>3</sup>Neurosurgery, <sup>2</sup>From Karadeniz Technical University, Department of Pathology, and <sup>4</sup>General Surgery

## BİR GANGLİONÖROMA OLGUSU

## ÖZET:

*İzole hamartomatöz ganglionöroma son derece nadir tümörlerden biridir. Adrenal bez ve retroperitoneal bölgede izlenmesine karşın en sık arka mediasten yerleşimlidir. Bu hamartomatöz tümörler nadiren malign odaklar (nöroblastomatöz ya da malign sinir kılıfı tümör alanları) içerebilirler. 17 yaşında kız çocukta üst arka mediasten yerleşimli ganglionöroma olgusunun klinik ve morfolojik bulguları sunulmuştur ve son literatürler gözden geçirilerek tartışılmıştır.*

## SUMMARY

*Isolated hamartomatous ganglioneuromas are extremely rare tumors. Although they may be found in adrenal gland, or retroperitoneal region most of the time, they are localized in the posterior mediastinum. These hamartomatous tumors may rarely possess malignant foci (areas of neuroblastomaous or malignant nerve sheath tumor). An isolated hamartomatous ganglioneuroma in a 17 years old girl localised at upper posterior mediasteneum is presented with Its clinical and morphologic characteristics and is discussed with current literature data.*

*Key Words: Ganglioneuroma, Von Recklinghausen's disease, satellite cells.*

Ganglioneuromas are rarely associated with von Recklinghausen's disease (2). Isolated ganglioneuromas are rare (5, 6). Mediastinal and retroperitoneal ganglioneuromas are usually originated from autonomic ganglia(3). These are benign tumors but in rare cases malignant foci, such as ganglioneuroblastoma, may take place (3, 5). Differential diagnosis of such cases should be obtained by excisional biopsy (3).

The rarity and isolated presence of this tumor and the relations of counterpart are the reasons of this report.

## CASE

Seventeen years-old girl was admitted to our hospital complaining right-lower abdominal pain. She underwent exploratory laparotomy with a preoperative prognosis of acute appendicitis and then appendectomy was performed.

Routine chest x-ray examination (Fig 1) revealed solitary tumoral mass that was 10 cm largest diameter. After the operation, computed tomographic examination confirmed the radiological findings. The mass localised at upper posterior mediastinum (Fig 2). At the level of fourth intercostal space, posterolateral thoracotomy was performed for excision. Tumoral mass that had been fixed by a broad base to the inner soft tissues of the upper mediastineum was excised.

Macroscopic appearance of the excisional biopsy material revealed a tumoral mass with 10 cm diameter and 240 g in weight, and it was soft, fleshy, homogenous pale, gray-white, a fibrillar neoplasm.

Microscopically, tumor composed of fusiform cells grouped in fascicles like neurofibromas. These cells are intermixed with scattered solitary or grouped of mature ganglion cells (Fig 3). The ganglion cells contain 1-2 nucleus and Nissl substances. There was no satellite cell association. Some vacuolated Schwannian cells were recognized. Melanin pigment has not been demonstrated in ganglion cells stained by Fontana method. Flow

cytometric study was performed on formaldehyde fixed and paraffin embedded biopsy material. The DNA content of the tumor was diploid.



Fig 1. Radioopaque mass take place at upper-left chest x-ray.

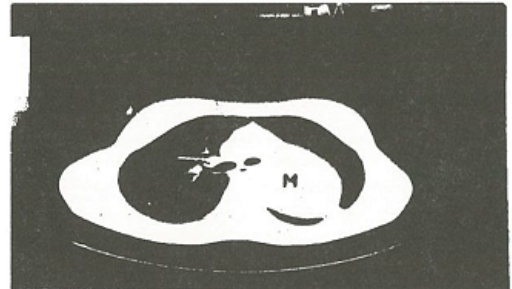


Fig 2. Solid extrapulmoner upper-left mediastinal mass (M) is seen at the chest CT.

## DISCUSSION

Isolated ganglioneuromas are rare (2, 5, 6) and show close relation to autonomic nervous system and its ganglia (3, 6). They usually take place at paravertebral region as it was seen in our case (6). Tumor has remained

dormant since childhood and adolescence. Although as hamartomatous tumor it may contain areas of neuroblastomas (3). So, it should be excised as large as possible and microscopically evaluation should be done in large number of slides, as it was seen in our case. Vacuolated Schwannian cells may indicate immaturity of the tumor so clinical controls should be advised in such cases (3).




Fig 3. Ganglionic cells (G), degenerated schwannian cells are intermixed with fibroblastic elements (I.E. x 250)

Microscopic significance of isolated ganglioneuromas are absence of the satellite cell association of neurons (3, 6, 7). This histological finding is the most useful morphologic criteria that helps to differentiate from von Recklinghausen's disease, binucleated or multinucleated cells are commonly present in ganglioneuromas, but rarely seen in normal ganglions (3, 7). We found all of these characteristics in our case. Immunohistochemical and ultrastructural studies proved that microfilaments which take place in ganglioneuromas were real neurofilaments. This finding indicates their hamartomatous origin.

Nissl granules can be frequently seen (3, 7). Pigment has tinctorial properties of dermal melanin (Fontana-positive) is sometimes present within the ganglion cells and is believed to represent catecholamine products (1). The absence of neuroendocrinologic sign and systemic abnormality are the other characteristics of isolated and hamartomatous ganglioneuromas as we obtained in our case.

DNA diploidy has been also detected by flow cytometry in ganglioneuroma as in numerous histological types of benign soft tissue tumors (4).

#### REFERENCES

1. Enzinger FM, Weiss SW: *Soft tissue tumors Third Edition. Mosby-Year Book, Inc 1995, St Louis, Missouri pp 929-964.*
2. Geffner RL, Hassel CM: *Ganglioneuroma of the skin. Arch Dermatol 1986; 122: 377..*
3. Harkin JC, Reed RJ: *Tumours of the Peripheral Nervous System. Atlas of Tumour Pathology 2nd series fascicle 3 (AFIP) Washington D.C. 1982, pp 144-149.*
4. Kroese MCS, Rutgers DH, Wils IS et al: *The relevance of the DNA index and proliferation rate in the grading of benign and malignant soft tissue tumors. Cancer 1990; 65: 1782.*
5. Lashner BA: *Ganglioneuromatosis of the colon and extensive glycogenic acanthosis in Cowden's disease. Dig Dis Sci 1986; 31: 28.*
6. Özorun Y, Ruacan P, Komsuođlu SP, Özorun A, Aktürk F: *A case of ganglioneuroma. Turkish J urnal of Pediatrics 1987; 29: 135.*
7. Russel DS, Rubinstein LJ: *Pathology of Tumours of the Nervous System. 5th ed. Staughton, London, Melbourne, Auckland: Edward Arnold, a division of Holder, 1989, pp289-307.*