

FINE NEEDLE ASPIRATION CYTOLOGY OF PILOMATRICOMA: A CASE REPORT

Nasuhi Engin AYDİN¹, Bahar MÜEZZİNOĞLU², Güntekin GÜNER³, Sefa MÜEZZİNOĞLU⁴ 1Professor of Pathology, İnönü University Medical School Department of Pathology, 2Staff, İnönü University Medical School Department of Pathology, 3Assistant Professor, İnönü University Medical School, Department of Orthopedics, 4Associate Professor, Kocaeli University Medical School Department of Orthopedics

SUMMARY

Pilomatricoma is a common benign lesion of hair bearing skin. Fine needle aspiration cytology of a pilomatricoma case is presented. In Giemsa stained smears clusters of basalooid cells adjacent to multinuclear giant cells, occasional calcium deposits and a prominent inflammatory background were present. Ghost cells and intermediate cells, reported in many cases, were lacking. Lesion was histologically confirmed. Basolooid cells with foreign body giant cells in an inflammatory background were helpful in excluding malignant lesions.

Key words: Pilomatricoma, fine needle aspiration cytology

PILOMATRİKOMANIN İNCE İĞNE ASPIRASYON SİTOLOJİSİ. OLGU SUNUMU
ÖZET

Pilomatrikoma saçlı derinin sık görülen bir lezyonudur. Bir pilomatrikoma olgusunun ince iğne aspirasyonunu sunuyoruz. Giemsa boyalı yaymalarda inflamatuvar zeminde bazalooid hücre kümeleri, bunların komşuluğunda multinükleer dev hücreler, nadir kalsiyum çöküntüleri görülmüştür. Genelde görülenin aksine gölge hücreleri ve intermedier hücreler bu olguda izlenmemiştir. Lezyon total eksize edilerek histopatolojik incelenmesi yapılmıştır. İnflamatuvar zeminde yabancı cisim dev hücreleri ile beraber görülen bazalooid hücreler malign lezyonlardan ayırıcı tanıda önemlidir.

Anahtar kelimeler: pilomatrikoma, ince iğne aspirasyonu

Pilomatricoma is a common benign lesion of hair bearing skin. It is usually a firm, deep seated, solitary lesion, mostly localized in face, neck and upper extremities. Almost 60% of cases are under twenty years of age (1).

It was first described by Malherbe and Chenantais in 1880 as a "calcifying epithelioma of a sebaceous gland". (2) On its descriptive and histogenetic evolution basophilic cells and shadow cells are found to be in continuum in terms of keratinisation. Numerous tonofilaments are aggregated into thick keratin fibrils, but typically lacking keratohyaline globules (3). This is in striking resemblance to the keratogenous zone of normal hair. Original sebaceous gland origin theory was thus outdated. This resemblance led Forbis and Helwig (4) to propose in 1961 the term pilomatricoma for calcifying epithelioma of Malherbe. Now, both names are used.

Classical cytological findings in a pilomatricoma are deeply basophilic cell aggregates, clusters of degenerative squamous cells, calcific debris, multinuclear giant cells and inflammatory background (5).

We present here a case of pilomatricoma lacking typical cytological components.

CASE REPORT

A 19 year old male presented with a six month history of painless mass on his right forearm. Lesion was subcutaneous, well circumscribed, firm and seemed to be free from overlying skin. On aspiration hardly introduced needle yielded sparse material. Slides that were air dried and stained with May Grünvald Giemsa. On microscopy, aspirate showed abundant cellularity. Predominant cells were deeply basophilic cells slightly larger than lymphocytes either forming clusters or lying singly. They had scanty cytoplasm, fine chromatin pattern with prominent small single nucleoli. Adjacent to these cells there were multinuclear giant cells. (figure 1,2) On

background inflammatory cells with polymorphonuclear predominance were present. Infrequent anuclear squames and small calcium deposits were detected. Any squamous well defined or degenerated cells reminiscent of ghost cells or overt malignant cells were not present.




Figure 1: Clusters of basaloid cells with prominent nucleoli, fine chromatin and scanty cytoplasm. (May Grünvald Giemsa X 100)



Figure 2: Multinuclear giant cell and adjacent clusters of basaloid cells (May Grünvald Giemsa X 400)

Case was discussed with the clinicians, a computerized tomography scan yielded well-bordered subcutaneous lesion with heterogeneous content of calcification and soft tissue. Case was reported to be a benign giant cell lesion consistent with pilomatricoma.

Surgically excised specimen was 3.2 cm in largest diameter. It was well circumscribed, encapsulated and firm. While sectioning hard gritty areas neighboring with soft areas were encountered. Histopathologically, underneath a well-defined connective tissue capsule, fibrous stroma with inflammatory cells and foreign body type multinuclear giant cells were readily evident. Embedded within the stroma irregular clusters of epithelial cells were present. These were composed of peripheral basophilic cells and central ghost cells. (Figure 3) Some nests were almost totally composed of ghost cells. Transition of basaloid cells to ghost cells were frequently abrupt. In some clusters round, eosinophilic keratinous material was seen. Large sheets of amorphous calcified material were frequently replacing the shadow cells. No malignant transformation was detected.

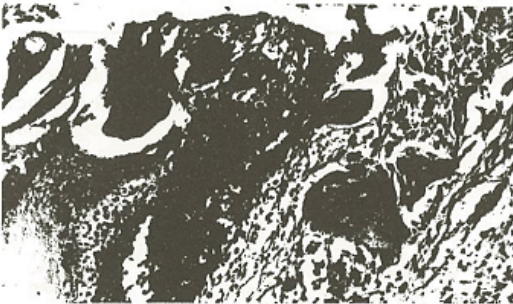


Figure 3: Histologically pilomatricoma composed of abundant ghost cells and stromal multinuclear giant cells (H&E X 100)

DISCUSSION

Pilomatricoma is not an uncommon skin appendage tumor, arising primarily in young age groups. They are usually solitary, though a low percentage (3.5%) of multiple lesions was reported (1).

Head and neck are the primary localizations reported in half of the cases of Lever and Griescmer (6). Following this upper extremity, trunk and rarely lower extremity is involved. Generally it varies in diameter from 0.5 to 3 cm but it may be as large as 5 cm.

Cytologically, most striking findings are reported to be abundant ghost cells in Giemsa stained smears (7). However in other cases they were observed occasionally or unequivocally (8).

Basaloid cells are the most confusing elements in fine needle aspiration (FNA) findings. Scanty cytoplasm, variable nuclear size, hyperchromatism, presence of nucleoli can lead to a misdiagnosis of carcinoma (7,8). Similarly in a study of Gomez-Aracil et al.(9) FNA findings of two pilomatricoma cases were misleading. One case was reported as carcinoma and other as suspected. However, even chromatin distribution, degenerated squamous cells, multinuclear giant cells, calcific debris and

no clearly defined malignant cells should alert for a polymorphic benign lesion rather than a squamous or any other type of carcinoma.

Regarding the prominent basophilic cell component in our case basal cell carcinoma (BCC) might be considered in diagnosis, but one would not expect to see an inflammatory background in a BCC unless ulcerated or infected. Besides, a subcutaneous firm lesion with an intact overlying skin should at first clinically disregard BCC in diagnosis. Additionally, in a typical pilomatricoma case presence of ghost cells and calcific deposits is convincing for exclusion of BCC.

In epidermal appendageal lesions epidermal and trichilemmal inclusion cysts have to be considered. Aspirates of these cysts frequently yield anucleate squames, well-defined squamous cells and inflammatory, giant cell containing background (10). Granulomatous reaction to the keratinized material is important in differential diagnosis but presence of basophilic cells and ghost cells are diagnostically essential for pilomatricomas.

Considering the cylindroma and adenoid cystic carcinoma in differential diagnosis, amorphous material characteristic of hyalinised stroma is totally lacking in pilomatricoma.

In this case prominent basophilic cells with infrequent squames, calcific material and giant cells giant cells in a background of inflammatory component might have been diagnosed as carcinoma. Computerized tomography assisted clinical guidance led us to a proper diagnosis confirmed histologically. One also has to consider any malignant change (11) in a pilomatricoma even totally lacking in a typical FNA smear. Thus total excision is preferred in treatment.

REFERENCES

1. Moehlenbeck FW: Pilomatricoma (calcifying epithelioma): A statistical study. *Arch Dermatol* 1973;108:532-534.
2. Malharbe A, Chenanatais J: Note sur l'epithelioma calcifie des glandes sebaces. *Prog Med* 1880;8:826-28.
3. Lever WF, Lever GS *Histopathology of the skin*. Seventh edition Lippincott Philadelphia, 1990: 587-9
4. Forbis R Jr, Helwig EB: Pilomatricoma (Calcifying epithelioma) *Arch Dermatol* 1961;83:606-618
5. Orell SR, Sterett GF, Walters MN, Whitaker D: *Manual and Atlas of fine needle aspiration cytology*. Churchill Livingstone UK 1992 :304-5
6. Lever WF, Griesever RD: Calcifying epithelioma of Malharbe. *Arch Dermatol Syph* 1949; 59:506-518
7. Unger P, Watson C, Phelps RG, Bernard P. *Fine Needle Cytology of Pilomatricoma (calcifying Epithelioma of Malherbe) Report of a Case Acta Cytol* 1990; 34:847-49
8. Woyke S, Oszewski W, Eichelkraut A: Pilomatricoma: A pitfall in the aspiration cytology of skin tumors. *Acta Cytol* 1982; 26:189-194
9. Gomez-Aracil V, Azua J, San Pedro C, Romero J. *Fine Needle Aspiration Cytologic Findings in Four Cases of Pilomatricoma (Calcifying Epithelioma of Malherbe) Acta Cytol* 1990; 34:842-46
10. Engzell U, Zajicek J: *Aspiration biopsy of tumors of the neck: I. aspiration biopsy and cytologic findings in 100 cases of congenital cysts. Acta Cytol* 1970; 4:51-7
11. Van der Walt JD, Rohlova B: Carcinomatous transformation in a pilomatricoma. *Am J Dermatol* 1984; 6:63-69