

## CASE REPORT

# 24 Months follow-up CEREC CAD-CAM ceramic overlay restorations: Report of 3 cases\*

Mağrur Kazak<sup>α</sup>

*Selcuk Dent J, 2017; 4: 139-143 (Doi: 10.15311/selcukdentj.331009)*

Başvuru Tarihi: 24 Ocak 2017  
Yayına Kabul Tarihi: 27 Temmuz 2017

### ABSTRACT

#### 24 Months follow-up CEREC CAD-CAM ceramic overlay restorations: Report of 3 cases

The objective of this follow-up case series report was to examine the overlay restorations of posterior teeth produced with CAD- CAM technique over a functional period of 24 months. All overlays were made of feldspathic ceramic blocks and cemented with a dual cure adhesive cement. In a single appointment, esthetic and tooth like indirect restorations were produced with CAD-CAM system. Clinical evaluation was done and follow-up after 12 and 24 months showed no secondary caries, fracture, discoloration and loosening of the structural integrity of all overlays. Also, with CAD-CAM system, the patients had convenient, well-fitting and durable indirect restorations.

### KEYWORDS

CAD-CAM, ceramic, overlay, permanent dental restoration

### ÖZ

#### CEREC CAD-CAM seramik overlay restorasyonların 24 aylık klinik takibi: 3 Olgu sunumu

Bu olgu sunumunda, arka bölge dişler için CAD-CAM tekniği ile üretilen overlay restorasyonların 24 aylık takibinin incelenmesi amaçlanmıştır. Tüm overlay restorasyonlar feldspatik seramik bloklardan üretilmiş ve sonrasında restorasyonlar ışıkla ve kendi kendine sertleşen (dual cure) adeziv bir siman ile yapıştırılmıştır. CAD-CAM sisteminin tercih edilmesi ile; tek seansta, estetik ve dişe benzer özellikler taşıyan indirekt restorasyonlar elde edilmiştir. 12 ve 24 aylık klinik takipler sonucunda, restorasyonlarda sekonder çürüğe, kırığa, renklenmeye ve herhangi bir yapısal bütünlükte bozulmaya rastlanmamıştır. Ayrıca, CAD-CAM sistemi ile hastalar kullanışlı, iyi uyum sağlayan ve dayanıklı indirekt restorasyonlara sahip olmuştur.

### ANAHTAR KELİMELER

CAD-CAM, seramik, overlay, daimi diş restorasyonu

Direct restorations of posterior teeth have difficulties in daily dental practice. In addition to these difficulties, if the tooth is non-vital or the loss of hard tissue is too much, restoration of these teeth with direct restoration is even more challenging. As an alternative for direct restorations, indirect restorations can be done using metal, composite, and /or ceramic restorative materials. Indirect ceramic restorations have become very popular for the clinicians in making of inlays, onlays and overlays for the molar teeth. Due to the increased aesthetic expectations by patients, it is likely the most indirect restorations are currently made from ceramic materials.<sup>1</sup> Indirect ceramic restorations can be made by either a dental technician in the laboratory or produced by CAD/CAM systems to make chairside restorations in a single visit. CAD/CAM chairside system allows producing highly aesthetic and reliable restorations while minimizing costs and maximizing patient comfort during treatment session.<sup>2</sup> Nowadays several materials are available for CEREC chairside system.<sup>3</sup> Feldspathic

ceramic is one of the materials which combines the desired aesthetic properties with color stability and biocompatibility for manufacturing of inlays, onlays, overlays, veneers, anterior and posterior crowns.<sup>4</sup>

Therefore, the aim of this case series report was to restore three different patients' four posterior (non-vital and large hard tissue loss) tooth with feldspathic ceramic overlay restorations using CAD-CAM technique.

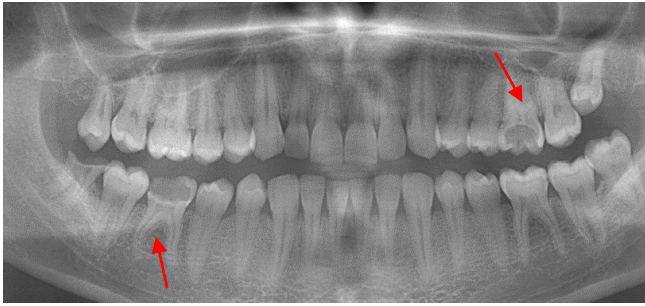## CASE REPORT

### Case 1

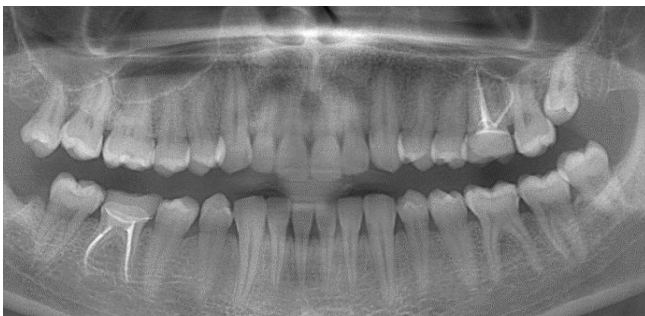A 30-year-old male patient was admitted to Restorative Dentistry Department for the restoration of endodontically treated #26 and #46 (Figure 1). Due to the large hard tissue loss, ceramic overlay restorations were decided to perform (Figure 2, 3, 4, 5A, 5B).

\* 23<sup>rd</sup> European Dental Materials Conference, 27-28<sup>th</sup> August, 2015, Nürnberg, Germany (Poster Presentation)  
European Journal of Prosthodontics & Restorative Dentistry Special Issue P19

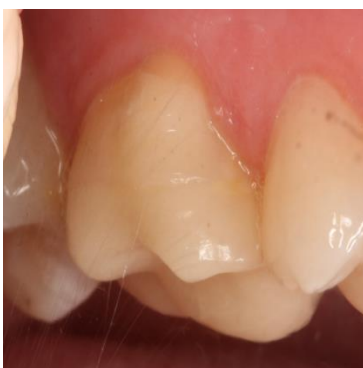<sup>α</sup> Bezmialem Vakif University, Faculty of Dentistry, Department of Restorative Dentistry, Istanbul



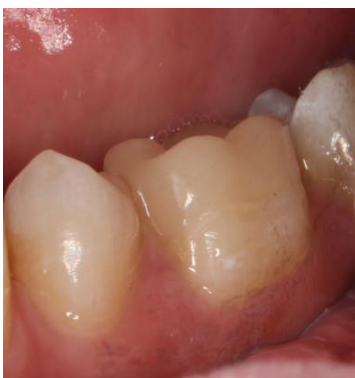**Figure 1.**  
Panoramic radiography of the patient



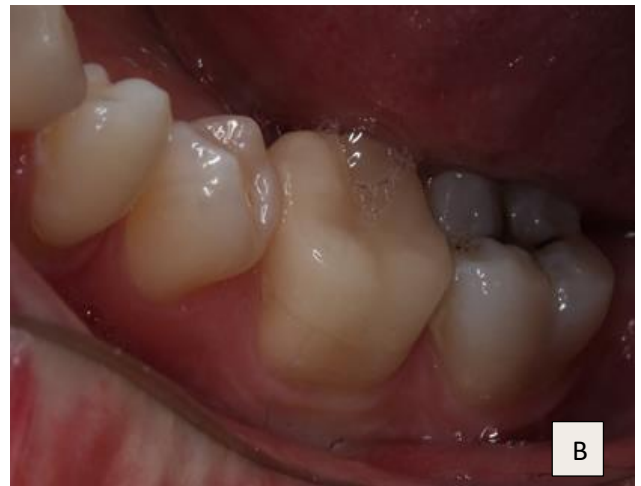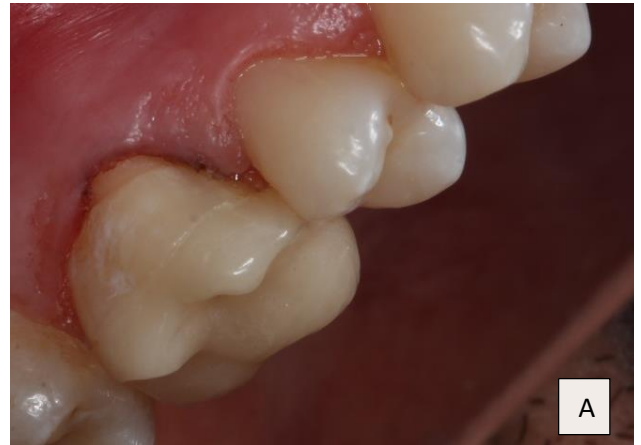**Figure 2.**  
Panoramic radiography of endodontically treated teeth and cemented overlays on #26, #46



**Figure 3.**  
Photo of overlay on #26 at 1 year



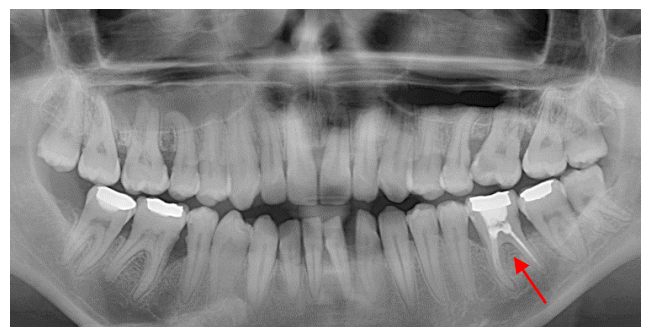**Figure 4.**  
Photo of overlay on #46 at 1 year



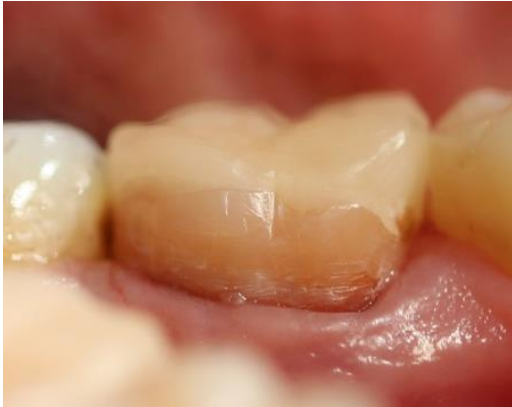**Figure 5.**  
Photos of overlay on A) #26, B) #46 at 2 years

### Case 2

A 26-year-old female patient was presented to Restorative Dentistry Department after the endodontic retreatment of #36 (Figure 6). It was decided to do overlay restoration in order to strengthen the weakened non-vital tooth structure (Figure 7, Figure 8).

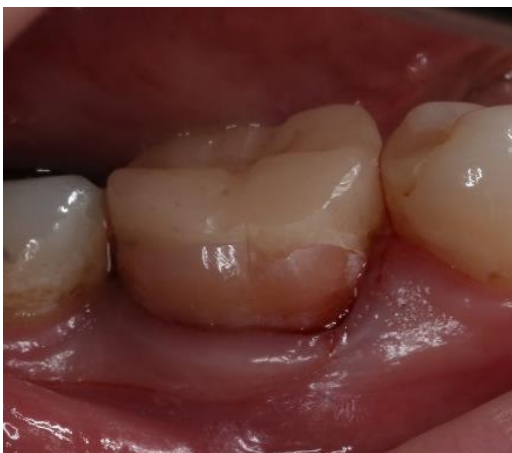

**Figure 6.**  
Panoramic radiography of the patient



**Figure 7.**

Photo of overlay on #36 at 1 year



**Figure 8.**

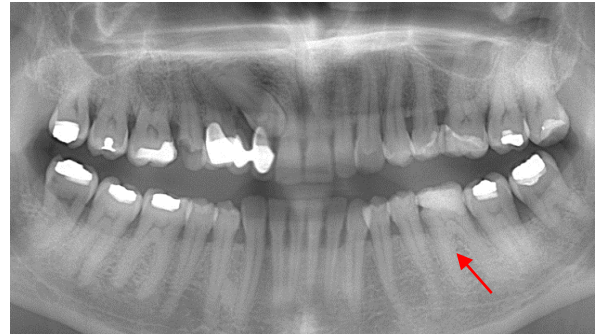
Photo of overlay on #36 at 2 years

### Case 3

A 48-year-old female patient was directed to the Clinic of Restorative Dentistry. The old amalgam restoration was removed and #36 was decided to restore with an overlay restoration due to loss of all cusps (Figure 9, Figure 10, Figure 11).

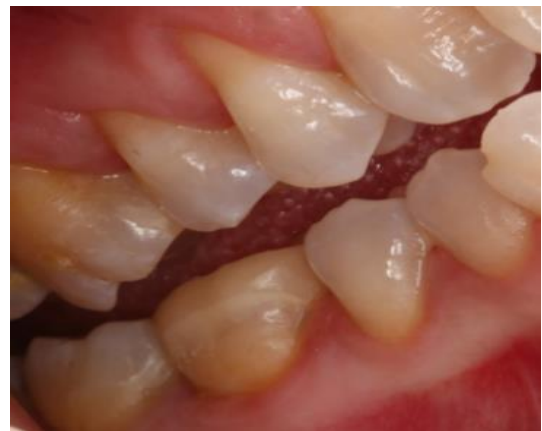Before any restorations, all procedures followed were in accordance with the ethical standards of the responsible committee on human experimentation (institutional and national) and with the Helsinki Declaration of 1964 and later versions. Informed consents were obtained from all patients for being included in this study.

All the restorations were made from feldspathic ceramic blocs (Sirona CEREC Blocs C-VITA Zahnfabrik, Bad Säckingen, Germany). All of the preparations were scanned and designed with CEREC System (CEREC Premium - Sirona Dental Systems GmbH, Bensheim, Germany) and then sent to the milling unit. After glazing, all of the overlay restorations were cemented with a dual cure adhesive resin cement (Panavia F 2.0, Kuraray Noritake Dental Inc., Japan).



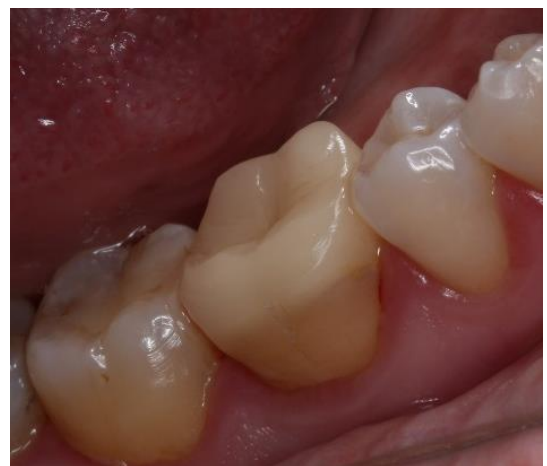**Figure 9.**

Panoramic radiography of the patient



**Figure 10.**

Photo of overlay on #36 at 1 year



**Figure 11.**

Photo of overlay on #36 at 2 years



## DISCUSSION

Large hard tissue losses are frequent in molar teeth depending on caries or aging of the restoration. Due to these reasons, the remaining coronal tooth structure and the functional requirements are important factors to be considered in deciding the treatment planning.<sup>5</sup> After deciding the treatment plan, the physical properties of the selected restorative materials should be considered, prior to the cavity preparation.<sup>6,7</sup> Teeth with large hard tissue losses can be restored with direct composite resins<sup>8</sup>, crowns<sup>9</sup> or inlay, onlay, and, overlays.<sup>10,11</sup> Direct composite resin restorations are increasingly popular but due to the side-effects of composite polymerization shrinkage especially in big cavities, it is not recommended to use for the restoration of large hard tissue losses.<sup>8</sup> On the other hand, traditional fabrication of a crown has multistage process that involves an impression also a laboratory part<sup>11</sup> and, requires more extensive tooth preparation.<sup>10</sup> Although a full crown is considered as the gold standard, with a six time greater rate of success in endodontically treated teeth, with this restoration type preserving the healthy dental tissue is impossible.<sup>12</sup> Inlays/onlays/overlays are very conservative restoration types which preserve maximum amount of sound tooth structure.<sup>13</sup> Onlays, but mostly overlay restorations allow to delay the execution of a full crown, preserving the healthy dental tissue. Besides, adhesive overlays preserve coronal structure, avoid contamination of the root canal treatment, reinforce residual dental tissues, guarantee optimal form, function and aesthetics.<sup>12</sup> Magne and Besler<sup>14</sup> were also reported that onlay and overlay restorations were the most effective choices in the treatment of the excessively damaged posterior teeth. Inlay/onlay/overlay restorations can be made of composite and ceramic which are both esthetic materials.<sup>15</sup> Composite inlays/onlays/overlays can be produced using laboratory techniques indirectly, but more than one session is needed for the final restoration. Ceramic materials performed better than composite resin materials for inlays in the short term.<sup>15</sup> Also ceramic inlays, onlays, and overlays showed high survival rates at 5 years and 10 years when compared to the composite material.<sup>10</sup> Besides the advantages; the higher cost, the greater skill level required to do the treatment, and the possible need for an additional appointment are the challenging features of the ceramic restorations. As the ceramic inlays/onlays/overlays can be produced indirectly in the dental laboratory which includes many preparation stages, these restorations can be also milled from prefabricated ceramic blocks in the dental laboratory or in the dental office using a chair-side CAD-CAM systems.<sup>16</sup>

Improvements in computer technology, equipments, and restorative materials have made it possible to manufacture an indirect aesthetic restoration in a single visit while the patient is waiting. The CAD/CAM systems offer many advantages in clinical practice. Customized shaping, definite milling of blocks, adaptation of the inner surface of the restoration which provides precision-fit, replication of the occlusal morphology, producing the restorations chairside and cementing in one appointment are the most important properties of this system. Also, by CAD-CAM system, the errors are minimized, the cross-contamination due to impression and laboratory processes is reduced which is finalized with patient satisfaction.<sup>17,18</sup> Material selection plays an important role when producing CAD-CAM restorations (CEREC). Overlay restorations can be fabricated from a number of restorative material. Feldspathic porcelain is indicated as one of the current choices.<sup>16</sup> In this case series, feldspathic ceramic material was selected due to good translucency, clinical acceptance, highly aesthetic appearance, chameleon effect, and antagonist-friendly abrasion properties.<sup>19</sup> In addition to these properties when feldspathic ceramic blocks compared to dental ceramic materials which are processed in the laboratory, it was found out that feldspathic ceramic blocks have better fracture strength and structural homogeneity. Also the preparation is suitable for the conservative and modern preparation design.<sup>20</sup> In an *in vitro* study which compares MOD composite resin restorations with ceramic inlay restorations, it was reported that teeth which restored with CAD-CAM ceramics showed comparable fracture resistance to the sound teeth.<sup>21</sup> In an other study, the success rate of CAD/CAM manufactured ceramic inlays (CEREC) was found out 98 % after 2 years.<sup>22</sup> As a result, in this case report, when all the overlay restorations were clinically evaluated, no secondary caries, fracture, discoloration, esthetic degradation, and loosening of the structural integrity were determined after 12 and 24 months follow-up. Besides, the stability of the restorations and tissue preservation were found satisfactory. Therefore, it can be reported that the success rate of these cases was 100% after 24-months follow-up.

## CONCLUSIONS

Combined with adhesive luting technique, CAD-CAM Systems create biocompatible, indirect tooth like esthetic restorations in a single treatment session. Based on current data, indirect ceramic restorations luted with adhesive resin cement can be considered as an ideal option for the restoration of tooth weakened due to large tooth loss. Also CAD-CAM Systems provide to the patient a convenient, well-fitting and durable indirect restoration to the patients. Furthermore, proper case and material selection are critical for ensuring clinical success with overlays.

## REFERENCES

1. Collares K, Correa MB, Laske M, Kramer E, Reiss B, Moraes RR, et al. A practice-based research network on the survival of ceramic inlay/onlay restorations. *Dent Mater* 2016; 32: 687-94.
2. Sannino G, Germano F, Arcuri L, Bigelli E, Arcuri C, Barlattani A. CEREC CAD/CAM Chairside System. *Oral Implantol* 2014; 7(3): 57-70.
3. Zimmermann M, Mehl A, Reich S. New CAD/CAM materials and blocks for chairside procedures. *Int J Comput Dent* 2013; 16(2): 173-78.
4. Marocho S, Melo R, Macedo L, Valandro L, Bottino M. Strength of a feldspar ceramic according to the thickness and polymerization mode of the resin cement coating. *Dent Mater J* 2011; 30(3): 323-29.
5. Faria AC, Rodrigues RC, de Almeida Antunes RP, de Mattos Mda G, Ribeiro RF. Endodontically treated teeth: Characteristics and considerations to restore them. *J Prosthodont Res* 2011; 55(2): 69-74.
6. Esquivel-Upshaw JF, Anusavice KJ. Ceramic design concepts based on stress distribution analysis. *Compend Contin Educ Dent* 2000; 21(8): 649-52.
7. Frankenberger R, Hehn J, Hajto J, Krämer N, Naumann M, Koch A, et al. Effect of proximal box elevation with resin composite on marginal quality of ceramic inlays in vitro. *Clin Oral Investig* 2013; 17(1): 177-83.
8. Batalha-Silva S, de Andrada MA, Maia HP, Magne P. Fatigue resistance and crack propensity of large MOD composite resin restorations: Direct versus CAD/CAM inlays. *Dent Mater* 2013; 29(3): 324-31.
9. Sequeira-Byron P, Fedorowicz Z, Carter B, Nasser M, Alrowaili EF. Single crowns versus conventional fillings for the restoration of root-filled teeth (Review). *Cochrane Database Syst Rev* 2015; 25(9): 1-31.
10. Morimoto S, Vieira GF, Agra CM, Sesma N, Gil C. Fracture strength of teeth restored with ceramic inlays and overlays. *Braz Dent J* 2009; 20(2): 143-48.
11. Oen KT, Veitz-Keenan A, Spivakovsky S, Wong YJ, Bakarman E, Yip J. CAD/CAM versus traditional indirect methods in the fabrication of inlays, onlays, and crowns (Review). *Cochrane Database Syst Rev* 2014; 4: 1-8.
12. Aquilino SA, Caplan DJ. Relationship between crown placement and the survival of endodontically treated teeth. *J Prosthet Dent* 2002; 87: 256-63.
13. Garlapati R, Venigalla BS, Kamishetty S, Thumu J. Ceramic onlay for endodontically treated mandibular molar. *JOFS* 2014; 6(1): 69-72.
14. Magne P, Besler UC. Porcelain versus composite inlays/onlays: effects of mechanical loads on stress distribution, adhesion, and crown flexure. *Int J Periodontics Restorative Dent* 2003; 23: 543-55.
15. Chabouis HF, Faugeron VS, Attal JP. Clinical efficacy of composite versus ceramic inlays and onlays: A systematic review. *Dent Mater* 2013; 29: 1209-18.
16. Hopp CD, Land MF. Consideration for ceramic inlays in posterior teeth: a review. *Clin Cosmet Investig Dent* 2013; 5: 21-32.
17. Chang C-Y, Kua J-S, Lin Y-S, Chang Y-H. Fracture resistance and failure modes of CEREC endo-crowns and conventional postand core-supported CEREC crowns. *JDS* 2009; 4(3): 110-17.
18. Vinothkumar TS, Kandaswamy D, Chanana P. CAD/CAM fabricated single unit all ceramic post core crown restoration. *JCD* 2011; 14(1): 86-9.
19. Sirona The Dental Company. [www.sironausa.com](http://www.sironausa.com). 2016.
20. Altıncı P, Kiremitçi A. Endodontik tedavili dişlerin restorasyonu. *Hacettepe Dis Hek Fak Derg* 2007; 31(3): 102-13.
21. Bremer BD, Geurtsen W. Molar fracture resistance after adhesive restoration with ceramic inlays or resin-based composites. *Am J Dent* 2001; 14: 216-20.
22. Sjögren G, Molin M, van Dijken J, Bergman M. Ceramic inlays (Cerec) cemented with either a dual-cured or a chemically cured composite resin luting agent. A 2-year clinical study. *Acta Odontol Scand* 1995; 53(5): 325-30.

Corresponding Author:

Dr.Dt. Mağrur KAZAK  
 Bezmialem Vakıf University  
 Dentistry Faculty  
 Department of Restorative Dentistry  
 Adnan Menderes Bulvarı, Vatan Caddesi  
 34390, Fatih, İstanbul  
 Phone: +90 532 332 51 27  
 E-mail: magrur@hotmail.com