



## EVALUATION IN TERMS OF ANGLE AND LENGTH OF THE CORONOID PROCESS AND CONDYLE IN ADOLESCENTS AND ADULTS

### YETİŞKİN VE ADOLESANLARDA KORONOİD ÇIKINTININ VE KONDİLİN AÇI VE UZUNLUK YÖNÜNDE DEĞERLENDİRİLMESİ

Görkem Tekin<sup>1\*</sup>, Nesrin Saruhan<sup>1</sup>

<sup>1</sup>Eskisehir Osmangazi University, Faculty of Dentistry, Department of Oral and Maxillofacial Surgery, Eskişehir, Turkey

ORCID iD: Nesrin Saruhan: 0000-0003-1160-4179; Görkem Tekin: 0000-0002-6572-2675

\*Sorumlu Yazar / Corresponding Author: Görkem Tekin, e-posta / e-mail: dt.gorkemtekin@gmail.com

Geliş Tarihi / Received: 24.12.2019

Kabul Tarihi / Accepted: 24.11.2020

Yayın Tarihi / Published: 29.05.2021

#### Abstract

**Objective:** The aim of this study is to evaluate the condyle and coronoid process in terms of angle and length in adults and adolescents.

**Methods:** A total of 184 patients who had Cone Beam Computed Tomography (CBCT) images were included in this study. The patients were divided into 2 groups, including 92 adolescents (female, n=48; male, n=44) and 92 adults (female, n=46; male, n=46). The condyle angle (CoA), coronoid angle (CrA), condyle length (CoD) and coronoid length (CrD) were evaluated in adults and the adolescents. Shapiro-Wilk test was performed to evaluate the normality of the variances. After determination at the normal distribution of the data, statistical analysis was performed by using independent-samples t-test. The data without normal distribution were statistically analyzed by using Mann-Whitney U test.

**Results:** The mean CrA was  $120.23 \pm 5.27^\circ$  in the adolescents and  $115.57 \pm 6.99^\circ$  in the adults. The mean CoA was  $111.33 \pm 5.18^\circ$  in the adolescents and  $113.14 \pm 6.19^\circ$  in the adults. The mean CoD was  $16.43 \pm 2.57$  mm in the adolescents and  $15.16 \pm 2.81$  mm in the adults. The mean CrD was  $11.71 \pm 2.24$  mm in the adolescents and  $13.90 \pm 3.53$  mm in the adults. When the CrA, CoA, CrD and CoD values were compared with the adults and the adolescents, statistically significant differences were found in their CrA, CoD and CrD values. CrD was higher in the adults than the adolescents. CrA and CoD were higher in the adolescents than in the adults. There was no statistically significant difference in CrA, CoA, CrD and CoD values when these groups were compared in terms of sex.

**Conclusion:** CrD was higher in the adults than the adolescents. CrA and CoD were higher in the adolescents than in the adults. There was no statistically significant difference in CrA, CoA, CrD and CoD values when these groups were compared in terms of sex. In order to evaluate lengths and angles in more detail between adults and adolescents, studies including more detail datasets are needed.

**Keywords:** Cone Beam Computed Tomography, Coronoid Process, Condyle

#### Öz

**Amaç:** Bu çalışmanın amacı yetişkin ve adolesanlarda kondil ve koronoid çıkıntının açı ve uzunluk yönünden değerlendirilmesidir.

**Yöntem:** Araştırmamıza Konik Işınli Bilgisayarlı Tomografi (KIBT) görüntüleri olan 184 hasta dahil edildi. Hastalar 2 gruba ayrıldı: 92'si adolesan (kadın, n=48; erkek, n=44) ve 92'si yetişkin (kadın, n=46; erkek, n=46). Hastaların kondil açısı (CoA), koronoid açısı (CrA), kondil uzunluğu (CoD) ve koronoid uzunluğu (CrD) yetişkin ve adolesanlar arasında değerlendirildi. Verilerin normal dağılıp dağılmadığını değerlendirmek için Shapiro-Wilk testi yapıldı. Gruplar arasındaki farklılıkları değerlendirmek için normal dağılım gösteren verilerde bağımsız örnekleme t-testi, normal dağılım göstermeyen verilerde ise Mann-Whitney U testi yapıldı.

**Bulgular:** Ortalama CrA değeri adolesanlarda  $120,23 \pm 5,27^\circ$  ve yetişkinlerde  $115,57 \pm 6,99^\circ$  olarak bulundu. Ortalama CoA değeri adolesanlarda  $111,33 \pm 5,18^\circ$  ve yetişkinlerde  $113,14 \pm 6,19^\circ$  olarak bulundu. Ortalama CoD değeri adolesanlarda  $16,43 \pm 2,57$  mm ve yetişkinlerde  $15,16 \pm 2,81$  mm olarak bulundu. Ortalama CrD değeri adolesanlarda  $11,71 \pm 2,24$  mm ve yetişkinlerde  $13,90 \pm 3,53$  mm olarak bulundu. CrA, CoA, CrD ve CoD yetişkin ve adolesanlar arasında karşılaştırıldığında, CrA, CoD ve CrD değerlerinde istatistiksel olarak anlamlı bir fark bulundu. CrD yetişkinlerde adolesanlara göre daha yüksek bulundu. CrA ve CoD ise adolesanlarda yetişkinlere göre daha yüksek bulundu. Yetişkin ve adolesanlarda cinsiyet açısından karşılaştırılma yapıldığında CrA, CoA, CrD ve CoD değerlerinde istatistiksel olarak anlamlı fark bulunmadı.

**Sonuç:** CrD yetişkinlerde adolesanlara göre daha yüksek bulundu. CrA ve CoD ise adolesanlarda yetişkinlere göre daha yüksek bulundu. Yetişkin ve adolesanlarda cinsiyet açısından karşılaştırılma yapıldığında CrA, CoA, CrD ve CoD değerlerinde istatistiksel olarak anlamlı fark bulunmadı. Ayrıntılı değerlendirme için veri sayısının fazla olduğu çalışmalara ihtiyaç duyulmaktadır.

**Anahtar Kelimeler:** Konik Işınli Bilgisayarlı Tomografi, Koronoid, Kondil

## Introduction

The mandible is an important part of the viscerocranium's articulation with the skull base.<sup>1</sup> The mandible changes its morphology, depending on its dynamic environment, and forms trabeculae to achieve the maximum strength with minimum material according to biodynamic principles.<sup>2</sup> Morphological changes in the mandible are due to many factors such as age, genetics, osteoporosis, tooth loss, sex and ethnicity.<sup>3</sup> Studies have reported that mandibular ramus height's, symphysis height's and mandibular angle's changes related to age.<sup>4-6</sup> It is thought that these changes in the mandible may also affect the condyle and the coronoid process. Mandibular condyles play an important role in the growth and development of the maxillofacial area and may be directly associated with the patients' maxillomandibular characteristics.<sup>7</sup> The coronoid process of the mandible is gaining vital significance as a graft material in reconstructive maxillofacial surgeries and as a non-metric skull variant in assessment of age, sex, race and species.<sup>8</sup> The mandible is an important tool for radiological identification because at easy imaging.<sup>7</sup> Imaging of the mandible with conventional techniques is difficult due to the superposition of the temporal bone. Measurements that can be made are limited due to distortions in the image. CBCT provides better data acquisition by providing 3D imaging.<sup>9</sup> Some studies have been conducted to evaluate the lengths of the condyle and the coronoid process.<sup>10, 11</sup> However, age-related comparisons of angles and lengths were not done in these studies.

In this study, it was aimed to evaluate the angles and lengths of the condyle and the coronoid process compared with adults and adolescents who were admitted to a Department of Oral and Maxillofacial Surgery.

## Methods

Before the study, ethical approval was obtained (Ethical Committee Decision No: 166/2018). In this study, the retrospective data of patients who were admitted to the Department of Oral and Maxillofacial Surgery at the Faculty of Dentistry at Eskisehir Osmangazi University between 2014 and 2018 were examined.

The CBCT images of 192 patients who had no mandibular pathology, trauma and mandibular operation were included in the study. The patients were divided into two groups; 92 adults (female n=46; male n=46) and 92 adolescents (female n=48; male n=44).

### CBCT Measurements

All tomographic images were obtained in a standing position using a CBCT machine (Promax 3D Mid; Planmeca, Helsinki, Finland). The imaging parameters were as follows: tube voltage 94 kVp, X-ray tube current 14 mA, rotation 360°, scan time 27 s, field of view (FOV) area 20.2×20.2×17.5 mm and voxel size 0.600 mm. All CBCT images obtained from the patients were examined by the same researcher. The sagittal sections of the CBCT images obtained with Promax 3D Mid; Planmeca (Helsinki, Finland) were used.

For the evaluation on CBCT, we determined reference points (Fig.1.A). These points are summarized and depicted in Table 1 and Fig. 1.

### Length measurement

CrD: Vertical distance between Reference Line(RL) and Cr (lateral view) (Fig. 1.B)

CoD: Vertical distance between RL and Co (lateral view) (Fig. 1.B)

Angle measurement

CoA: The angle between RL and a line connecting MF-Co (lateral view) (Fig. 1.C)

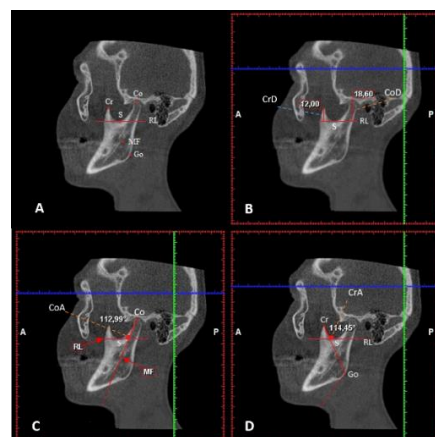
CrA: The angle between RL and a line connecting Cr-Go (lateral view) (Fig. 1.D)

### Statistical Analysis

Statistical analysis was performed by using the IBM SPSS Statistics 22 package program (IBM Corp, Armonk, NY). Descriptive statistics, including the mean, standard deviation, median, and minimum and maximum values, were calculated for each of the two groups. Shapiro-Wilk test was conducted to assess the normality of variances. After determination at the normal distribution of the data, statistical analysis was performed by using independent-samples t-test. The data that did not have a normal distribution were statistically analyzed by using Mann-Whitney U test. The test results were considered statistically significant if the *p*-value was < 0.05.

## Results

The measurements were made on the CBCT images of 184 patients including 92 adults and 92 adolescents whose ages varied in the range of 10-54 (mean: 24.66±12.66). While the mean age of the adolescent group was 13.54±2.18, the adult group was 35.78±8.24. The mean CrA, CoA, CoD and CrD values of the adolescents were found respectively as 120.23±5.27°, 111.33±5.18°, 16.43±2.57 mm and 11.71±2.24 mm. The mean CrA, CoA, CoD and CrD values of the adults were found respectively as 115.57±6.99°, 113.14±6.19°, 15.16±2.81 mm and 13.90±3.53 mm (Table 2). Shapiro-Wilk test was done. CrA and CoD showed normal distribution. CoA and CrD showed not normal distribution. In the results of the independent-samples t-test to assess the differences between the adults and the adolescents, the adolescents showed a higher CrA and CoD values in comparison to that of the adults (Table 3). There were statistically significant differences between these values (*p*<0.05). The Mann-Whitney U test was done. The CrD value was found greater in the adults than in the adolescents (Table 4). No statistically significant difference was found in the intragroup comparisons in terms of sex (Table 5).



**Figure 1:** A: Reference Points, B: Condyle-Coronoid Lengths and Angle Measurements, C: Coronoid Angle Measurement, D: Condyle Angle Measurement

**Table 1.** Reference line and points in this study

Landmark		Definition
Cr	Coronoid Process	The most superior point of the mandibular coronoid process
Co	Condyle	The most superior point of the mandibular condyle
Go	Gonion	The most prominent, inferior, and posterior point at the angle of the mandible
MF	Mandibular Foramen	The most inferior point of the mandibular foramen
S	Sigmoid Notch	The most inferior point of the sigmoid notch
RL	Reference Line	Line passing through point S and drawn parallel to the axial plane

**Table 2.A.** Descriptive statistics

	n	Minimum	Maximum	Mean	SD
CrA(°)	184	99.64	136.04	117.90	6.60
CoA(°)	184	100.35	137.01	112.24	5.77
CoD(mm)	184	8.80	22.80	15.79	2.76
CrD(mm)	184	5.40	24.00	12.80	3.15
Age	184	10	54	24.66	12.66

Abbreviations: CrA:Coronoid angle; CoA:Condyle angle; CoD:Condyle distance; CrD:Coronoid process distance; SD.:Standard deviation

**Table 2.B.** Descriptive statistics between groups

Group	Measure and Age	n	Minimum	Maximum	Mean	SD
Adolescent	CrA(°)	92	106.53	132.59	120.23	5.27
	CoA(°)	92	102.56	125.54	111.33	5.18
	CoD(mm)	92	11.40	22.80	16.43	2.57
	CrD(mm)	92	5.40	17.40	11.71	2.24
	Age	92	10	19	13.54	2.18
Adult	CrA(°)	92	99.64	136.04	115.57	6.99
	CoA(°)	92	100.35	137.01	113.14	6.19
	CoD(mm)	92	8.80	21.00	15.16	2.81
	CrD(mm)	92	6.80	24.00	13.90	3.53
	Age	92	24	54	35.78	8.24

Abbreviations: CrA:Coronoid angle; CoA:Condyle angle; CoD:Condyle distance; CrD:Coronoid process distance; SD.:Standard deviation

**Table 3.** CrA and CoD according to groups were analysed by Independent Samples T test

Measures	Adolescent (n=92)		Adult (n=92)		P
	Mean	SD	Mean	SD	
CrA(°)	120.23	5.27	115.58	6.99	.00*
CoD(mm)	16.43	2.57	15.16	2.81	.00*

**Table 4.** Comparison of CoA and CrD according to groups were analysed by Mann-Whitney U test

Measures	Adolescent (n=92)			Adult (n=92)			P
	Median	Min.	Max.	Median	Min.	Max.	
CoA(°)	84.83	102.56	125.54	100.17	100.35	137.01	>.05
CrD(mm)	75.74	5.40	17.40	109.26	6.80	24.00	.00*

\*P<0.05: statistically significant; Min.:Minimum; Max.:Maximum

**Table 5.A.** Comparison of CrA and CoD in terms of gender in their own groups were analysed by Independent Samples T test

Groups	Measures	Gender	n	Mean	SD	P value
Adolescent	CrA(°)	Female	48	119.66	5.64	.285
		Male	44	120.84	4.82	
	CoD(mm)	Female	48	16.17	2.35	.282
		Male	44	16.71	2.79	
Adult	CrA(°)	Female	46	116.31	7.93	.314
		Male	46	114.83	5.91	
	CoD(mm)	Female	46	15.35	2.74	.527
		Male	46	14.97	2.90	

\*P < 0.05: statistically significant

**Table 5.B.** Comparison of CoA and CrD in terms of gender in their own groups were analysed by Mann-Whitney U test

Groups	Measures		P value
Adolescent	CoA(°)	Female	.097
		Male	
	CrD(mm)	Female	.667
		Male	
Adult	CoA(°)	Female	.944
		Male	
	CrD(mm)	Female	.113
		Male	

\*P< 0.05: statistically significant

## Discussion

Carlos et al.<sup>12</sup> compared panoramic radiography and CBCT images in terms of length measurements. They reported that panoramic radiography showed 29% more than normal ratios, while CBCT showed 4% more than normal ratios. They concluded that the measurements were made more accurately with CBCT. In our study, CBCT was used for the accuracy of the measurements.

Tavassol et al.<sup>10</sup> formed two groups in their study to evaluate the length of the condyle and the coronoid process. They divided these groups into two further groups: adult and adolescent. Tavassol et al. found the mean age in group 1 (adults) 42.9 years (range of 26-59, median 43) and in group 2 (adolescents) 13.9 years (median 15 years, age range 7-19 years). The World Health Organization (WHO) defines 'Adolescents' as individuals in the 10 to 19 age group and 'adults' as individuals aged 24 and over.<sup>13</sup> In our study, we also formed 2 groups as adults and adolescents. The ages of the adolescents were in the range of 10-19 (mean: 13.54±2.18). The ages of the adults were in the range of 24-54 (mean: 35.78±8.24). In our study, the mean age of the adolescents was similar to that reported by Tavassol et al., the mean age of the adults was lower in our study.

Tavassol et al.<sup>10</sup> compared the coronoid process and the condyle based on the deepest point of the sigmoid notch in CBCT images. In their measurements, they found that the mean coronoid process lengths as 13.02 mm in adults and 12.43 mm in adolescents. They found that the coronoid/condyle ratio as 0.78 between adults and adolescents. Bilgili et al.,<sup>14</sup> measured the vertical lengths of the condyle and coronoid process from the top point based on a line in parallel to the ground from the deepest point of the sigmoid notch on the sagittal plane. They compared the coronoid length and condyle length on the sides with and without coronoid hyperplasia. On the side with coronoid hyperplasia, they found the mean coronoid process length as 15.72 mm and the mean condyle length as 13.23 mm. On the normal side, these values were 13.75 mm and 15.32 mm respectively. Başaran et al.<sup>11</sup> also measured the lengths of the condyle and coronoid process on the sagittal plane from the top point based on a line parallel to the ground from the deepest point of the sigmoid notch. They found the mean right condyle height of the patients as 16.70±0.22 mm, the mean left condyle height 16.99±0.22 mm, the mean right coronoid height 11.41±0.23 mm and the mean left coronoid height as 11.91±0.24 mm. The condyle and coronoid process lengths in males were found to be longer than females. In our study, a reference line is parallel to the axial plane and passing through the deepest point of the sigmoid notch was determined. Vertical lengths from the top points

of the coronoid process and the condyle to the reference line were determined. This measurement method was also used by Başaran et al. In this study, the mean coronoid process length was  $11.71 \pm 2.24$  mm in the adolescents and  $13.90 \pm 3.53$  mm in the adults. The mean condyle length was  $16.43 \pm 2.76$  mm in the adolescents and  $15.16 \pm 2.81$  mm in the adults. The coronoid process length was significantly higher in the adults than in the adolescents ( $p < 0.05$ ). The condyle length was significantly higher in the adolescents than in the adults ( $p < 0.05$ ). In the comparison of the groups based on sex, there was no statistically significant difference. In this study the coronoid process and condyle length values found were similar in the adult compared with Tavassol to those reported in normal patients by Tavassol et al., Bilgili et al. and Başaran et al. This supported the accuracy of the measurements. The difference of our study from the other studies was that these measurements made in other studies have not been compared between adolescents and adults. The higher value of the coronoid process length in the adults may be considered to be related to late-stage growth. Saccuci et al.<sup>15</sup> compared condyle volumes between mandibular divergence (low angle, normal angle and high angle) and skeletal class (class 1, class 2 and class 3). They found the condyle volume to be lower in class 2 skeletal and high-angle patients. It is thought that high angle or skeletal class 2 patients may be in adult patients and consequently higher CoD values are found in adolescents compared to adults. A few imaging studies have shown that disc deformity is common in temporomandibular joint disorders.<sup>16, 17</sup> As a result of disc deformity, they reported that the articular eminence was deformed and flattened, and the condyle height decreased. It is thought that the length of the condyle is reduced due to temporomandibular joint disease in adult patients.

Park et al.<sup>18</sup> compared lengths and angles in mandibles with class 1, class 2 and class 3 skeletal malocclusions. To calculate the condylar axis angle, they calculated the angle between the Frankfurt horizontal plane and the plane passing from the top point of the condyle and the bottom point of the mandibular foramen. The condylar axis angles of the class 1, class 2 and class 3 skeletal malocclusion patients were found respectively as  $71.90 \pm 5.6^\circ$ ,  $72.44 \pm 3.1^\circ$  and  $73.21 \pm 6.6^\circ$ . There was no statistically significant difference among these. In our study, the plane passing through the top point of the condyle and the bottom point of the mandibular foramen was taken as a reference. The angle between this reference plane and the plane is parallel to the axial plane was calculated. This indicates the difference of our study. The mean value of CoA was found for the adults and adolescents as respectively  $113.14 \pm 6.19^\circ$  and  $111.33 \pm 5.18^\circ$ . CoA was defined as the angle between the axial plane and the condylar plane that may represent the direction of the displacement of the condyle. Our expectation was that this angle would decrease in relation to condylar growth. CoA showed very little difference between the adults and the adolescents. This difference was not statistically significant. There was also no statistically significant difference when the groups were compared within themselves based on sex.

Assari et al.<sup>2</sup> calculated from the top point of the coronoid process to gonion point to assess the length of the coronoid process. They made linear measurement between these points. Also, these measurements compared between the sexes. They found the length of the coronoid process is longer in male than female. The line of linear measurement used by Assari et al. was also utilized in our study. The

angle between this line and the reference plane is parallel to the axial plane was measured as CrA. The mean CrA value in the adults and adolescents were found respectively as  $115.58 \pm 6.99^\circ$  and  $120.23 \pm 5.27^\circ$ . CrA was found to be smaller in the adults than in the adolescents. We believe that the decrease in CrA was associated with late-stage growth in the adults.

### Conclusion

CrA and CoD values were higher in adolescents than adults. CrD value was higher in adults than adolescents. There was no statistically significant difference in CrA, CoA, CrD and CoD values when these groups were compared according to sex. In order to evaluate lengths and angles in more detail between adults and adolescents, studies including more detail datasets are needed. The limitations of this study; Bruxism examination was not performed in the patients without joint temporomandibular disorder, and accordingly, the changes in the condyle could not be evaluated. Angle and length measurements were not made only in skeletal class 1 patients.

### Conflict of Interest

The authors have no conflicts of interest to declare

### Compliance with Ethical Statement

The ethical approval was obtained from Eskisehir Osmangazi University (Ethical Committee Decision No: 166/2018).

### Financial Support

The authors declared that no financial support was received for this paper.

### Author Contributions

NS: Design; NS: Conception; GT: Data collection; NS: Analysis; GT: Literature search; GT: Fundings; GT, NS: Manuscript writing

### References

1. Bakirci S, Ari I, Kafa IM. Morphometric characteristics and typology of the coronoid process of the mandible. *Acta Med Mediter.* 2013;29:683-6.
2. Assari A. Characteristics of Mandibular Parameters in Different Age Groups. A CBCT Assessment. *EC Dental Science.* 2017;14:95-103.
3. Dutra V, Yang J, Devlin H, Susin C. Mandibular bone remodelling in adults: evaluation of panoramic radiographs. *Dentomaxillofacial Radiology.* 2004;33(5):323-8.
4. Zangouei-Booshehri M, Aghili H-A, Abasi M, Ezoddini-Ardakani F. Agreement between panoramic and lateral cephalometric radiographs for measuring the gonial angle. *Iranian Journal of Radiology.* 2012;9(4):178.
5. Ogawa T, Osato S, Shishido Y, Misaki K. Relationships between the gonial angle and mandibular ramus morphology in dentate subjects: a panoramic radiophotometric study. *Journal of Oral Implantology.* 2012;38(3):203-10.
6. Leversha J, McKeough G, Myrteza A, Skjellrup-Wakefiled H, Welsh J, Sholapurkar A. Age and gender correlation of gonial angle, ramus height and bigonial width in dentate subjects in a dental school in Far North Queensland. *Journal of clinical and experimental dentistry.* 2016;8(1):e49.
7. Genú PR, Vasconcelos RJdH, Oliveira Bpd, Vasconcelos BCGd, Delgado NcdC. Analysis of anatomical landmarks of the mandibular interforaminal region using CBCT in a Brazilian population. *Brazilian Journal of Oral Sciences.* 2014;13(4):303-7.

8. Subbaramaiah M, Bajpe R, Jagannatha S, Jayanthi K. A study of various forms of mandibular coronoid process in determination of sex. *Ind J Clin Anat Physiol*. 2015;2:199-203.
9. Petersson A. What you can and cannot see in TMJ imaging—an overview related to the RDC/TMD diagnostic system. *Journal of oral rehabilitation*. 2010;37(10):771-8.
10. Tavassol F, Spalthoff S, Essig H, Bredt M, Gellrich N-C, Kokemüller H. Elongated coronoid process: CT-based quantitative analysis of the coronoid process and review of literature. *International journal of oral and maxillofacial surgery*. 2012;41(3):331-8.
11. Başaran M, Görmez Ö, Bozdemir E, Yıldırım D. Konik ışınli bilgisayarlı tomografi görüntülerinde mandibular koronoid proses boyutlarının değerlendirilmesi. *Selcuk Dental Journal*. 2019;6(4):425-8.
12. Flores-Mir C, Rosenblatt MR, Major PW, Carey JP, Heo G. Measurement accuracy and reliability of tooth length on conventional and CBCT reconstructed panoramic radiographs. *Dental press journal of orthodontics*. 2014;19(5):45-53.
13. Goodburn EA, Ross DA, Organization WH. A Picture of health?: a review and annotated bibliography of the health of young people in developing countries. *World Health Organization*; 1995.
14. Bilgili E. Unilateral Mandibular Koronoid Hiperplazisi Olgularının Konik Işınli Bilgisayarlı Tomografi ile İncelenmesi. *Van Tıp Dergisi*. 2017;24(4):250-3.
15. Saccucci M, Polimeni A, Festa F, Tecco S. Do skeletal cephalometric characteristics correlate with condylar volume, surface and shape? A 3D analysis. *Head & face medicine*. 2012;8(1):15.
16. Kurita H, Ohtsuka A, Kobayashi H, Kurashina K. Resorption of the postero-superior corner of the lateral part of the mandibular condyle correlates with progressive TMJ internal derangement. *International journal of oral and maxillofacial surgery*. 2003;32(4):363-7.
17. Cai X-Y, Jin J-M, Yang C. Changes in disc position, disc length, and condylar height in the temporomandibular joint with anterior disc displacement: a longitudinal retrospective magnetic resonance imaging study. *Journal of Oral and Maxillofacial Surgery*. 2011;69(11):e340-e6.
18. Park W, Kim B-C, Yu H-S, Yi C-K, Lee S-H. Architectural characteristics of the normal and deformity mandible revealed by three-dimensional functional unit analysis. *Clinical oral investigations*. 2010;14(6):691-8.