

# A Pediatric Case of Concomitant Leishmania and Brucella Infection

## Pediatric Bir Olguda Leishmania ve Brucella Birlikte Enfeksiyonu

Perihan Yasemen Canöz, Gökhan Tümgör\*, İbrahim Hakan Bucak\*\*, Göksel Leblebisatan, Fatma Levent İstifli, Mehmet Turgut\*\*

Adana Numune Training and Research Hospital, Clinic of Children's Health and Diseases, Adana, Turkey

\*Çukurova University Faculty of Medicine, Department of Pediatrics and Medicine, Adana, Turkey

\*\*Adıyaman University Training and Research Hospital, Clinic of Child Health and Diseases, Adıyaman, Turkey



### Abstract

Visceral leishmaniasis (Kala-azar) is a disease caused by protozoan parasites of the Leishmania Genus, and Brucellosis is a zoonotic disease infecting human host by infective animals. A sixteen year-old girl presented to our clinic with complaints of fatigue, myalgia, pallor, stomach ache, leg swelling, and diffuse body rash. Physical examination revealed findings of elevated body temperature, splenomegaly, upper and lower extremity edema, and diffuse erythema. Patients' brucella agglutination test was positive at titers 1: 640. Since the treatment of Brucellosis was unsuccessful, other disease processes were investigated and extracellular and intracellular amastigots were detected in the bone marrow aspirate preparations. Kala-azar dipstick (rk-39) was also positive. We present a 16 year-old girl who was diagnosed with Kala-azar and Brucellosis together infection and successfully treated. (The Journal of Current Pediatrics 2014;2:103-6)

### Özet

Viseral leishmaniasis; Leishmania türüne ait protozoal parazitlerin neden olduğu bir hastalıktır. Brusellozis; insanlara enfekte hayvanlardan bulaşan zoonotik bir hastalıktır. On altı yaşında kız hasta kliniğimize güçsüzlük, miyalji, solukluk, karın ağrısı, ayaklarda şişlik, tüm vücutta döküntü şikayetleri ile başvurdu. Yapılan klinik muayenede ateş yüksekliği, splenomegali, üst ve alt ekstremitelerde ödem ve tüm vücutta eritem tespit edildi. Hastaya ait Brusella aglütinasyon testi 1/640 titre ile pozitif idi. Hastaya başlanan Brusella tedavisinin başarısız olması üzerine yapılan kemik iliği incelemesinde hücre içi ve hücre dışı amastigotlar tespit edildi. Kala-azar dipstick testi (rk-39) pozitif idi. Kala-azar ve Brusellozis tanısı ile başarılı şekilde tedavi edilen 16 yaşında kız hasta tarafımızdan sunuldu. (Güncel Pediatri 2014;2:103-6)

### Key words

Leishmaniasis, brucellosis, bone marrow aspiration

### Anahtar kelimeler

Leishmaniasis, brusellozis, kemik iliği aspirasyonu

Received/Geliş Tarihi : 17.03.2013

Accepted/Kabul Tarihi : 30.09.2013

DOI:10.4274/jcp.07379

Address for Correspondence/Yazışma Adresi:  
İbrahim Hakan Bucak MD, Adıyaman  
University Training and Research Hospital,  
Clinic of Child Health and Diseases,  
Adıyaman, Turkey  
Phone: +90 416 216 10 15  
E-mail: ihbucak@hotmail.com

© The Journal of Current Pediatrics, published by Galenos Publishing.  
© Güncel Pediatri Dergisi, Galenos Yayınevi tarafından basılmıştır.

### Introduction

Even though Leishmaniasis has been seen for centuries, it was first named by Alexander Russell in 1757 in a Turkish patient (1). Leishmania genus infects humans in 4 types: visceral leishmaniasis (which is also called Kala-azar), cutaneous leishmaniasis, diffuse cutaneous and mucocutaneous leishmaniasis (2). Frequently visceral leishmaniasis is caused by *L. donovani*, *L. infantum* and *L. chagasi*, which are mostly seen in children with a high mortality. This is an uncommon disease for our country which is mostly reported as case reports around the world. It usually is found in spleen, liver and lymphoid tissue and the

last thought one in differential diagnosis (3,4). Main hosts of Kala-azar are dogs and rodents. Infection is transmitted by infected female phlebotomos fly (5). Disease is a zoonotic and only under certain circumstances people are infected. When it is not properly treated, it leads to chronic progressive disease or to death. 80% of patients are under 5 years old. It is hardly diagnosed in children because it has a long incubation period and does not have specific findings at presentation, so it is mostly misdiagnosed (6). This case is reported because it is a concomitant infection of Kala-azar with brucellosis.

### Case Report

A 16 year-old girl presented to our hospital's pediatric clinic with complaints of fever, fatigue, pallor, diffuse abdominal pain, myalgia, and leg swelling. Her parents who have relocated to Adana from Southeast Turkey a few months ago, had complaints of paleness, fatigue, stomach ache and diffuse myalgia. Fever has started 15 days ago, and despite the usage of antibiotics and antipyretics, the fever has continued. A few days ago a generalized rash more prominent in extremities has emerged and swelling started in her legs. Her vital signs were as follows; axillary temperature 39.5 °C, pulse 96 per minute, blood pressure 100/60 mmHg, respiratory rate 28 per minute. Her weight and height percentiles were within normal limits for her age. She was alert, but pale and fatigued. The erythematous rash was 1-2 cm diameters wide on her legs, arms and around the umbilicus. She had edema on her back of her foot and anterior cruris. In her abdominal examination there was diffuse tenderness with palpation in the abdomen. She was found to have splenomegaly (2 cm below the costal margin) but no hepatomegaly. Respiratory and cardiac examination was within normal limits. Complete blood count revealed pancytopenia (Table 1).

Serological evaluation was negative for antinuclear antibody, anti DNA, EBV VCA IgM, Mycoplasma IgG and IgM, VDRL, CMV, HIV. Serologic evaluation for hepatitis A, B, C, D and E did not show any evidence for current infection. Serum Immunoglobulin A (IgA), IgG, IgM levels were normal. IgE level was 2082 IU/ml (N: 1.53-114 IU/ml) in her serum. Purified Protein Derivative (PPD) test was negative. Brucella agglutination test was positive at titers 1: 640. Blood, urine, throat and stool cultures were negative.

Doxycycline 4 mg/kg/day, rifampin 20 mg/kg/day and gentamicin 3 mg/kg/day were started for brucellosis. Because her body temperature was 39 °C at the 5th day of treatment, bone marrow aspiration was performed for visceral leishmaniasis (Kala-azar), which is a sporadic disease in our region. Extracellular and intracellular amastigots were seen in preparation of bone marrow aspiration (Figure 1). Kala-azar dipstick (rk-39) was also found to be positive. Specific treatment of intramuscular sodium styboglucanate at a dose 20 mg /kg/day for 20 days was started. The fever resolved after 2 days of concomitant treatment of sodium styboglucanate, doxycycline, rifampin and gentamicin (Figure 2). No treatment- related side effects were observed. Brucella 2-ME (mercapto ethanol) test and culture of bone marrow aspiration cannot be applied in our hospital.

### Discussion

According to reports of World Health Organization (WHO), 500 new cases of Kala-azar are reported worldwide annually (7). Turkey shows a regional distribution for Kala-azar and West, South, Southeast regions are mostly affected regions in Turkey (8,9). The incidence of Kala-azar in Turkey is still unknown (10). Disease is caused by *Leishmania donovani* species. These species are; *Leishmania donovani donovani*,

**Table 1.** Whole blood count and biochemical values of the case

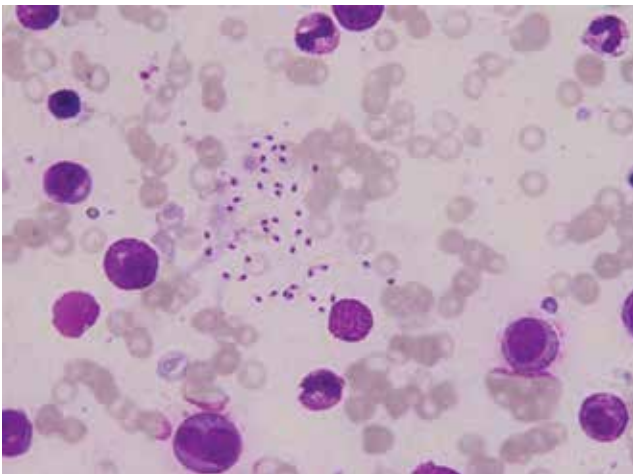
	1st day	14th day	35th day
Leukocyte (/mm <sup>3</sup> )	2390	3350	6730
Hemoglobine (g/dL)	9.7	9.3	10.8
Platelet (1000 /mm <sup>3</sup> )	106	433	439
AST (IU/L)	437	55	26
ALT (IU/L)	109	30	12
GGT (IU/L)	271	95	75
Albumine (g/dL)	2.9	3.7	3.8
Total bilirubin (mg/dL)	3.2	1.5	0.6
Conjugated bilirubin (mg/dL)	2.9	1.1	0.4
LDH (IU/L)	1157	438	254
Creatine Kinase (IU/L)	319	128	22
Alkalen phosphatase (IU/L)	285	189	128
C-reactive protein (mg/dL)	90	8.3	0.64
Sedimentation (mm/hours)	5	3	3

*Leishmania donovani infantum*, *Leishmania donovani chagasi* are the most frequently seen species in Turkey (11,12).

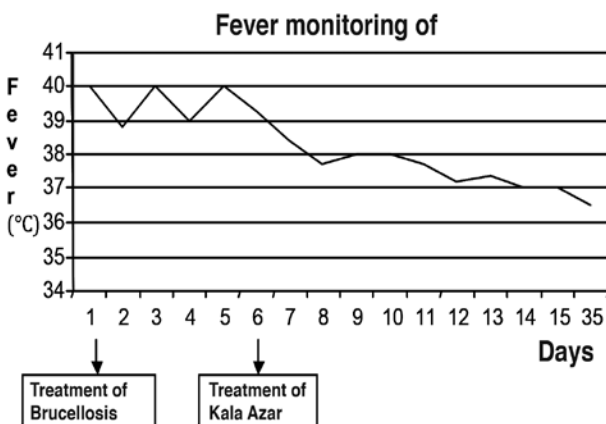
Brucellosis is a systemic infectious disease and according to (Centers for Disease Control and Prevention) CDC, 100 new *Brucella* cases are seen in the USA each year, however it is much higher in our country (13).

*Brucella* is an endemic disease in Turkey, and seropositivity is reported as 2-6% in several surveys performed in different years. It is a common disease, which is seen in all ages and genders but most frequently in 15-35 years of age (14,15).

This case was sent to our clinic for consultation with suspected malignancy. During the investigation of pancytopenia, *Brucella* agglutination test was



**Figure 1.** Bone marrow smear of the patient showing *Leishmania* amastigotes



**Figure 2.** Fever trend and onset of treatments

positive at a titer of 1: 640. Antibiotics to treat *Brucella* were started. Persistence of clinical findings after appropriate duration of antibiotics, bone marrow was aspirated again and was searched for a clue of malignancy or *Leishmania* parasite. After observation of the smear of bone marrow aspirate intensely, patient was diagnosed with Kala-azar, and 20 mg/kg/day, intramuscular sodyum sitobuglukonat was added to the regimen as a suggestion of department of pediatric infectious disease.

In this case, a diagnostic method of observation of amastigotes in bone marrow aspiration that is highly specific for diagnosis of the disease was used, and extensive examination of many smears was required to demonstrate the parasite. Kala-azar dipstick (rk-39) was also positive in this case. Often the parasite may be observed only in tissues such as spleen, bone marrow, and liver (16). We have found only one previous report by Fakhar M. et al. presenting a 27-year old male with *L. infantum* and *Brucella* co-infection from Iran (17). It seems that immunological interaction mechanisms between this organism and other intracellular pathogens exist and often inhibit the occurrence of co-infection.

It is important to diagnose Kala-azar, because it is treatable and also mostly fatal if it is not treated. In differential diagnosis of massive splenomegaly and fever, this disease has to be kept in mind. In rapid and early diagnosis of visceral leishmaniasis (VL), especially in areas where diseases such as brucellosis, malaria, typhoid, and tuberculosis are endemic, and in cases which have clinical signs of other similar conditions for VL, a differential diagnosis with appropriate laboratory analyses must be performed.

It has to be considered that there may be a co-infection of brucellosis and kala-azar in etiology of pancytopenia and hepatosplenomegaly in endemic regions.

## References

1. Kar K. Serodiagnosis of leishmaniasis. *Crit Rev Microbiol* 1995;21:123-52.
2. Garcia LS, Bruekner DA. *Diagnostic Medical Parasitology*. Fourth Edition, Washington DC: ASM Pres, 2001:205-34.
3. Unat EK, Yucel A, Atlas K, Samasti M, Unat'ın *Tip Parazitolojisi*. 5. baskı. İstanbul: Cerrahpasa Tip Fak. Yayını 1995:564-86.
4. Murray HW, Berman JD, Davies CR, Saravia NG. Advances in leishmaniasis. *Lancet* 2005;366:1561-77.

5. Murray HW. Clinical and Experimental Advances in Treatment of Visseral Leishmaniasis. *Antimicrob Agents Chemother* 2001;45:2185-97.
6. Minodier P, Garnier JM. Childhood visceral leishmaniasis in Provence. *Arch Pediatr* 2000;7:572-77.
7. WHO Division of Control of Tropical Diseases: Leishmaniasis Control, 1998.
8. Ozensoy S, Ozbel Y, Turgay N, Alkan MZ, Gul K, Gilman-Sachs A, et al. Serodiagnosis and epidemiology of visceral leishmaniasis in Turkey. *Am J Trop Med Hyg* 1998;59:363-9.
9. Aydođdu İ, Diñcer SL. Non-epidemiological kala-azar cases in Turkey. (letter) *Acta Paediatr* 1995;84:1034.
10. Kocabař E, Antmen B, Alhan E, Yıldıztař D, Aksaray N. Çocukluk çağında kala-azar. *Çukurova Üniversitesi Tıp Fakültesi Dergisi* 1998;23:95-101.
11. Wyler DJ, Leishmaniasis in Behrman, RE, Kliegman RM, Arvin, A.M. (Eds): *Nelson Text Book of Pediatrics*, WB Saunders Co, 1992;14:892-94.
12. American Academy of Pediatrics, 1997 Red Book: Report of the Committee on Infectious Diseases, Twenty-Fourth Edition, 1997:321-23.
13. Lim ML, Rickman LS. Brucellosis, *Infect Dis Clin Pract* 2004;12:7-14.
14. Sözen TH: Bruselloz, "Topçu AW, Söyletir G, Dođanay M (eds): *İnfeksiyon Hastalıkları*, 2. baskı" kitabında s. 636-42, Nobel Tıp Kitabevleri, İstanbul (2002).
15. Tansel Ö, Yavuz M, Kulođlu F Akata F. Trakya Üniversitesi Hastanesi'ne başvuran 40 bruselloz olgusunun deđerlendirilmesi, *İnfeksiyon Derg* 2003;17:1-4.
16. Sundar S, Rai M. Clinical and diagnostic laboratory immunology, *Sept* 2002;951-58.
17. Fakhar M, Banimostafavi E, Motazedian MH, Asgari Q. Co-infection of *Leishmania infantum* and *Brucella* spp in Iran. *Comp Clin Pathol* 2009;18:93-4.