

## THE USAGE OF LOW-DOSE LIDOCAINE FENTANYL IN INTRAVENOUS REGIONAL ANESTHESIA

Abdulmenap Guzel<sup>1</sup>, Feyzi Celik<sup>1\*</sup>, Öznur Uludağ<sup>2</sup>, Erdal Dogan<sup>1</sup>, Celil Alemdar<sup>3</sup>, Besir Yildirim<sup>1</sup>

1. Department of Anesthesiology, Dicle University, Diyarbakir, TURKEY.

2. Department of Anesthesiology, Education and Research Hospital, Adiyaman, TURKEY.

3. Department of Orthopaedics and Traumatology, Dicle University, Diyarbakir, TURKEY.

### Abstract

We aimed to present our IVRA practices by adding low-dose lidocaine fentanyl for the patients who have undergone forearm and hand surgery.

After approval Ethics Committee and the permission of patients, 36 patients which were undergone elective, forearm or hand surgery, aged 18-60 years, were included in the study. The intravenous route was opened with 20 G cannula from the hand back (dorsum) which will operated and double-cuffed pneumatic tourniquet was inserted into the arm proximal. The arm was uplift for ten minutes and had veins drained by firmly wrapping the arm from finger tips towards shoulder to distal arm with the Esmarch bandage. First, the proximal cuff was inflated so as to be 150 mmHg more than systolic pressure. The distal cuff was lowered and the Esmarch bandage was removed. The 100 mg lidocaine+100 µg fentanyl from the IV cannula on the hand back which will be operated, was given in 40 ml and the distal cuff was inflated after 5 min then proximal cuff was put out.

The sensory block was assessed and sensory block initial time and motor block initial time was recorded. The regression times of sensory and motor block were recorded. Also the complications during and after the operation were recorded.

Duration of surgery was determined as 30.3±10.1 min and the duration of tourniquet was 41.3±9.1 min. Sensory block initial time was recorded as 8.1±2.6 min, and the time for sensory block regression was recorded as 6.2±3.1 min. The motor block initial time was recorded as 13.4±5.2 min and motor regression time was recorded as 5.6±2.8 min. The clinical diagnoses of the patients were shown in Table 2. According to the VAS scores, it was observed that adequate level of anesthesia and analgesia was maintained for all patients.

The addition of low-dose lidocaine to fentanyl in IVRA may provide both sufficient and effective anesthesia and decrease the complications related with local anesthetic toxicity.

*Clinical article (J Int Dent Med Res 2013; 6: (2), pp. 96-99)*

**Keywords:** Low-Dose Lidocaine, Rejyonal Intravenoz Anesthesia, Upper Extremity.

Received date: 05 May 2013

Accept date: 29 July 2013

### Introduction

The intravenous regional anesthesia (IVRA) which was defined by Bier for the first time is a method that is easy to apply for daily distal upper extremity surgery which will take less

than an hour, having fast onset of action and providing efficient anesthesia<sup>1,2</sup>.

It also is cost-effective when compared with general anesthesia and peripheral nerve blocks and its success rate is between 94-98%<sup>3</sup>. However, the usage of local anesthetics at higher volumes and concentrations has the disadvantages such as poor postoperative analgesia and the emergence of unwanted systemic toxic signs of local anesthetics in case the tourniquet is opened earlier<sup>4</sup>.

Due to these disadvantages, the usage of RIVA is limited. Various adjuvant agents were added by reducing the dose of local anesthetic in

#### \*Corresponding author:

Dr. Feyzi Çelik  
Dicle University Medical School  
Department of Anesthesiology and Reanimation  
Diyarbakır, Turkey

E-mail: drfeyzicelik@gmail.com

order to speed up the start of anesthesia, prolong the duration of postoperative analgesia and avoid unwanted systemic toxic effects of local anesthetics<sup>4,5</sup>. With the demonstration of presence of opioid receptors in the peripheral nervous system, IVRA has also been used with opioids local anesthetics<sup>6</sup>.

In our study, we aimed to present our IVRA practices by adding low-dose lidocaine fentanyl for the patients who have undergone forearm and hand surgery.

### Materials and methods

Following the approval of the Ethics Committee and the permission of patients, ASA I-II Group of 36 patients which were undergone elective, forearm or hand surgery, aged 18-60 years, were included in the study. The patients with a history of uncontrolled hypertension, epilepsy, heart, liver and kidney dysfunction, diabetic neuropathy, vascular disease and allergy to drugs used were excluded from the study.

In all cases, 7 ml/kg/h crystalloid infusion was given by opening the IV route from hand back upon which cannot be operated. The intravenous route was opened with 20 G cannula from the hand back (dorsum) which will operated and double-cuffed pneumatic tourniquet (Tourniquet 5800 ELC, Germany) was inserted into the arm proximal. The arm was uplift for ten minutes and had veins drained by firmly wrapping the arm from finger tips towards shoulder to distal arm with the Esmarch bandage. First, the proximal cuff was inflated so as to be 150 mmHg more than systolic pressure (provided that the minimum tourniquet pressure is 250mmHg). The distal cuff was lowered and the Esmarch bandage was removed. The 100 mg lidocaine+100 µg fentanyl from the IV cannula on the hand back which will be operated, was given in 40 ml and the distal cuff was inflated after 5 min then proximal cuff was put out.

The sensory block was assessed by pinprick test and sensory block initial time was recorded. It was assessed by looking at the movements of the motor block finger and wrist (0 = no loss of motor function, 1 = slight loss of power, 2 = complete loss of power) and motor block initial time was recorded. The post sensory block operation was started. The additional need of analgesic fentanyl during the operation was provided with 1-2 µg/kg. The 1.5 µg/kg tramadol

iv was given to all patients for postoperative analgesia preemptively.

The hemodynamic and respiratory parameters of the cases and VAS (0 = no pain - 10 = very severe pain) values were recorded before tourniquet, after tourniquet and at intervals of 5 minutes after drug injection. After the surgical operation and lowering the distal tourniquet, the regression times of sensory block and motor block were recorded. If the duration of operation is less than 30 min, it was waited for 30 min elapsed in order to lower the tourniquet. Also the complications during and after the operation were recorded.

### Statistical Analysis

For the statistical analysis, SPSS (Statistical Package for Social Sciences) for Windows program was used. The chi-square test was used for the data obtained by the count, student-t test for the data obtained by measurement was used. P <0.05 was considered significant.

### Results

The demographic data of the patients included in the study were presented in Table 1. 17 of the patients included in the study were male and 15 were female. Duration of surgery was determined as 30.3±10.1 min and the duration of tourniquet was 41.3±9.1 min (Table 1).

Age (years)	39.03 ± 20.52
Gender M/F (person)	18 / 15
Height (cm)	165.39± 7.53
Weight (kg)	69.24 ± 11.95
ASA I/II	31/ 2
Surgery time (min)	30.3±10.1
Tourniquet time (min)	41.3±9.1

**Table 1.** Demographic characteristics and duration of surgery and tourniquet.

Sensory block initial time was recorded as 8.1±2.6 minutes, and the time for sensory block regression was recorded as 6.2±3.1 minutes. The motor block initial time was recorded as 13.4±5.2 minutes and motor regression time was recorded as 5.6±2.8 minutes. The clinical diagnoses of the patients were shown in Table 2.

33.3% of the patients were operated by the indication of carpal tunnel syndrome.

According to the VAS scores/values taken in the intraoperative and postoperative period, it was observed that adequate level of anesthesia and analgesia was maintained for all patients (Table 3).

Clinical diagnosis	n	%
Carpal tunnel syndrome	11	33.3
Wrist fracture/dislocation	7	21.3
Mass on hand/finger	7	21.3
Radius distal fracture	2	6.1
Foreign body on hand and wrist	4	12.2
Tendon section	2	6.1
n : number		

Table 2. The clinical diagnosis of cases.

Viewed times/durations	VAS scores (Mean±SD)
Before Tourniquet	0
After Tourniquet	
5.min	2.9± 1.8
10.min	2.1±1.6
15.min	2.0± 1.7
20.min	1.9±1.8
25.min	1.8±1.9
30.min	1.7±1.9
35.min	1.8±1.3
40.min	1.6±1.4
45.min	2.5±0.6
Postoperative 0. min	2.3±1.2
Postoperative 15. min	2.5±0.7
Postoperative 30. min	1.9±0.5
Postoperative 60. min	2.2±1.2
Postoperative 120. min	1.8±1.6

Table 3. Intraoperative VAS scores/values.

The findings were given in mean±standard deviation  
 min: minutes

It was observed that the hemodynamic parameters remained stable before and after the operation (Figure-1). No serious complications were observed in any of the patients throughout the process.

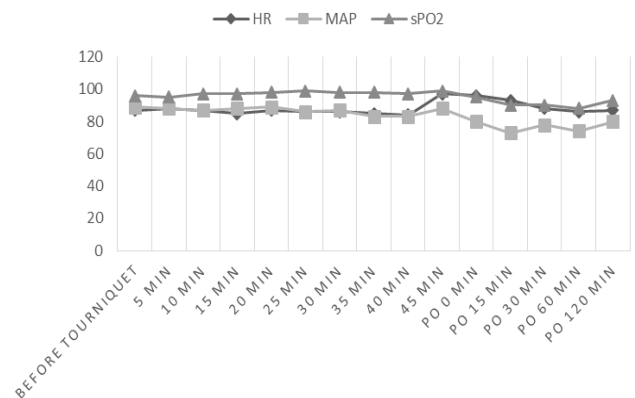


Figure 1. The MAP, HR and sPO<sub>2</sub> values of the cases.

### Discussion

The most important of the recent debates/discussions ongoing about IVRA is the most appropriate drug and dose of the drug to be used while applying the technique. The ideal IVRA solution block should have the properties such as rapid onset, the use of low-dose local anesthetic and providing low tourniquet pain. For this purpose, local anesthetics adjuvant agents (opioids, clonidine, dexmedetomidine, nonsteroidal antiinflammatory drugs, dexamethasone) were added in IVRA in order to both accelerate the formation of the sensory-motor block and lessen the need for post-operative analgesic agents by increasing the quality of anesthesia and also the effects of these agents were studied<sup>7-10</sup>. The most important contribution of adjuvant agents is reducing the incidence of the risk of local anesthetic toxicity while increasing the anesthetic and analgesic efficiency by using less local anesthetic due to additive effect<sup>11</sup>.

In this study, we aimed to present that the IVRA solution which was prepared by adding 100 µg fentanyl to 100 mg lidocaine would provide adequate level of surgical anesthesia.

The sensory block onset times, sensory block regression times and motor block onset times and motor block regression times viewed/taken in our study were at the level allowing the surgical anesthesia and the results were found to be similar with those in the studies performed by using higher dose of local anesthetic<sup>12</sup>.

The systemic local anesthetics toxicity which is the most common in the studies regarding IVRA was stated to be observed in

related with the inadequate tourniquet pressure and lowering the tourniquet earlier. It was also stated that the lidocaine may cause to toxicity even at the dose of 1.4 mg/kg and the cardiac arrest was observed at the dose of 2.5 mg/kg lidocaine<sup>11</sup>.

In our study, the tourniquet time was  $41.3 \pm 9.1$  min, however no complication occurred despite the inclusion of 100 mg lidocaine+100 µg fentanyl into the circulation due to lowering the tourniquet accidentally in 3 patients. For this reason, we think that the dose of local anesthetic we used is safe.

One of the major disadvantages of IVRA is the disappearance of analgesia rapidly once the tourniquet is opened and that it requires postoperative analgesic usage. The effects of adjuvant agents used in the studies upon the duration of postoperative analgesia were investigated. It was reported that the addition of clonidine to lidocaine in IVRA did not increase the duration of postoperative analgesia<sup>13</sup>. The lower postoperative VAS values in our study may be due to tramadol we used preemptively.

## Conclusions

As a result, the addition of low-dose lidocaine to fentanyl in IVRA may provide both sufficient and effective anesthesia and decrease the complications related with local anesthetic toxicity.

## Declaration of Interest

The authors report no conflict of interest and the article is not funded or supported by any research grant.

## References

1. Hilgenhurst G. The Bier block after 80 years: a historical review. *Reg Anesth* 1990; 15: 2-5.
2. Chilvers CR, Kinahan A, Vaghadia H, et al. Pharmacoeconomics of intravenous regional anaesthesia vs general anaesthesia for outpatient hand surgery. *Can J Anaesth* 1997; 44: 1152-56.
3. Choyce A, Peng P. A systematic review of adjuncts for intravenous regional anesthesia for surgical procedures. *Can J Anaesth* 2002; 49: 32-45.
4. Memis D, Turan A, Karamanlioglu B, et al. Adding dexmedetomidine to lidocaine for intravenous regional anesthesia. *Anesth Analg* 2004; 98: 835-40.
5. Lurie SD, Reuben SS, Gibson CS, et al. Effect of clonidine on upper extremity tourniquet pain in healthy volunteers. *Reg Anesth Pain Med* 2000; 25: 502-05.
6. Sakirgil E, Gunes Y, Ozbek H, et al. [Comparison of ropivacaine, ropivacaine plus tramadol and ropivacaine plus morphine in patients undergoing minor hand surgery]. *Agri* 2005; 17: 52-8.

7. Turan A, Karamanlioglu B, Memis D, Kaya G, Pamukcu Z. Intravenous regional anesthesia using prilocaine and neostigmine. *Anesth Analg* 2002; 95: 1419-22.
8. Bigat Z, Boztug N, Çete N, Hadimoğlu N, Ertok E. RİVA'da lidokain ve lidokain'e eklenen tenoksikam ve deksametazonun karşılaştırılması. *Türk Anest Rean Der* 2004; 32: 200-6.
9. Kleinschmidt S, Stöckl W, Wilhelm W, Larsen R. The addition of clonidine to prilocaine for intravenous regional anaesthesia. *Eur J Anaesthesiol* 1997; 14: 40-6.
10. Turan A, Memis D, Karamanlioglu B, Güler T, Pamukcu Z. Intravenous regional anesthesia using lidocaine and magnesium. *Anesth Analg* 2005; 100: 1189-92.
11. Guay J. Adverse events associated with intravenous regional anesthesia (Bier block): a systematic review of complications. *J Clin Anesth* 2009; 21: 585-94.
12. Sen S, Ugur B, N.Aydın O, Ogurlu M, Gursoy F, Savk O. The Analgesic Effect of Nitroglycerin Added to Lidocaine on Intravenous Regional Anesthesia. *Anesth Analg* 2006; 102: 916-20.
13. Ivie CS, Viscomi CM, Adams DC, Friend AF, Murphy TR, Parker C. Clonidine as an adjunct to intravenous regional anesthesia: A randomized, double-blind, placebo-controlled dose ranging study. *J Anaesthesiol Clin Pharmacol* 2011; 27: 323-7.