

## AN UNUSUAL CASE: NEUROFIBROMATOSIS TYPE 5

Michele Callea<sup>1\*</sup>, S. Zelal Baskan Ulku<sup>2</sup>, Sandra Giustini<sup>3</sup>, Izzet Yavuz<sup>4</sup>, Michele Maglione<sup>5</sup>,  
Refik Ulku<sup>6</sup>, Marco Montanari<sup>7</sup>, Guvenc Basaran<sup>8</sup>, Filippo Battelli<sup>7</sup>, Ahmet Gunay<sup>9</sup>, Gabriella Clarich<sup>1</sup>,  
Bayram Ince<sup>10</sup>, Matteo Ceccarello<sup>11</sup>

1. Department of Maxillo-Facial and Paediatric Dentistry, Institute for Maternal and Child Health-IRCCS Burlo Garofolo-Trieste, Italy.
2. Department of Prosthetic Dentistry, Faculty of Dentistry, Dicle University, Diyarbakir, Turkey.
3. Department of Dermatology, University of Rome Sapienza, Rome, Italy.
4. Department of Pediatric Dentistry, Faculty of Dentistry, Dicle University, Diyarbakir, Turkey.
5. Unit of Oral Surgery, Dental School, Department of Biomedicine, University of Trieste.
6. Department of Thoracic Surgery, Faculty of Medicine, Dicle University, Diyarbakir, Turkey.
7. Unit of Dentistry for Disabled Department of Oral Science, Alma Mater Studiorum, University of Bologna, Via San Vitale 59 40125 Bologna, Italy.
8. Department of Orthodontics, Faculty of Dentistry, Dicle University, Diyarbakir, Turkey.
9. Department of Periodontology Dentistry, Faculty of Dentistry, Dicle University, Diyarbakir, Turkey.
10. Department of Restorative Dentistry, Faculty of Dentistry, Dicle University, Diyarbakir, Turkey.
11. Institute for Maternal and Child Health - IRCCS Burlo Garofolo – Trieste, Italy.

### Abstract

Neurofibromatosis is a disease which includes 5 types in its classification. It has been firstly described by Robert Smith in 1849, but its name comes from the first publication in 1882, in which Von Recklinghausen convinced the scientific and medical world that Neurofibromatosis (NF) was a distinct entity.

Cafe-au-lait spots, cutaneous neurofibromas and Lisch nodules are the characteristics of the most common forms. Bilateral acoustic neuromas distinguish the type 2. Type 3, Riccardi type and intestinal type are briefly described.

Neurofibromatosis type 5 (NF5) is characterized by cafe-au-lait spots restricted to one area of the body. We report oro-dental phenotype of a patient affected by NF type 5, rare per se and unreported in literature.

*Case report (J Int Dent Med Res 2012; 5: (2), pp. 102-105)*

**Keywords:** Neurofibromatosis type 5, Oral Manifestation.

**Received date:** 03 November 2011

**Accept date:** 30 March 2012

### Introduction

Neurofibromatosis (NF) is a relatively common disorder characterized by neurological and cutaneous lesions. Lesions in all the oral soft tissues have, been noted, with a prevalence reported of less than 10%<sup>1</sup>, 26%<sup>2</sup>, and up to 72% of patients in a review that included mucosal abnormalities such as

enlargement of the fungiform papillae but lacked histopathologic diagnosis<sup>3</sup>. At least one intraoral or radiographic sign of NF was found in 92% of patients. Von Recklinghausen's disease (NF-1) and bilaterally acoustic NF (NF-2) are major forms.

Neurofibromatosis type 5 and its manifestations, especially the dental ones, are unreported. Bruxism is a common parafunctional habit, occurring both during sleep and wakefulness. The etiology is multifactorial. There is no known treatment to stop bruxism.

The role of bruxism in the process of tooth wear is unclear, but it is not considered a major cause. Grinding of teeth has long been held as one physical manifestation of stress and anxiety. Systemic conditions affecting the pulp are

#### \*Corresponding author:

Dr. Michele Callea  
Maxillo-Facial Surgery and Paediatric Dentistry,  
Institute for Maternal and Child Health – IRCCS  
"Burlo Garofolo"-Trieste, Italy

E-mail: mcallea@gmail.com

seldom documented and appear to be extremely uncommon. On reviewing the literature, no reports of pulpal pathology have been found in NF<sup>4</sup>.

### Case Report

We report a case of a 12 years old young male who came to our attention for dental pain. An accurate oral examination revealed an insufficient oral hygiene, few and not deep caries in the primary dentition, affected by evident bruxism visible at first sight .

Ortopantomography (Fig.1), which enhances dental grindings and occlusal erosion of deciduous molars and a Teleradiography (Fig.2) have been carried out. They revealed a delayed development of the root of permanent premolars.

The occlusion revealed a first skeletal class, confirmed by the examination of the cephalometry. In our case, after an instruction of oral hygiene, a follow up of 2 years has been carried out, and the decision to wait for natural exfoliation of the primary molars was taken for the first years, to control the level of bruxism.

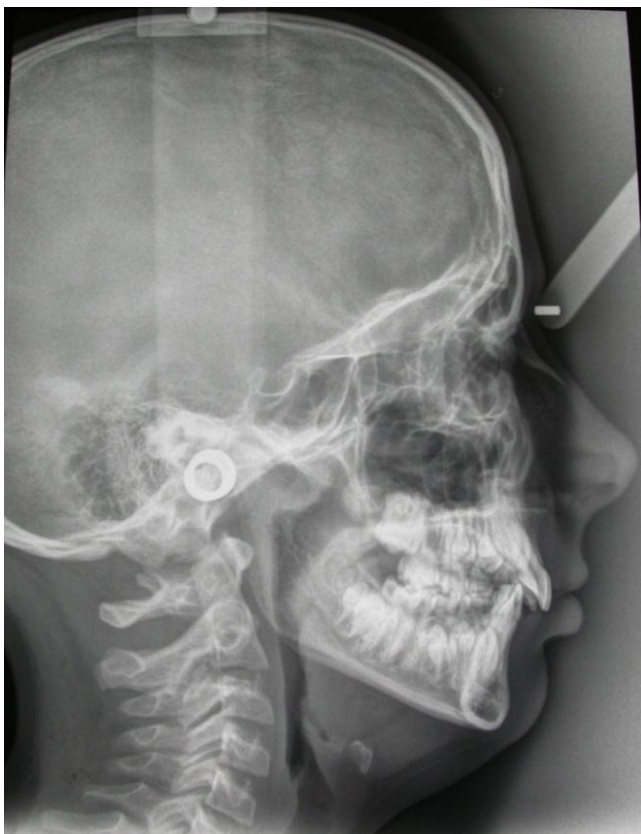

Figure 2. Teleradiography.

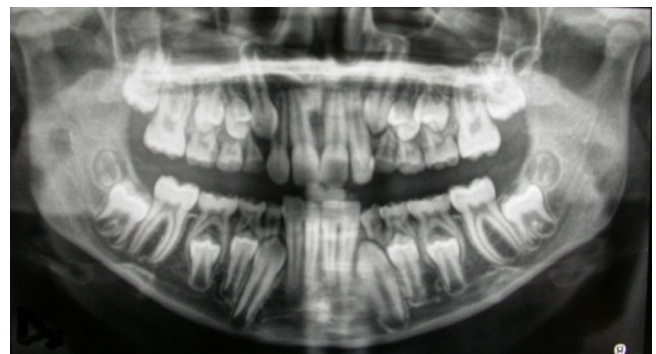


Figure 1. Ortopantomography which enhances dental grindings and occlusal erosion of deciduous molars.

The erosion due to attrition of the central maxillary incisors led us to the decision of their aesthetic and functional reconstruction, and whether this might reveal successful, a further follow-up without any intervention will be carried out. A bite to avoid further erosion might be a good solution, knowing that stress is one of the main causes of bruxism and in a patient with NF5 often undergoing to instrumental examination is understandable. However, considering stress unusual between infancy and adolescence, we should not underestimate the role played by occlusal precontact which is present in our case. Bruxism and in general oral findings in segmented NF (NF5) are unreported.

### Discussion

Neurofibromatosis is a diseases which mostly appears in 2 type, but a third, a fourth and a fifth are as well reported (5,6). Neurofibromatosis type 1 accounts for the 90% of the cases and is the classic form. Major features includes six or more cafe-au lait-spots, cutaneous neurofibromas and Lisch nodules. The inheritance is autosomal dominant and it's caused by a mutation in a tumour suppressor gene which maps to chromosome region 17q11.2<sup>5,6</sup>. The hallmark of NF type 2 (NF2) consists of bilateral acoustic neuromas. NF2 is caused by mutation in a tumor suppressor gene which maps to chromosome region 22q12.2. Thorax and lungs are affected in various forms. The patients have dyspnea, cough and chest pain.

Thoracic manifestations of neurofibromatosis are such as upper airway, chestwall, mediastinal, thoracic neoplasms, and

lung parenchyma. Rib abnormalities are common in patients with NF. They have been described as twisted ribbon deformity. Notching of the ribs occurs secondary to erosion by intercostal neurofibromas or a primary defect in bone formation<sup>7,8</sup>.

In NF3 (Riccardi type) cafe-au lait-spots are usually pale, few in number and may be large<sup>4,6,9</sup>.

In NF3 intestinal type, neurofibromatous involvement is limited to the gastrointestinal tract. NF4 is a category of different phenotypes for those patients who do not fit close into any other known type. Segmented Neurofibromatosis type 5 (NF5) is a rare disease 30 time less common than Neurofibromatosis type 1. Neurofibromas and cafe-au lait-spots have been frequently reported restricted to one area of the body<sup>10,11-14</sup>.

Evidence is consistent with mosaicism for NF1 mutations<sup>11,13</sup>.

Oral manifestation in segmented neurofibromatosis are unreported. Most common oral findings in neurofibromatosis are oral neurofibromas, enlarged fungiform papilla, intrabony lesions, wide inferior alveolar canals and enlarged mandibular foramina. Tumor of the tongue and tongue lesions are reported in literature as well as malposition of the teeth. No enamel or dentin deficiency are reported but increased bone density, enlarged mandibular foramen and increased dimensions of coronoid notch<sup>5-11</sup>.

Neurofibromatosis type 5 and its manifestations, especially the dental ones, are unreported. On the other hands bruxism at young ages is becoming more and more frequent, and our hypothesis is that, since stress is the first cause of bruxism<sup>15</sup>. Bruxism is an habit that can have a negative effect on the quality of life of affected individuals by damaging the teeth, periodontium, facial muscles, and the temporomandibular joint<sup>16-19</sup>.

The long-term follow-up and instrumental and multidisciplinary examination may put under stress very young patients. Considering stress unusual between infancy and adolescence, we should not underestimate the role played by occlusal precontact which is present in our case. It is common for dentists to confect musclerelaxing bite plates for patient to be used while sleeping in order to protect the teeth and periodontium<sup>20-22</sup>.

## Conclusions

Moreover, the use of a bite to reduce the erosion of the surface of the teeth is not appropriate and a strict surveillance of young patients, along with a correct oral hygiene, seems to be the best choice, unless a selective reducing or totally eradicating precontact can rise a good result.

## Acknowledgements

We thank the family for allowing us with written consent publication of clinical data and images, the study has been supported by a Clinical Research Fellow of the Institute for Child and Maternal Health of Trieste.

## Declaration of Interest

The authors report no conflict of interest and the article is not funded or supported by any research grant.

## References

1. Baden E, Jones JR, Khedekar R, Burns WA. Neurofibromatosis of the tongue: a light and electron microscopic study with review of the literature from 1849-1981. *J Oral Med* 1984;39:157-64.
2. D'Ambrosio JA, Langlais RP, Young RS. Jaw and skull changes in ueurofibromatosis. *Oral Surg* 1988;66:391-6.
3. Shapiro SD, Abramovitch K, Van Dis ML, Skoczylas LJ, Langlais RP, Jorgenson RJ, Young RS, Riccardi VM. Neurofibromatosis: oral and radiographic manifestations. *Oral Surg Oral Med Oral Pathol*. 1984 Oct;58(4):493-8.
4. Curtin JP, McCarthy SW. Perineural fibrous thickening within the dental pulp in type 1 neurofibromatosis: a case report. *Oral Surg Oral Med Oral Pathol Oral Radiol Endod*. 1997 Oct;84(4):400-3.
5. Adigun CG, Stein J. Segmental neurofibromatosis. *Dermatol Online J*. 2011 Oct 15;17(10):25.
6. Maldonado Cid P, Sendagorta Cudós E, Noguera Morel L, Beato Merino MJ. Bilateral segmental neurofibromatosis diagnosed during pregnancy. *Dermatol Online J*. 2011 May 15;17(5):6.
7. King Jr TE, Zamora AC. Neurofibromatosis 2006; 92-97
8. Çamsarı G, Gür A, Özkan G, Bakan ND, Zengin F, Külcü A. Thoracic findings in neurofibromatosis J of tuberculosis and thorax. 2006; 54: 267-72
9. Johansson A, Omar R, Carlsson GE. Bruxism and prosthetic treatment: a critical review. *Journal of prosthodontic research* 55, 2011:127-136.
10. Sutin AR, Terraciano A, Ferrucci L, Costa PT. Teeth grinding: Is emotional stability related to bruxism. *Journal of research in Personality* 44, 2010;402-404.
11. Cabral R, Santiago F, Tellechea O. Multiple glomus tumors and segmental neurofibromatosis: there are no coincidences. *Dermatol Online J*. 2011 Mar 15;17(3):4.
12. Mansur AT, Göktay F, Akkaya AD, Güneş P. Segmental neurofibromatosis: report of 3 cases. *Cutis*. 2011 Jan;87(1):45-50.
13. Messiaen L, Vogt J, Bengesser K, Fu C, Mikhail F, Serra E, Garcia-Linares C, Cooper DN, Lazaro C, Kehrer-Sawatzki H. Mosaic type-1 NF1 microdeletions as a cause of both generalized and segmental neurofibromatosis type-1 (NF1). *Hum Mutat*. 2011 Feb;32(2):213-9. doi: 10.1002/humu.21418.

14. Dang JD, Cohen PR. Segmental neurofibromatosis and malignancy. *Skinmed*. 2010 May-Jun;8(3):156-9.
15. Messiaen L, Vogt J, Bengesser K, Fu C, Mikhail F, Serra E, Garcia-Linares C, Cooper DN, Lazaro C, Kehrer-Sawatzki H. Mosaic type-1 NF1 microdeletions as a cause of both generalized and segmental neurofibromatosis type-1 (NF1). *Hum Mutat*. 2010 Nov 30.
16. Morais P, Ferreira O, Bettencourt H, Azevedo F. Segmental neurofibromatosis: a rare variant of a common genodermatosis. *Acta Dermatovenerol Alp Panonica Adriat*. 2010 Oct;19(3):27-9.
17. de la Hoz-Aizpurua JL, Díaz-Alonso E, LaTouche-Arbizu R, Mesa-Jiménez J. Sleep bruxism. Conceptual review and update. *Med Oral Patol Oral Cir Bucal*. 2011 Mar 1;16(2):e231-8.
18. Broliato GA, Volcato DB, Reston EG, Kramer PF, Marquezan M, Ruzzarin F, Spiguel MH. Esthetic and functional dental rehabilitation in a patient with gastroesophageal reflux. *Quintessence Int*. 2008 Feb;39(2):131-7.
19. Ohayon MM, Li KK, Guilleminault C. Risk factors for sleep bruxism in the general population. *Chest* 2001;119:53–61.
20. Vanderas AP, Papagiannoulis L. Multifactorial analysis of aetiology of craniomandibular dysfunction in children. *Int J Paediatr Dent* 2002;12:336–46.
21. Huynh N, Lavigne GJ, Okura K, Yao D, Adachi K. Sleep bruxism. In: Montagna P, Chokroverty S editors. *Handbook of clinical neurology: sleep disorders, Part II*. Amsterdam: Elsevier, 2011; 901–11.
22. Onodera K, Kawagoe T, Sasaguri K, Protacio- Quismundo C, Sato S. The use of a bruxchecker in the evaluation of different grinding patterns during sleep bruxism. *Cranio* 2006; 24: 292–299.