

## RIGA'S PAPILOMA IN A 3 MONTH OLD INFANT: A CASE REPORT

Sonali Saha<sup>1\*</sup>, Firoza Samad<sup>2</sup>, Sabyasachi Saha<sup>3</sup>, Fahad Mansoor Samad<sup>4</sup>

1. Senior Lecturer, Department of Pedodontics, Sardar Patel Postgraduate Institute of Dental and Medical Sciences, Lucknow, India.
2. Professor & Head, Department of Pedodontics, Sardar Patel Postgraduate Institute of Dental and Medical Sciences, Lucknow, India.
3. Professor & Head, Department of Public Health Dentistry, Sardar Patel Postgraduate Institute of Dental and Medical Sciences, Lucknow, India.
4. Senior Lecturer, Department of Oral & Maxillofacial Pathology, Sardar Patel Postgraduate Institute of Dental and Medical Sciences, Lucknow, India.

### Abstract

Riga's papilloma or Cardarelli's apthae describes ulceration on the ventral of the tongue in neonates and infants. It is often associated with natal or neonatal teeth. It may rarely occur in older infants. Failure to diagnose and properly treat this lesion can result in inadequate nutrient intake for the infant.

Treatment should begin conservatively and should focus on eliminating the source of trauma. The purpose of this study is to describe a clinical case of an infant with Riga's papilloma on the ventral of the tongue along with the clinical management. The case is very interesting and can be very useful to Pediatric Dentists. A 3 month-old male infant reported for evaluation of a neonatal tooth that was erupting in the mandibular anterior region together with a non-healing oral ulcer. The tooth was not present at the time of his birth.

Intra Oral examination revealed one firm tooth crown in the mandibular anterior central incisor region. Examination also revealed ulceration on the ventral surface of tongue. As the neonatal tooth was the cause of the ulceration and pain, extraction of the tooth was chosen as treatment of choice. Patient was re-examined after 3 weeks. Examination revealed complete healing of the ulcer and the extraction socket.

With subsequent patient follow-up (at 7 months of age), an occlusal radiograph revealed erupting mandibular central incisors. Hence it was possible to conclude that the neonatal tooth had been a supernumerary.

*Case report (J Int Dent Med Res 2011; 4: (1), pp. 12-16 )*

**Keywords:** Riga's papilloma, Cardarelli's apthae, natal and neonatal teeth, traumatic ulcer.

**Received date:** 10 September 2010

**Accept date:** 04 March 2011

### Introduction

'Riga's papilloma' is a rare, benign traumatic ulceration on the ventral surface of the tongue in neonates and infants typically between 1 week and 1 year of age<sup>1,2</sup>. It is frequently associated with natal, neonatal, or primary lower incisor teeth<sup>3</sup>. The lesion was first described by Antonio Riga, an Italian physician, in 1881<sup>4</sup>.

Histologic studies and additional cases

were subsequently published by F. Fede in 1890. It has been subsequently known as 'Riga's boil' or 'Riga's disease'<sup>5</sup>.

Typically, the benign lesion begins as an ulcerated area on the ventral surface of the tongue exposed to repeated trauma from a natal or neonatal tooth<sup>2</sup>. With repeated trauma, it may progress to an enlarged fibrous mass and resemble a traumatic ulcerative granuloma (with stromal eosinophilia). Often, the lesion develops a rolled white hyperkeratotic border immediately adjacent to the ulceration. Occasionally, the underlying proliferative granulation tissue results in a raised exophytic lesion similar to a pyogenic granuloma<sup>6</sup>.

The clinical presentation many resemble squamous cell carcinoma causing concern but are not frequently reported<sup>7,8</sup>.

#### \*Corresponding author:

Dr. Sonali Saha (Senior Lecturer)  
Department of Pedodontics, Sardar Patel Postgraduate Institute of Dental and Medical Sciences, Rai-bareilly Road, Lucknow, India. Pin- 226025.

E-mail: [sonalisaha24@yahoo.co.in](mailto:sonalisaha24@yahoo.co.in)

It may interfere with proper suckling and feeding and the pain associated with the lesion may put the neonate at risk for dehydration and failure to thrive. In such instances, dental intervention may be required<sup>5,7</sup>.

Treatment should begin conservatively and should focus on eliminating the source of trauma<sup>7-11</sup>. The purpose of this study was to describe a clinical case of an infant with Riga's papilloma on the ventral of the tongue.

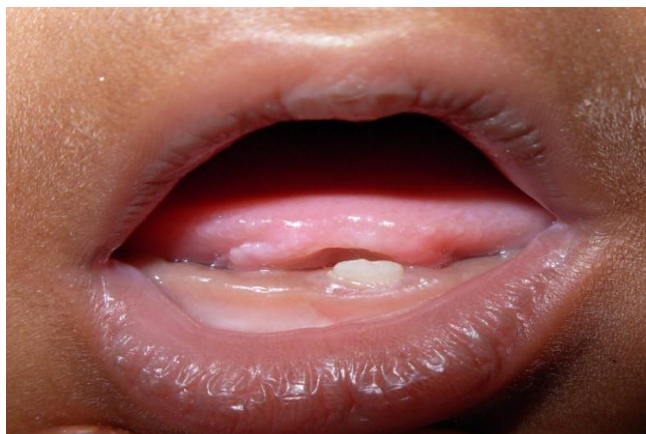### Case Report

A 3 month-old male infant was referred to the out-patient department, Department of Pedodontics, Sardar Patel Postgraduate Institute of Dental & Medical Sciences by his attending paediatrician for evaluation of a neonatal tooth that was erupting in the mandibular anterior region together with a non-healing oral ulcer of approximately 1 month duration. The tooth was not present at the time of his birth. The mother complained of child exhibiting inadequate nutrient intake together with pain during suckling.

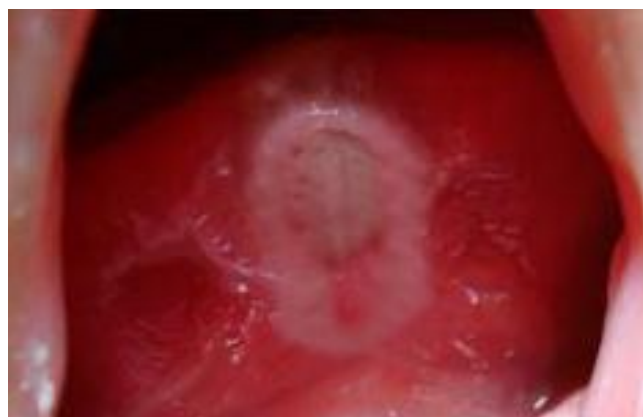A review of his medical chart revealed that he had a birth weight of 1,665 g. Maternal and paternal medical and social histories had no evidence of heredity influence or other significant information.

Intra Oral examination revealed one firm tooth crown, whitish in colour in the mandibular anterior central incisor region (Figure 1).

Examination also revealed 6 mm x 11 mm ulceration on the ventral surface of tongue that extended from anterior border of the tongue to lingual frenum (Figure 2). On palpation, area elicited a pain response from the patient.



**Figure 1.** Intra Oral Photograph of 3 month old infant showing Neonatal Tooth in mandibular anterior region.



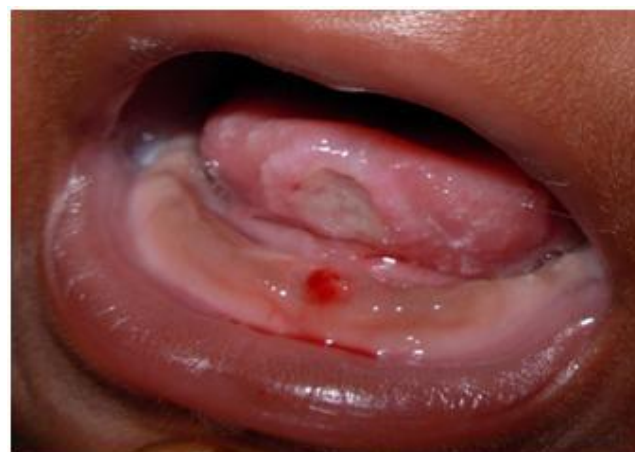**Figure 2.** Intra Oral Photograph showing 'Riga's papilloma' on the ventral surface of the tongue.

Examination of the rest of intraoral mucosa revealed no other lesions.

Difficulty in obtaining a radiograph of the region, due to the child's age, prevented immediate confirmation of whether the tooth in question belonged to the normal series or was a supernumerary.

Based on clinical findings, diagnosis of 'Riga's Papilloma' was made.

As the neonatal tooth was the suspected cause of the ulceration and pain, extraction of the tooth was chosen as treatment of choice. Extraction was carried out under topical local anaesthesia, which the infant tolerated well (Figure 3).

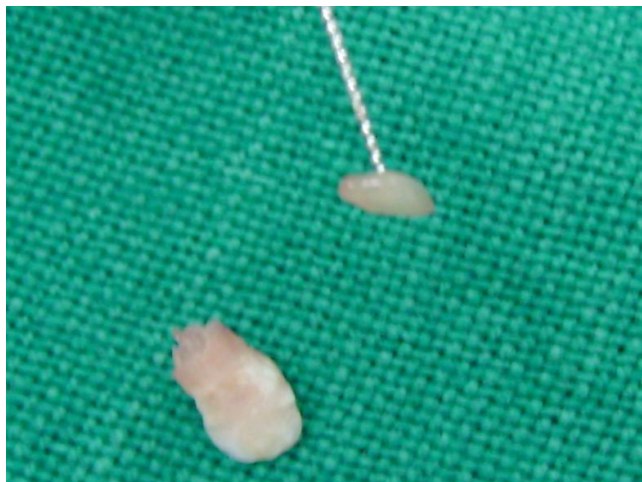

**Figure 3.** After Extraction of Neonatal Tooth.

Clinical examination of the extracted tooth revealed pulp tissue (Figure 4) which was sent for histological examination.

Histological results revealed it to be normal, underdeveloped pulp tissue with sparse innervations and cellular components.

Histological examination of the neonatal tooth showed of thin layer of hypoplastic enamel, atubular dentin and no evidence of root formation (Figure 5).



**Figure 4.** Extracted Tooth with Extirpated Pulp Tissue.

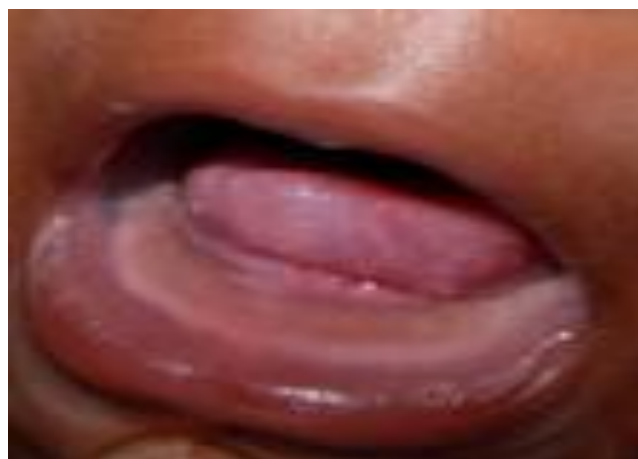

**Figure 5.** Ground section of the neonatal tooth showing irregular arrangement of enamel rods & irregular DE junction.

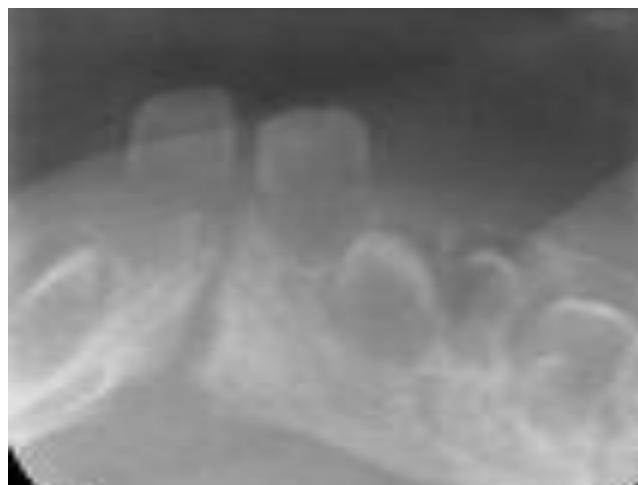
Patient was re-examined after 3 weeks. Examination revealed complete healing of the ulcer and the extraction socket (Figure 6).

The baby appeared to be much more content and the mother reported that her baby was feeding normally and gained weight. With subsequent patient follow-up (at 7 months of age), an occlusal radiograph revealed erupting mandibular central incisors.

Hence it was possible to confirm that the neonatal tooth had been a supernumerary (Figure 7).



**Figure 6.** Healed ulcer after 3 weeks.



**Figure 7.** Mandibular Anterior Occlusal Radiograph taken at 7 Months. Erupting Central Incisors (71, 81) visible.

### Discussion

Infants born with teeth or teeth erupting immediately after birth have appeared in the medical and dental literature<sup>1-5, 7</sup>. These teeth have been referred as 'Natal teeth', 'congenital teeth', fetal teeth, and predeciduous teeth<sup>2, 7</sup>. If the primary teeth erupt during the third to the fifth month of life, they are termed precocious dentition<sup>1, 2</sup>.

According to Massler and Savara<sup>1</sup>, natal teeth indicates teeth present in oral cavity at birth and 'neonatal teeth' are those which erupt during the neonatal period i.e., from birth to thirtieth day of life.

Natal and neonatal teeth are rare in the buccal cavity<sup>3, 4</sup>.

Their incidence has been investigated in many studies. In a 1995 review article, Zhu and



King<sup>3</sup> tabled results from 10 studies dating from 1876 to 1991. For this group, the reported incidence of both natal and neonatal teeth ranged from 1:7160 to 1:30,000. Bodenhoff & Gorlin<sup>4</sup> reported the incidence of natal and neonatal teeth to be 0.3-0.5%. According to Elzay<sup>8</sup>, natal teeth are more frequent than neonatal teeth, ratio being approximately 3: 1.

Previous clinical studies and surveys suggest that more females are affected than males<sup>1-4,9</sup>. In our case the infant is a male child. 76% to 94% of natal and neonatal teeth occur in pairs<sup>1, 2, 6-8</sup>. In the present case, there was a single neonatal tooth present in the lower central incisor region.

The etiology of this anomaly remains unknown, although it has been related to a series of factors, such as superficial positioning of the tooth germ, osteoclastic activity within the tooth germ area (bone remodeling), hereditary factors, endocrine disorders, hypovitaminosis and fever states<sup>2, 7,8,10</sup>.

Three syndromes have been associated with natal teeth: (a) chondroectodermal dysplasia or Ellis-van Creveld syndrome, (b) oculo-mandibulo-dyscephaly with hypotrichosis or Hallermann-Streiff syndrome, and (c) pachyonychia congenita or Jadassohn-Lewandowski syndrome. Natal teeth may also be associated with cleft lip, cleft palate and cyclopia<sup>9</sup>. Clinical studies by Kates *et al.*<sup>6</sup> and Massler and Savara<sup>1</sup> suggested that only 1 to 8 % of natal and neonatal teeth are supernumerary.

However, in the present case, with subsequent patient follow-up (at 7 months of age) and eruption of mandibular central incisors, it was possible to confirm with a radiograph that the tooth had been a supernumerary.

Clinically, natal and neonatal teeth can be normal in size and shape, or conical, with enamel hypoplasia and a yellow-brownish coloration<sup>2-6</sup>. Radiographically, these teeth show low radiopacity, minimal or absent root formation<sup>1-4</sup>.

Ground section of natal and neonatal teeth revealed hypo mineralized enamel, irregular arrangement of enamel rods, irregular dentino-enamel junction, dentinal tubules, more cellular and numerous vascular channels with endothelial cells and large pulp chamber<sup>7,8,11,12</sup>. There was also a failure of root formation despite eruption and a failure of cementum formation<sup>6,8</sup>. This was in accordance with the histological findings in our present case.

Simple chronic traumatic ulcerations occur most often on the tongue, lips, and buccal mucosa (sites usually injured by the dentition). The presence of natal or neonatal teeth may lead to formation of a traumatic ulcer on the ventral surface of the tongue, which is known as Riga's Boil or Riga's apthae<sup>2, 9,10,13,14</sup>. Although usually associated with natal or neonatal teeth, it may also occur in older infants after the eruption of the primary lower incisors<sup>5-7</sup>.

Various terms have been applied to this lesion, including Cardarelli's apthae, Cardarelli's disease, Fede's disease, Riga's apthae, Riga's boil, Riga's papilloma, Riga's disease, Riga-Fede's disease, sublingual ulcer, sublingual granuloma<sup>9,12,15</sup>.

This lesion was of particular concern in Italy in the late 1800s because it was frequently associated with malnourished infants and often resulted in death. In some cases, it was also thought to be diagnostic of whooping cough. Hence it was considered that the lesion was of traumatic origin<sup>7,12</sup>.

Buchanan *et al.*<sup>2</sup> & Elzay *et al.*<sup>8</sup> reported these lesions to be found on the anterior ventral surface of the tongue. In our present case the ulceration extended from anterior border of the tongue to lingual frenum. According to Slayton<sup>11</sup>, the dorsal surface may also be affected. Ventral tongue lesions contact the mandibular anterior incisors whereas dorsal lesions contact the maxillary incisors. Zaenglein *et al.*<sup>9</sup> reported cases on the buccal mucosa, palate, and lip, but the tongue remains to be the most common site of involvement.

Feeding behaviours also contribute to the trauma that causes this type of lesion<sup>13, 15</sup>. Hence, parents are advised to modify their feeding methods to try to avoid the child positioning his tongue over the teeth and to minimize the amount of sucking needed to obtain fluids. This may involve using a bottle with a larger hole in the nipple or a Sippy cup that requires less vigorous sucking<sup>7,9</sup>. According to Jariwala *et al.*<sup>16</sup> the parent can also attempt feeding by spoon to minimize trauma to the tongue.

Treatment should begin conservatively and should focus on eliminating the source of trauma. For traumatic ulcerations that have an obvious source of injury, the irritating cause should be removed first<sup>8-10,14</sup>. Jariwala *et al.*<sup>16</sup> suggested biopsy for lesions that remain for 2 weeks after removal of the cause. Ahmet *et al.*<sup>13</sup>

reported a rare recurrence rate. In case of mild to moderate irritation to the tongue, conservative treatment such as smoothing the incisal edge with an abrasive instrument is advocated<sup>11,14</sup>.

Alternatively, a small increment of composite may be bonded to the incisal edges of the teeth<sup>13</sup>.

In this case, ulcerated area was large and denuded and even a reduced incisal edge may still contact and traumatize the tongue during suckling, enough to delay healing. Extraction of the natal or neonatal tooth, like in this case was recommended. Tooth extraction had resolved the ulceration too. Although reported by Rutt<sup>12</sup>, the possibility of pyogenic granuloma in the tooth extraction place, we did not observe this kind of alteration in our present case.

### Conclusions

Our male infant presented a single neonatal tooth in the mandibular central incisor region with hypoplastic enamel. The paediatricians' concern over the infant's failure to gain weight due to ulceration's interference with suckling dictated the need for rapid resolution of the lesion.

So extraction of the natal tooth was chosen over more conservative treatments. With subsequent patient follow-up, an occlusal radiograph revealed erupting mandibular central incisors. Hence it was possible to confirm that the neonatal tooth had been a supernumerary.

### Declaration of Interest

The authors report no conflict of interest and the article is not funded or supported by any research grant.

### References

1. Massler M, Savara BS. Natal and neonatal teeth. *J Pediatr* 1950; 36: 349-59.
2. Buchanan S, Jenkins CR: Riga-Fedes syndrome: natal or neonatal teeth associated with tongue ulceration: Case report. *Aust Dent J* 1997; 42: 225-27.
3. Zhu J, King D. Natal and neonatal teeth. *ASDC J Dent Child* 1995; 62(2):123-8.
4. Bodenhoff J, Gorlin RJ. Natal and neonatal teeth: folklore and fact. *Pediatrics* 1963; 32:1087-1093.
5. Chow MH. Natal and neonatal teeth. *ASDC J Dent Child* 1995; 62(2): 123-8.
6. Kates GA, Needleman HL, Holmes LB. Natal and neonatal teeth: a clinical study. *JADA* 1984; 109: 441-3.
7. Tsubone H, Onishi T, Hayashibara T, Sobue S, Ooshima T. Clinicopathological aspects of a residual tooth: a case report. *J Oral Pathol Med* 2002; 31(4): 239-41.

8. Elzay RP: Traumatic ulcerative granuloma with stromal eosinophilia (Riga-Fede's disease and traumatic eosinophilic granuloma). *Oral Surg Oral Med Oral Pathol* 1983; 55: 497-506.
9. Zaenglein AL, Chang MW, Meehan SA, Axelrod FB, Orlow SJ: Extensive Riga- Fede disease of the lip and tongue. *J Am Acad Dermatol* 2002; 47: 445-47.
10. Hedge R J. Sublingual traumatic ulceration due to neonatal teeth. *J Indian Soc Pedod Prev Dent* 2005; 23: 51-52.
11. Slayton R. Treatment alternatives for sublingual traumatic ulceration (Riga-Fede disease). *Pediatr Dent* 2000; 22: 413-14.
12. Ruth AA. Natal and neonatal teeth: Histologic investigation of two black females. *ASDC J Dent Child* 1982; 49: 300-3.
13. Ahmet T, Ferruh B, Gurcan A. Lingual traumatic ulceration (Riga-Fede disease). *Br J Oral Maxillofac Surg* 1982; 41: 201.
14. Rakocz M, Frand M, Brand N. Familial dysautonomia with Riga-Fede's disease: report of case. *ASDC J Dent Child* 1987; 54: 57-59.
15. Terzioglu A, Bingul F, Aslan G. Lingual traumatic ulceration (Riga-Fede disease). *J Oral Maxillofac Surg* 2002; 60: 478.
16. Jariwala D, Graham RM, Lewis T. Riga fede disease. *Br Dent J* 2008; 204: 171-72.