

GINGIVAL METASTASE AND INTRACEREBRAL HAEMORRHAGE RESULTING FROM UNSUSPECTED CHORIOCARCINOMA: A CASE REPORT

Mehmet Serhan Tasdemir¹, Ayfer Aktas^{2*}, Nebahat Tasdemir³, Yusuf Nergiz⁴

1. Research Assistant PhD, University of Dicle Medical Faculty, Department of Histology and Embryology, 21280Diyarbakir, Turkey.
2. Associate Professor. Dr. University of Dicle Medical Faculty, Department of Histology and Embryology, 21280Diyarbakir, Turkey.
3. Professor Dr.University of Dicle Medical Faculty Department of Neurology, 21280Diyarbakir, Turkey.
4. Professor Dr.University of Dicle Medical Faculty, Department of Histology and Embryology, 21280Diyarbakir, Turkey.

Abstract

Gestational choriocarcinoma is a highly malignant epithelial tumour arising from the trophoblasts of any type of gestational event, most often a hydatidiform mole. Choriocarcinoma is for all practical purposes limited to reproductive age women but rare examples of choriocarcinoma in postmenopausal women have been reported.

In case of a 24- years- old was a female patient with left hemiparalysis. Biopsy that obtained from lower gingival ulcer indicated the availability of choriocarcinoma metastasis. Before putting her in our intensive care unit she suddenly became unconscious. Focally haemorrhagic fragile gingival tissue (grossly, 1× 1× 0.5 cm) was processed. In the formaline fixed, paraffin embedded and hematoxylin and eosin(H&E) stained slides, beneath the stratified squamous epithelia, there was tumoral infiltration. Tumor was consisted of abnormal cytotrophoblasts and syncytiotrophoblasts cells and diffuse intercerebral haemorrhage.

In this report we presented a rare case of metastatic gingival choriocarcinoma and intracranial haemorrhage resulting from an unsuspected choriocarcinoma metastasis.

(*J Int Dent Med Res* 2010; 3: (2), pp. 79-81)

Keywords: Intracerebral haemorrhage, gestational choriocarcinoma, gingiva.

Received date: 17 November 2009

Accept date: 21 April 2010

Introduction

Gestational choriocarcinoma is a highly malignant epithelial tumour arising from the trophoblasts of any type of gestational event, most often a hydatidiform mole. Choriocarcinoma is for all practical purposes limited to reproductive age women but rare examples of choriocarcinoma in postmenopausal women have been reported¹.

Theoretically, choriocarcinoma may arise in the trophoblast of the primitive blastocyst during implantation, but most cases of choriocarcinoma appear to follow a recognizable

gestational event.

The signs and symptoms of choriocarcinomas are protean. Abnormal uterine bleeding is one of the most frequent symptoms of choriocarcinoma, but uterine lesions may be restricted to the myometrium and remain asymptomatic.

Not all patients have a demonstrable lesion in the uterus after an intrauterine gestation.

Many examples of metastatic choriocarcinoma without a primary uterine tumour have been described². It is highly likely that the neoplasm undergoes regression in the uterus. Sometimes, symptoms related to metastases are the first indication that a choriocarcinoma is present, and the lungs are the most frequent sites for metastasis^{2,3}.

Secondary involvement of the gingival metastasis by choriocarcinoma is uncommon. In this report we presented a rare case of metastatic gingival and intracranial haemorrhage resulting from unsuspected choriocarcinoma metastasis.

*Corresponding author:

Assist. Prof. Dr. Ayfer Aktas,
University of Dicle Medical Faculty,
Department of Histology and Embryology,
21280 Diyarbakir, Turkey.

E-mail: aaktas@dicle.edu.tr

CASE REPORT

We described a 24 years old female patient with left hemiparalysis. Biopsy that obtained from lower gingival ulcer indicated the availability of choriocarcinoma metastasis. Before putting her in our intensive care unit she suddenly became unconscious. She had 3 children and her last pregnancy was 3 months ago. In her neurological examination: We found left Babinski's sign positive and her whole deep tendon reflexes were brisk with left hemiparalysis. Her gynaecologic examination was normal. β -hCG: 10 000(≤ 3). We detected a haematoma at right parieto-occipital region.

It was 3.5 x5 cm size by CT scan (Figure 1). Abdominal ultrasonographic examination of uterus and bilateral ovaries were found to be normal. Dermatological consultation: Pyogenic granuloma of the mouth. Clinical diagnosis: Malign pyogenic parenchymal tumour.

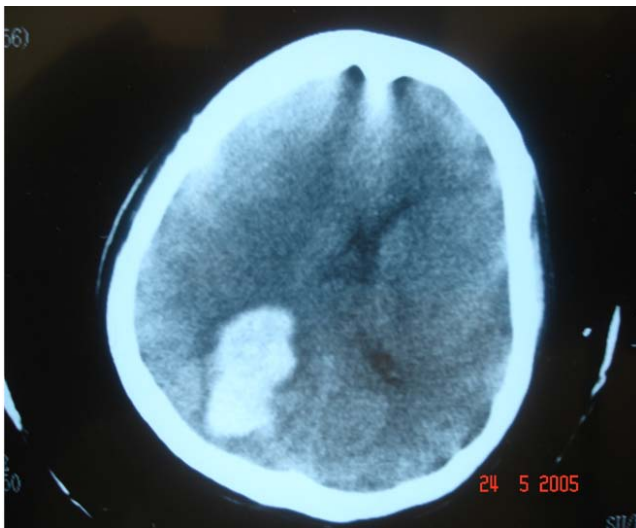


Figure 1. Patient CT-Scan.

Tissue pathologic findings: grossly, 1x 1x 0.5 focally haemorrhagic fragyl tissue processed, In the formaline fixed, paraffin embedded and H.E stained. Beneath stratified squamous epithelium, these were tumoral infiltration. Tumour was consisted of abnormal cytotrophoblasts and syncytiotrophoblasts cells (Figure 2).

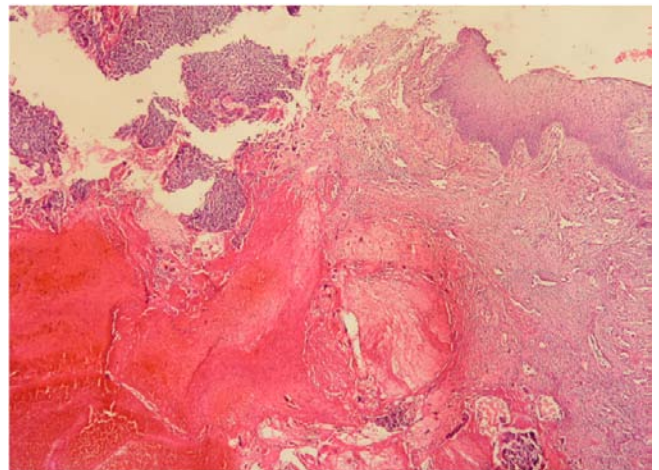


Figure 2. Biopsy tissue from gingiva.(H&E,X80).

Discussion

Hertig found an incidence of choriocarcinoma 1 in 160.000 normal gestations, 1 in 15.386 abortions, 1 in 5.333 ectopic pregnancies, and 1 in 40 molar pregnancies⁴. In that series, one-half of the cases of choriocarcinoma were preceded by hydatidiform mole, with 25% following abortion , 22.5 % following normal pregnancy , and 2.5% following ectopic pregnancy⁴. Other studies have generally confirmed these figures⁵.

Metastases to the gingiva are uncommon. They can be a diagnostic challenge clinically because of their rarity and tendency to mimic benign lesions. Sometimes, symptoms related to metastases are the first indication that a choriocarcinoma is present, and the lungs are the most frequent sites for metastasis⁶.

Large amounts of trophoblast showing atypic should be viewed suspiciously for choriocarcinoma. If the diagnosis is in doubt, a chest radiograph and careful monitoring of β -hCG levels should resolve the problem. Radioimmunoassay of beta human chorionic gonadotrophin (hCG) should be used to confirm the diagnosis.

Discriminating choriocarcinoma from other carcinomas either within the uterus or at other sites usually is not a problem. Occasionally a biopsy of choriocarcinoma may show few syncytiotrophoblastic cells, or the entire lesion is composed of mononucleate trophoblastic cells, a pattern that can mimic a poorly differentiated carcinoma⁶. We also found syncytiotrophoblastic cells in her gingival biopsy tissue.

Patients usually are in the reproductive

age group (19-62 years with an average of 30 years) and can present with either amenorrhea or abnormal uterine bleeding, often accompanied by uterine enlargement^{7,8} and frequently are thought to be pregnant.

When this differential diagnosis arises, the clinical history may reveal a previous molar pregnancy or another suspicious pregnancy event that can assist in the diagnosis. Serum hCG levels and immunohistochemical localization of hCG, hPL, and inhibin- α in syncytiotrophoblast can be useful. We found serum hCG level was over than 10 000. Choriocarcinoma has been described as a primary tumour arising in a number of different sites besides the uterus and gonads.

In women of reproductive age, however, pure choriocarcinoma that appears to be an extrauterine primary tumour probably represents gestational chorocarcinoma in which the index pregnancy is undetected⁹.

True primary choriocarcinoma at an unusual site may be derived from differentiation of an ordinary carcinoma. Our patient had her last pregnancy 3 months ago and normally delivered. Her last gynaecologic examination was completely normal.

Primary somatic tumours of the gastrointestinal tract, bladder, breast, lung, or endometrium rarely show choriocarcinomatous differentiation, and these show transitions from ordinary carcinoma to the trophoblastic component. Over the past four decades there has been a substantial improvement in survival of patients with choriocarcinoma^{3,9}.

Brain metastases are relatively uncommon and their incidence in patients with choriocarcinoma is 3-27%^{1,3,7,8}. However, the incidence of cerebral metastasis found at autopsy on patients with choriocarcinoma is significantly higher (66.7% of patients)¹⁰.

The prognosis for choriocarcinomas in the uterus is very good. Although these tumours have often spread throughout the body, chemotherapy results in a cure or remission in at least 80-90% of cases. Women who have had choriocarcinomas often go on to have normal pregnancies and deliveries but choriocarcinomas in other sites have a worse prognosis. These tumors are a worse prognosis. These tumours tend to spread quickly and don't always respond well to the chemotherapy. Although treatment can be effective, the outcome usually depends

on how widely the cancer is dispersed.

Generally, the prognosis is worse if the cancer can be found in the liver or brain, and the original tumour developed outside the gonads. Five year survival with testicular cancers can range from 92% for tumours that have spread only to the lungs to 48% to tumours that have spread to other internal organs^{1,2,4,5}.

Conclusions

In this report we presented a rare case of metastatic gingival choriocarcinoma and intracranial hemorrhage resulting from unsuspected choriocarcinoma metastasis.

Declaration of Interest

The authors report no conflict of interest and the article is not funded or supported by any research grant.

References

1. Dougherty CM, Cunninham C, Mickal A. Choriocarcinoma with metastasis in a postmenopausal woman. *Am J Obstet Gynecol.* 1978; 132:700-701.
2. Berkowitz RS, Goldstein DP. Chorionic tumours. *N. Eng. J.Med.* 1996; 335:1740-8.
3. Bakri Y, Berkowitz RS, Goldstein DP et al. Brain metastases of gestational trophoblastic tumour. *Reprod Med.* 1994; 39:179-84.
4. Hertig AT. Tumours of the female sex organs. Part 1. Hydatidiform mole and choriocarcinoma, *Atlas of tumour pathology*, sec 9, fasc 33. Armed Forces Institute of pathology; 1956: Washington, DC.
5. Mazur MT, Lurain JR, Brewer JI. Fatal gestational choriocarcinoma. Clinicopathologic study of patients treated at a trophoblastic disease center. *Cancer (Phila)* 1982; 50:1833-1846.
6. Wurzel J, Brooks JJ. Primary gastric choriocarcinoma: Immunohistochemistry, postmortem documentation and hormonal effects in a postmenopausal female. *Cancer (Phila)* 1981; 48:2765-2761.
7. Komeichi T, Igarashi K, Takigami M et al, A case of metastatic choriocarcinoma associated with cerebral thrombosis and aneurysm formation. *No Shinkel Geka.* 1996; 24: 463-7.
8. Kobayashi T, Kida Y, Yoshida, Shibuya N, Kageyama N, Brain metastases of choriocarcinoma. *Surg. Neurol.* 1982; 17:395-403.
9. Lurain JR, Brewer JI, Torok EE, Halpern B. Gestational trophoblastic disease center. *Obstet Gynecology.* 1982; 60:354-360.
10. Young RH, Scully RE. Placental site trophoblastic tumour: current status. *Clin Obstet Gynecol.* 1984; 27:248-258.