

ISOLATED ARCUS ZYGOMA FRACTURES (9 CASES REPORT)*

Rezzan GUNER¹, U. Nezhil YILMAZ², Ferhan YAMAN^{3**}, Cigdem CETIN⁴

1. Assoc. Prof. Dr. Department of Oral and Maxillofacial Surgery, Faculty of Dentistry, Dicle University, Diyarbakir / TURKEY
2. PhD. DDS. Department of Oral and Maxillofacial Surgery, Faculty of Dentistry, Dicle University, Diyarbakir / TURKEY
3. Assist. Prof. Dr. Department of Oral and Maxillofacial Surgery, Faculty of Dentistry, Dicle University, Diyarbakir / TURKEY
4. PhD. DDS. Oral and Maxillofacial Surgery, Private Practice, Diyarbakir / TURKEY

Abstract

Arcus zygomaticus is one of the weakest parts in the facial bone that can be easily affected and fractured by traumas. The typical shape of the fracture is midline depression and separation from zygomatic and temporal bone. Sometimes by the whole arcus fracture can be occur. The arcus fractures can be seen the component of the zygomatic complex fracture and also may happen as an isolated damage even if occurs minimal trauma to the lateral face parts.

Most of the cases, as a result of fracture the arcus zygomaticus force the coronoid process and result in limited mouth opening and trismus. If these kinds of symptom will be seen the treatment is necessary. Conventionally, Keen, Gilles, Hook traction and open reduction treatment method and also new treatment modality can be use. For satisfied functional and aesthetically clinical results, meticulous approach is necessary.

Our study's aim is to present 9 isolated arcus zygoma fracture cases a point of clinical findings, treatment methods, and result. In addition, classification and treatment methods will be discussed in the light of literature reviews.

In our study group we have 1 female and 8 male patient. Etiological factors are violence, falling, and sport accidents respectively 6 cases, 1 and 2 cases. Main compliment was limiting of the mouth opening in all patients. Keen's method (Intraoral approach) and hook tractions method were preferred as a choice of treatment modalities. Only for one case, which is delayed arcus zygomaticus fracture, temporal approach was performed.

After the operation along to 5-7 day, we performed intermaxiller fixation all the patients. After operation maximal mouth opening and functional rehabilitation was obtained.

(*Journal of International Dental and Medical Research 2009; 2: (3), pp. 81-85*)

Key words: Arcus Zygoma, Midface fracture.

Received date: 20. September 2009

Accept date: 09 November 2009

Introduction

The zygomatic arch, contradistinction to the zygoma, is a relatively weak part of the facial bone. Fracture of the zygomatic arch and does occur

zygomatic and temporal suture, as well as along the full length of the arch (1). Usually those M shaped fractures mentioned in text books and having 3 fractures line². Fracture of the zygomatic arch often occurs as a part of tripod fracture of the zygoma and of the Le Fort III- type maxillary fractures (2).

Isolated zygomatic arch fractures compromise about 10 % of all zygoma fractures (3).

A displaced zygomatic arch fractures can be clinically diagnosed by observation of in the region by pain, prevention coronoid from moving forward as in jaw opening and by trismus caused by trauma to the temporalis muscle¹. Indeed , trismus has been reported to occur in approximately half of isolated zygomatic arch fracture. The zygomatic arch fractures should treat to restore function and aesthetic (1).

Facial fractures have recently been classified in fine detail according to computed

**Corresponding author:

Assist. Prof. Dr. Ferhan YAMAN
Dicle University, Faculty Of Dentistry,
Department of Maxillofacial Surgery,
21280 Diyarbakir, TURKEY.

Tel: +90 412 248 81 01-3496

Fax: +90 412 248 81 00

E-mail: dtferhan@hotmail.com

*This paper was presented in Oral and Maxillofacial Surgery Society 1st International Congress 2007, Antalya / TURKEY

tomographic findings. Nevertheless, there exists no classification of the zygomatic arch fracture, which has a physiognomically important place, to provide guidance for treatment (2,3).

Because of these reasons new classification systems are improved: The classification according to dislocation of fracture is summarized a below (3).

1 Type I : No displacement

Type II : Displacement with bone contact at all fracture lines

Type III : Displacement without bone contact at 1 fracture line

Type IV : Displacement without bone contact at 2 fracture lines

Type V : Comminution or displacement without bone contact at 3 or more fracture lines

Numerous techniques have been reported for the reduction of zygomatic arch fractures, such as closed reduction by the Gilles method or an intraoral approach percutaneous approach (hook traction) and open reduction (4).

The patient should be given a soft diet for 8-10 days postoperatively to limit function of the masseter muscle which pulls downward to zygoma(4).

Fixation by the intraosseous wiring rarely is required. The incision for open reduction lies above the zygomatic arch; care must be taken avoid the branches of the facial nerve .When exposed the soft tissue not be separated excessively lest the bone fragment loose their blood supply(4).

Case Reports

9 patient, were included in the study. One of them was female and the others were male. Mean age of all patient was 33 year old (Table-1).

The most common causes of fractures were violence and the fallows were sport accident and falls. Limited mouth opening was observed as symptom all patients. As a result of fracture depression of lateral depression was detected in all patient. (Fig- 1,2).

The others symptom which were associated with fractures were pain and edema.

On the radiological evaluation of all patients we used axial CT for 5 patients and conventional radiography (submento-vertical graph) for 4 patients. Except for patients with multi-fragmented arcus zygoma, "M" shaped depression was observed in all patients (Fig-3,5).

3 patients were treated by hook traction (Fig- 3,4), 5 patients were treated by Keen modality (intraoral approach) (Fig-5,6) and also one patient who was applied to our clinic on the 12th day of fracture was treated by Gillies's method (Fig- 7,8).



Figure 1. Lateral depression view as a preoperative.



Figure 2. Postoperative view of patient.

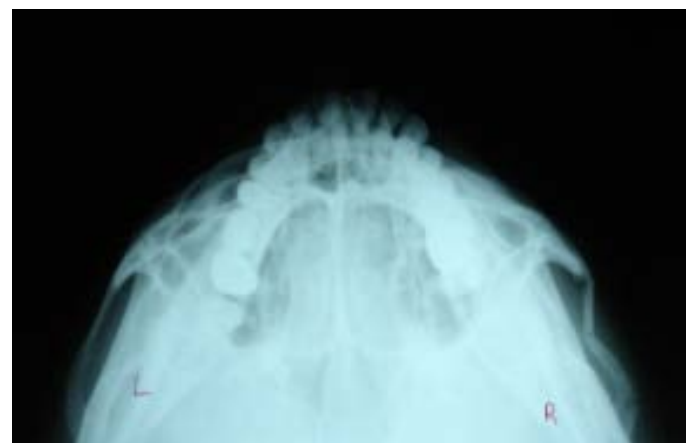


Figure 3. Multi-fragmented arcus zygoma.

To prevent to relapse intermaxillary fixation (IMF) was performed to all patients for 5-7 days in the post operation period.

Finally we detected that on clinical observations normal function and esthetic results had been obtained far all patients.

Complete anatomic reduction was ensured on treated with Keen and Gillies's approach. (Fig- 5,6,7,8)

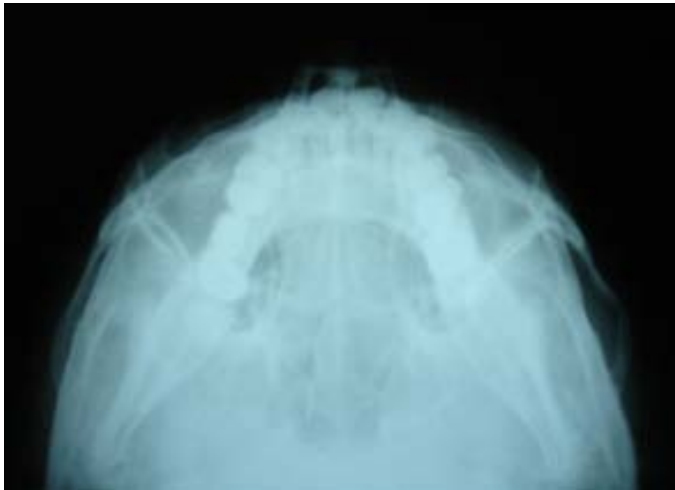

Figure 4. Overcorrection was seen on 2 of 3 patients treated with hook traction modality(Fig-3, 4).

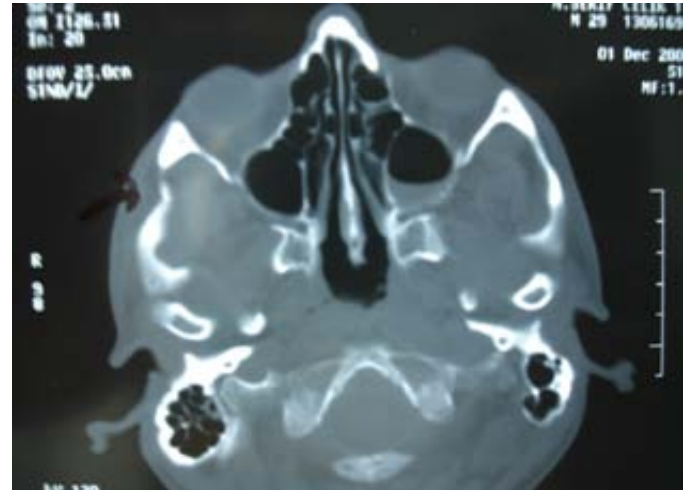


Figure 7.

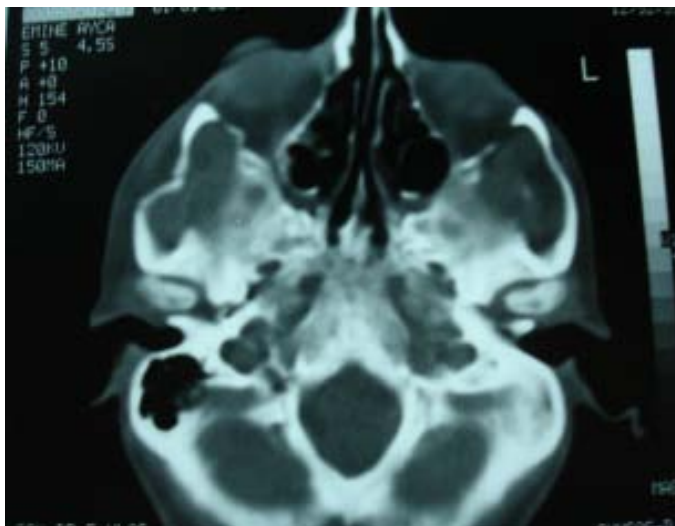


Figure 5. Complete anatomic reduction was ensured on treated with Keen and Gillies's approach (Fig. 5-8).

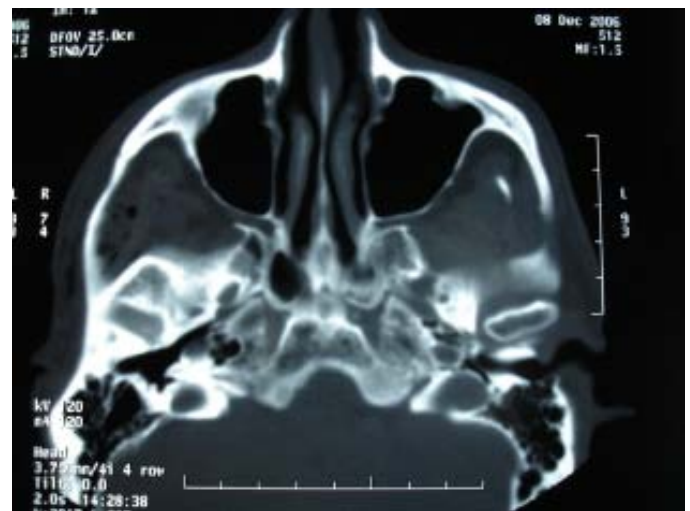


Figure 8.

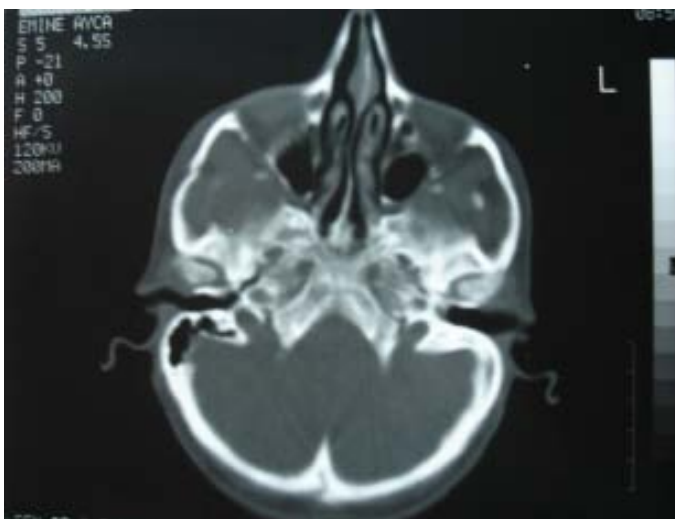

Figure 6.

Patient No	Age	Sex	Etiology	Main Complaint	Radiological Assessment	Treatment Modalities
1	37	F	Violence	Depression of lateral mid-face, limiting mouth opening	SMV* Radiograph	Keen Approach
2	37	M	Violence	Depression of lateral mid-face, limiting mouth opening	SMV Radiograph	Hook Traction Modality
3	30	M	Sport Accident	Depression of lateral mid-face, limiting mouth opening	SMV Radiograph	Hook Traction Modality
4	23	M	Sport Accident	Depression of lateral mid-face, limiting mouth opening and pain	Axial CT	Keen Approach
5	32	M	Falling	Depression of lateral mid-face, limiting mouth opening and pain	Axial CT	Hook Traction Modality
6	39	M	Violence	Depression of lateral mid-face, limiting mouth opening and pain	Axial CT	Keen Approach
7	38	M	Violence	Trismus, minimal depression, swelling	SMV Radiography	Keen Approach
8	30	M	Violence	Depression of lateral mid-face, limiting mouth opening	Axial CT	Gilles Approach
9	28	M	Violence	Depression of lateral mid-face, limiting mouth opening	Axial CT	Keen Approach

Table 1. Demographic and etiologic distributions,

symptoms, diagnosis and treatment modalities on our patients (* Submentovertical).

Discussion

Arcus zygoma has a thin structure and also is effected easily by traumas. Therefore among facial fractures zygomatic arch fractures rather frequently (2).

Some of the zygomatic arch fractures may be in the form of component of the mid-face fracture(2). The others in the form isolated fractures in the arch only results from localized forced landing on the face laterally and having relatively less impact³. Isolated zygomatic arch fractures comprise about 10% of all zygomatic fractures(2). When not treated properly, the arch fractures may lead not only to various cosmetic deformities related to skeletal structure of the face but also to functional disorders resulting from the pressure on the coronoid process(3).

There are a lot of studies which related to demographic distribution of isolated arcus zygoma fractures in the literature. In these studies it is reported that fractures were more common in males than females (3). Also in our study almost whole of fractures were occur in males. Although in same investigation, falls were mostly observed etiological factor, in our study determined that violence is the most occur etiological factor (3). The left side was more frequently involved than the right side, but the reason for this is unknown (3).

Classification of the fractures greatly facilitates the surgeon's choice of the treatment and also classification facilitates that it constitutes a common terminology among surgeons and enables communication, too (3).

Facial fractures have recently been classified in fine detail according to computed tomographic findings (3). However, recently there has been no classification of the generally encountered isolated zygomatic arch fractures to provide guidance for treatment (2, 3). To make detailed classification of zygomatic fractures in various shapes, which does not exist in the literature, and to form an algorithm for treatment was attracted attention (3). Yamomato et al (3). therefore classified the fractures into 5 types according to the degree of displacement and loss of bone contact (3). This classification is useful to determine the treatment method and need for fixation. Yamomato et al (3) reported that in type I fractures with no displacement, reduction is not necessary. In type III and IV fractures with displacement without bone contact at 1 or 2 fractured sites, good reduction can be obtained,

although there may be less stability after reduction, however, in type V fractures, open reduction may be needed to reduce comminuted bone fragments together with fixation or stabilization to maintain their alignment (3). Honig and Merten (5). were classified the fractures which called by their names, on the below:

(HM) class I is defined as an isolated tripod fracture, HM class II as an isolated stick fracture of the arch, and HM class III is a combined fracture of the malar bone and the zygomatic arch. Researchers determined that open reduction is mandatory in class III fractures (HM) (5).

The reduction status was evaluated by axial x- ray film and classified into 4 types: excellent, good, fair, and poor . Excellent reduction was achieved mostly in type II fractures (5).

Fracture of the zygomatic arch is usually treated using blind methods. As the fracture lines cannot be visualized directly in closed reduction, digital exploration and crepitus noise or conventional radiographic imaging are used clinically as a guide to reposition the fragments. Successful closed reductions are often difficult (6).

Postoperative radiographs are often the only way to assess the adequacy of the reduction. Intraoperative assessment of the zygomatic arch is very important in achieving adequate repositioning (6). The correct alignment of the zygomatic arch indicates the proper position of the zygomatic bone and ensures adequate prominence of the lateral midfacial aspect⁶. Gulicher et al studied on estimate the value of ultrasonography as an intraoperative repositioning control in the treatment of the zygoma fractures and they concluded that ultrasonography rapid and easy perform, and is recommended, and is intraoperative visualizing tool (6).

And also in the literature it was reported that the use of ultrasonography, portable fluoroscopy and C-arm may have the advantage of intraoperative evaluation of the reduction status (6, 7).

The treatment for isolated zygomatic arch fractures depends on the degree of displacement (1). Usually, fractures with significant displacement need reduction (1). There are several methods to reduce zygomatic arch fractures such as intraoral approach (Keen modality), hook traction (percutaneous approach), temporal approach by Gillies's and open reduction (4). Some investigator reported that Gillies's approach has been most frequently used modality (1, 3). These researches are be opinion that the Gillies's method offers several advantages, such as easy execution under local anesthesia, little possibility of facial nerve damage or direct trauma to the globe, and no visible

scars within the hairline (3). Yamomato et al reported that in your department, reduction by the Gillies's method was the first choice, because the procedure can be performed consistently and the results are satisfactory (3). In the same way we also treated delayed fracture successfully.

Other methods of reduction via lateral eyebrow incision and by a transcutaneously inserted hook have also been reported (5).

Recently, intraoral approaches have become the preferred choice due to the advantage of leaving no visible scars. Of these 9 patients, 5 patients were treated by Keen method and complete anatomic reduction was obtained.

Besides these methods hook traction method is frequently used (1, 4) and we also preferred hook traction for 3 of 9 patient. Yamomato et al (3) reported that with laceration of the buccal skin below the affected zygomatic arch, hook reduction was also chosen (3). There were no laceration for our patient. In 1 case 2-3 mm incision was made on arcus zygoma. For the others percutaneous approach was performed. In 2 of 3 cases that treated with hook traction method overcorrection was occurred.

Some researches reported that intermaxillary fixation (IMF) is not necessary after zygomatic arch reduction. However in communicated fractures other researches reported that open reduction and fixation may be necessary (4). We preferred, IMF to prevent possible relapse for 5-7 days. We are in opinion of that IMF for short period doesn't make discomfort and useful to prevent relapse.

Recently endoscopic reduction and fixation method has been used for zygomatic fractures (7).

The use of an endoscope may be helpful to perform reduction and fixation inside the optical cavity via a small incision. And also endoscope-assisted zygomatic arch realignment and fixation allow anatomic repair without sustaining the drawbacks of extensive access incisions (7, 8).

Conclusions

Another treatment modality towel clip reduction which created by Carter et al (9). Although the towel clip reduction of the depressed zygomatic arch fracture may be another simple technique in the armamentarium of surgical management of facial fractures, the unpredictability, limitations, and operator technique sensitivity can have an impact on the success of the operation where the procedure is applied (10). Manzon et al(10) reported that this technique is limited because it may only be used to reduce minimally displaced fractures.

Additionally desired results are not guaranteed for this technique (10).

Besides this modality tchrakeal tube and foley catheter is used for treatment of arcus zygoma fracture in literature (11, 12).

References

1. Fonseca, R; J, Oral and Maxillofacial Surgery, ,Chapter 6, Volume 3, 1st edition, p. 198-199. W.B Saunders Company 2000.
2. Ozyazgan I, Günay GK, Eskitaşçioğlu T, Özköse M, Çoruh A; A new proposal of classification zygomatic arch fractures. J Oral and Maxillofac Surg. 2007;65: 462-469.
3. Yamamoto K., Murakami K., Sugiyura T., Fujimoto M., Inoue M., Kawakami M. Ohgi K., Kirita T; Isolated Zygomatic Arch Fractures. J Oral Maksillofac Surg 2007.
4. Kruger E; Oral and Maxillofacial Traumatology, Schilli W, Chapter 10, Volume 2, p. 172- 173. Quintessence Publishing Co., Inc., Chicago, Illinois 1986.
5. Honig JF, Merten HA. Classification system and treatment of zygomatic arch in the clinical setting. J Craniomaxillofac. Surg. 2004;15: 986-9.
6. Gulicher D, Krimmel M, Reinert S; The role of intraoperative ultrasonography in zygomatic complex fracture repair. Int. J Oral and Maxillofac. Surg. 2006;35: 224-230.
7. Badjate SJ, Cariappa KM. C-Arm for accurate reduction of zygomatic arch-a case report. Br Dent J 2005;10: 275-7.
8. M. Czerwinski and C. Lee, Traumatic arch injury: Indication and an endoscopic method of repair, Facial Plast Surg. 2004;20:231-238.
9. Carter TG, Bagheri S, Dierks EJ. Towel clip reduction of depressed zygomatic arch fracture. J Oral Maxillofac Surg. 2005;63:1244-54.
10. Manzon S, Choudhary N, Philbert R, Towel clip reduction of the depressed zygomatic arch fracture. J Oral Maxillofac Surg. 2006;64:1323-1326.
11. El-Haddy AM: The use of Foley catheter in isolated zygomatic arch fractures. Plast. Reconstr. Surg. 2005;116: 853-856.
12. Holmes S, Bridle C. Use of tracheal tube in isolated fractures of the zygomatic arch. Plast Reconstr. Surg. 2006;117:315.