

THE HISTOLOGICAL STRUCTURE OF FILIFORM AND FUNGIFORM PAPILLAE OF THE PUPPY RATS WHICH BORN FROM THE RATS GIVEN EGF AFTER SIALOADENECTOMY

Ayfer AKTAS^{1*}, Yusuf NERGIZ²

1. Assist. Prof. Dr. Department of Histology and Embryology, Medical School, Dicle University, 21280, Diyarbakir / TURKEY
2. Prof. Dr. Department of Histology and Embryology, Medical School, Dicle University, 21280, Diyarbakir / TURKEY

Abstract

After the complete removal of submandibular gland surgically, morphological alterations, and the effects of EGF given orally on these alterations were investigated. In the study, 30 adult female Sprague-Dawley rats were used, which were divided equally into three groups: Control group; sialoadenectomy group; sialoadenectomy + epidermal growth factor group.

Following a three week period of recovery, the rats were mated. On days 16-19th of pregnancy, a total of 5 microgram EGF was given to the animals in sialoadenectomy + epidermal growth factor group with orogastric tube as 1.25µg daily to each animal. The fetuses born following pregnancy were kept to grow up until the 28th day. The pupy rat of 28 days in all groups were taken, and then they were sacrificed. Tongues of all puppy rats were fixed in a 10 % neutral buffered formalin solution. The paraffin sections obtained through routine histological methods were stained with Hematoxylen-Eosine, Methylen blue- Basic Fuchsin, Hemotoxylen-Van Giesson, and were examined under light microscope. A significant increase in the keratinization; an elongation and bifurcation at the ends of the filiform papillae of the sialoadenectomy group rats were observed.

The fungiform papilla and the taste buds were noticed to be larger than that of the control group, and a decrease was detected in the cells population that constitutes the taste buds. Bifurcation and hyperkeratosis in the filiform papillae of the sialoadenectomy + epidermal growth factor group rats. The morphological appearance of fungiform papillae and taste buds was observed to be similar to that of fungiform papillae of the control group.

(Journal of International Dental and Medical Research 2009; 2: (3), pp. 100-104)

Keywords: Rat, EGF, Sialoadenectomy, Lingual Papillae.

Received date: 05 October 2009

Accept date: 22 November 2009

Introduction

The tongue papillae were first identified by Malpighi in 1664 (1). The Taste buds found in humans and mammals are the receptors for the perception of taste and in rats there are three types of taste bud-bearing tongue papillae, which are fungiform papilla, circumvallate papilla, and foliate papilla (2). While the fungiform papillae are on the anterior portion of the tongue and the foliate papillae on the rear-lateral edges, the circumvallate papilla, which is singular, is placed

more posteriorly on the midline of the tongue (3).

The circumvallate papilla which is located in the midline of the dorsum lingua is circumscribed from the rear and lateral sides with a horseshoe-shaped, incompletely enclosed trench, that is left and right trenches do not merge in the anterior part (4).

Farbman and Mbeine (5), observed the formation of a mushroom shaped fungiform papilla with mechanical and gustatory functions in the tongues of 15-day fetuses. It was announced that every single fungiform papilla has a single taste bud on it in a ratio of 99% in rats as in hamsters. Miller and Preslar (6) divided the tongue into two; and they declared that more than 50% of the papilla was located in the edges of the tongue. While the average papilla density was 3.4/mm² in the first 4 mm of the tongue, it decreased to 1.3/mm² in the 4-17 mm range and no papilla was present in the dorsal line. There were more papillae in the right half of the tongue with respect to the left one.

*Corresponding author:

Dr. Ayfer AKTAS
Department of Histology and Embryology
Medical School, Dicle University
21280, Diyarbakir / TURKEY

Phone: +90 4122488001-4123

Fax: +90 4122488435

E-mail: aaktas@dicle.edu.tr, fuldic@gmail.com

The filiform papillae of rats have a mechanical effect and their histological structure was demonstrated by Farbman (4). However, there are limited amount of work dealing with the different aspects of filiform papillae. The filiform papillae start to develop in the last days of embryonic life. The length and the base width of the papillae show an increase with age.

A soft keratin layer on the front and lateral faces and a hard keratin layer on the rear faces of filiform papillae can be distinguished. Filiform papillae have a pointed end tended backwards and the shape of a cone getting thinner going up (6, 7).

Material and method

1. Animals

In this study 30 adult female Sprague-Dawley rats weighing about 250-300 g and provided from the Practice and Research Center of Medical Sciences in Dicle University were used.

The female rats were divided into three groups in equal numbers (n=10) as control(C), sialoadenectomy (SX), and sialadenectomy + Epidermal Growth Factor (EGF), respectively.

2. Surgical Procedures

Control Group (C): Female rats of this group were allowed to mate without any operation. The first day of the pregnancy was determined by the microscopic examination of vaginal smear. On the 28th day following their birth, tongues of all puppy rats were fixed in a 10% neutral buffered formalin solution.

Sialadenectomy (SX): Female Sprague-Dawley rats were put under general anesthesia by intramuscular administration of Ketamine + Xylazine. A transversal incision was performed at the neck region and the submandibular glands were totally extracted (8). For three weeks following the operation it was waited for the EGF level to drop. Then the test animals were mated, and the first day of the pregnancy was determined through the microscopic examination of vaginal smears. On the 28th day following their birth, tongues of puppy rats were put into a 10% neutral buffered formalin solution for the histological examination.

Sialadenectomy + Epidermal Growth Factor (SX+EGF): As in Group 2, the submandibular glands of female rats were removed by a sialadenectomy operation. The

rats of this group were let to mate after three weeks following the operation and the starting day of their pregnancy were determined again by microscopic examination of vaginal smears. Along the four days between 16th and 19th days of pregnancy, a 1.25 µg of EGF (Human Recombinant EGF, sigma) per subject was administered daily to pregnant rats by orogastric probe, making a sum of 5 µg per subject in total (8). On the 28th day following their birth, tongues of puppy rats were fixed in a 10% neutral buffered formalin solution.

3. Histological Method

On the 28th day following the birth, tongues of puppy rats of all three groups were dissected and cut into two from the line determining the anterior 2/3 portion and the posterior 1/3 portion. Then the samples were separately put into 10% neutral buffered formalin solutions. Sections with thicknesses of 4-6 µm were taken transversally and coronally from the paraffin blocks, which were obtained by routine paraffin treatment, with the aid of a sliding microtome. After passed through an ethanol series and xylol, the sections were stained with Haematoxylin-Eosin (HE), Haematoxylin-Van Giesson, and Methylene Blue + Basic Fuchsin, and then examined under a light microscope, and microphotographs were taken.

Results

The findings of tongue samples are summarized as follows:

1. Control Group

No pathology could be showed on the panoramic views of fungiform and filiform papillae (Fig. 1).

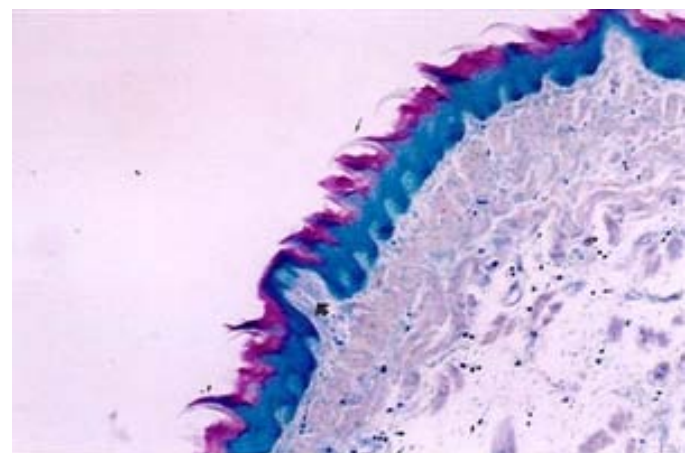


Figure 1. Control Group: The panoramic view of the filiform (thin arrow) and fungiform (thick arrow)

papillae on the dorsum lingua. (Methylene blue-Basic fuchsin, original magnification X 40)

2. Sialoadenectomy Group (SX)

A significant increase in the keratinization; longitudinal elongation of apical spines in several fungiform papillae in SX animals had apical spines of filiform papillae of the SX group rats were observed (Fig. 2a).

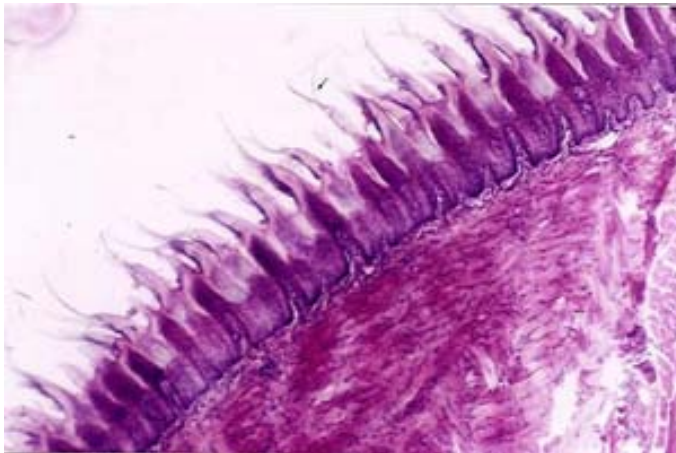


Figure 2a. SX group: Note the apical spines at the tips of filiform papillae (thin arrow) (H-E, original magnification X 40).

The fungiform papilla and the taste buds were noticed to be larger than that of the control group, and a decrease was detected in the cells population that constitutes the taste buds (Fig. 2b).

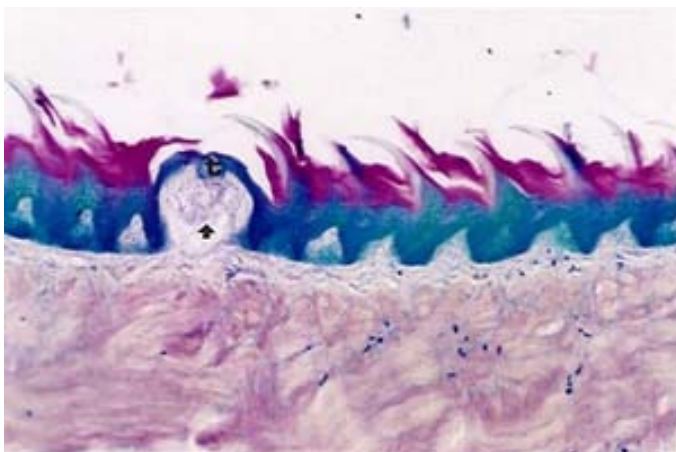


Fig. 2b: SX group: The hypertrophied fungiform papillae (thick arrow) and taste buds (t) in the apical epithelium. (Methylene Blue-Basic fuchsin, original magnification X 80)

3. Sialoadenectomy + Epidermal Growth Factor Group (SX+EGF)

Bifurcation and hyperkeratosis in the filiform papillae of the SX+EGF group rats (Fig. 3a).

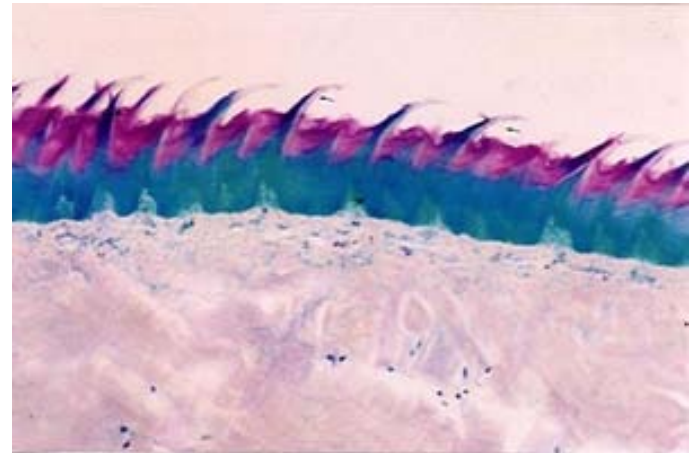


Figure 3a. SX+EGF group: The panoramic view of the filiform papillae (thin arrow) (Methylene blue-Basic fuchsin, Original magnification X 40).

The morphological appearance of fungiform papillae and taste buds was observed to be similar to that of fungiform papillae of the control group (Fig. 3b).

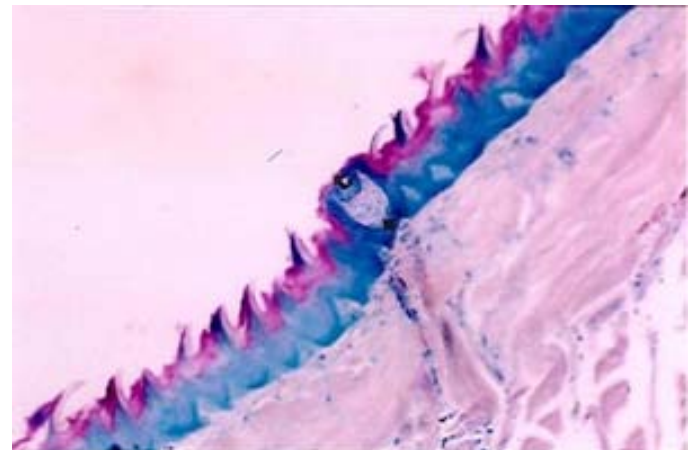


Figure 3b. SX+EGF group: Fungiform papilla (thick arrow) and taste bud (t) with normal appearances (Methylene blue-Basic fuchsin, Original magnification X 40).

Discussion

Shinzaburo and co-workers reported that the EGF concentration in the saliva of the mice and rats who had undergone sialoadenectomy was considerably diminished and because of this the recovery period of tongue wounds was elongated. It is known that the orally administered EGF afterwards, which does not increase the EGF level of portal and peripheral blood, enhances the healing process of tongue scars. Besides it was reported to cause mouth dryness in mice, as the amount of saliva in the mouth was decreased by the extraction of main

saliva source, i.e., submandibular gland. In mice, the inadequacy of EGF is the major cause of retardation observed in the recovery of wounds. It was discovered that the recovery rate of wounds reached usual levels when exogenous EGF was introduced. As quite well-known, the tongues of mice are covered with a stratified squamous epithelium; and since the EGF found in saliva cannot be absorbed from the lingual epithelial under normal circumstances, it is reported not to affect the basal epithelial cells. However, if the lingual epithelial is impaired due to certain chemical or mechanical agents, the EGF in the saliva can easily access the basal epithelial cells and contributes to the healing of wound. There was, however, a noticeable increase in keratinization of the lingual epithelium and increased infiltration of inflammatory cells within the mucosa SX groups.

The healing process of wounds in mice with sialoadenectomy was reported to exhibit a two-day lag with respect to normal healthy mice (9).

In our study, while the fungiform papillae of the control group exhibit a natural appearance, an elongation and bifurcation at the tips was witnessed in those of the SX group, together with a significant increase in the keratinization (Fig 2a-b). Epithelium and thinning in fungiformis papilla atrophy of taste buds. Increase in the surface epithelium spines and covering a large portion of the papilla. However bifurcation and increase in the keratinization could not be detected in the fungiform papillae of the SX+EGF rats thanks to orally administered EGF (Fig 3a).

The morphology of the fungiform papillae undergoes a change and the number of taste buds is declined in the rats treatment to sialadenectomy, which makes itself clear in the supplementation of EGF as feedback. The healthy development of taste buds in the fungiform papilla is the proof of the important role that EGF plays. The exogenous administration of EGF to the rats subjected to sialadenectomy causes an increase in the volumes of fungiform papillae. SX group when compared with the effects depending on the taste buds EGF in the epithelial layer and the thickness of the prominent observed.

Although some researchers suggest not only a parallel between the distribution of fungiform

papillae located in the anterior part of the tongue and their taste buds but also the presence of a taste bud in the apical of each papilla, there are some other researchers claiming that not all the fungiform papillae have a taste bud on them. The results obtained from our study concerning to fungiform papillae contradicts with the works of Beidler (13).

The tongue papillae of the rats are arranged both from the anterior to posterior and also to the middle in series in the tongue. Mistretta and et al pointed that the arrangement of the fungiform papillae were in series of longitudinally and diagonally (medial-lateral) in the tongues of rat fetuses in their study (10). Farban has indicated that the distribution of the fungiform papillae of the rat fetuses were similar with the adult rat papillae (11).

Therewithal, Vich and et al also reported that the arrangement of the papillae on the surface of the tongue were parallel with the branches of the lingual nerve (12).

Cano and co-workers investigated the role of sialoadenectomy in the maturation and survival of taste buds and they discovered that it affected the development of specific taste bud cell types. These observations lead the researchers to think that some other factors also in the saliva must have been responsible for the sustenance of the natural taste function and morphology, but these factors could not be detected yet (14).

After the experimental work performed on the taste buds of the rat fungiform papillae, Morris-Wiman et al. found that in the rats subjected to sialoadenectomy, the taste buds were atrophied and they were composed of only a few cells. Besides, their surface areas were rather diminished with respect to the sham group. When the EGF was administered orally afterwards, an improvement on the taste buds of the fungiform papillae was noticed; in fact they acquired an appearance identical to that of the sham group. In our study, the average diameters of the taste buds of control group and SX group fungiform papillae were measured as 122 μm and 88 μm , respectively. There was a decrease in the number of cells that make up the taste buds.

The sole reason for the fungiform papillae and their taste buds being hypertrophied is thought to be the extensive elimination of EGF source by the total extirpation of submandibular glands by sialadenectomy. In the tongue of sialadenectomized rats, fungiform papillae often had spines reminiscent of the apical spines of filiform papillae. EGF supplementation restored epithelium and papillae. Our findings concerning the taste buds of the fungiform papillae are consistent with the results of the studies carried out by Morris-Wiman and co-workers (15).

Conclusions

The structural changes observed in the fungiform and filiform papillae due to sialoadenectomy display a significant recovery as a result of the orally administered EGF.

References

1. Bradley R.M, Stern IB The development of the human taste bud during the foetal period. *J Acat* 1980;130(1):25-32.
2. Fish HS, Malone DD, Richter CP The anatomy of the tongue of the domestic Norway rat. I. The skin of the tongue, the various papillae, their number and distribution. *Anat Rec* 1994; 89: 429-440.
3. Iwasaki S, Yoshizawa H, Kawahara I. Study by Electron Microscopy of the morphogenesis of three types of lingual papilla in the rat. *Anat Rec* 1997 ;247: 528-541.
4. Farbman AI The dual pattern of keratinization in filiform papillae of rat tongue. *J Anat* 1970; 106(2) :232-242.
5. Farbman A., Mbiene JP Early development and innervation of taste bud-bearing papillae on the rat tongue. *The J. Comparative Neurol* 1991;304:172-186.
6. Miller IJ, Preslar AJ Spatial distribution of rat fungiform papillae. *Anat Rec* 1974;181:679-684.
7. Reynolds G *Handbook of Histological Techniques*, 2nd edition, Department of Histopathology, London 1990; 5-36.
8. Whitehead MC, Kachele DL Distrubution of taste and general sensory nerve endings in fungiform papilla of the hamster *J Comp Neurol* 1994; 340:515-530.
9. Noguchi S, Ohba Y, Oka T Effect of salivary epidermal growth factor on wound healing of tongue in mice. *Am J Physiol* 1991; 260: E620- E625.
10. Misteratta C. M Topographical and histological study of the developing rat tongue, palate and taste buds. *Third Symposium on Oral Sensation and Perception: The mouth of the infant*, J. F. Bosman, ed. Thomas, Spring field 1972; 163-187.
11. Farbman AI Electron microscope study of developing taste bud in rat fungiform papilla. *Dev Biol* 1965; 27(2) :263-272.
12. Vij SR Development of the nerve supply to the human tongue. *Acta Anat* 1972; 81: 466-477.
13. Beidler LM, Smallman RL Renewal of cells within taste buds. *The J Cell Biol* 1965; 27: 263-272.
14. Cano J, Roza C, Rodriguez EL Effects of selective removal of the salivary glands on taste bud cells in the vallate papilla of the rat. *Experientia* 1978; 34 :1290-1291.
15. Morris- Wiman J, Sego R, Brinkley L, Dolce C The Effects of sialoadenectomy and exogenous EGF on taste bud morphology and maintenance. *Chem. Senses* 2000; 25: 9-19.