

Nonsurgical Treatment of a Case With Skeletal Class III Malocclusion and Total Open – Bite: A Case Report

Nihal HAMAMCI^{1*}, Emin Caner TUMEN², Güvenc BASARAN³, Engin AGACKIRAN³

¹ Assistant Professor DDS PhD Department of Orthodontics, Dicle University, DİYARBAKIR, TURKEY.

² Assistant Professor DDS PhD Department of Pedodontics, Dicle University, DİYARBAKIR, TURKEY.

³ Research Assistan MSc Department of Pedodontics, Dicle University, DİYARBAKIR, TURKEY.

Abstract

This case report presents an adult skeletal Class III and open-bite malocclusion case treated without surgical intervention using the fixed edgewise technique, an RME appliance and box elastics.

The patient was an 18-year-old female who had completed her growth and development. She had a total open-bite, maxillary retrognathia, a crossbite in the posterior, and hypoplasia of the maxillary centrals and first molars. In addition, the patient's left mandibular first molars had previously been extracted because of caries, and extraction spaces were present.

We extracted the upper first premolars and right lower first molar for treatment. We then applied a RME appliance, Roth edgewise device and intermaxillary elastics. At the end of treatment, we obtained a Angle class I dental relationship in the canines, an ideal occlusion relationship and an esthetic dental and facial relationship. treatment was completed in 20 months.

(*International Dental and Medical Disorders 2008; 1: 15-23*)

Keywords: Skeletal class III, Openbite, Bonded RME, Molar mesialisation.

Received date: April 2008

Accept date: August 2008

Introduction

Open-bite malocclusion is considered one of the most difficult problems to treat. Proper diagnosis, successful treatment, and long-term retention of open-bite malocclusion have been a constant subject of discussion and research studies. There have been numerous theories proposed regarding the cause of open-bite malocclusion, including inherited facial form, unfavorable growth pattern, posture, digital habits, nasopharyngeal airway obstruction, and tongue posture and function. Several aspects of function, including posture and environmental influences, most likely interact with inherent facial morphology to produce open-bite in some individuals^{1,2}.

The treatment of malocclusion characterized by open-bite is difficult for orthodontists. Because the development of such malocclusions takes place with various etiological factors playing interactive roles. Skeletal open-bite cases are generally characterized by increased vertical growth of the

maxillary posterior dentoalveolar segment. Posterior tooth intrusion becomes more difficult in later years, though there are mechanical treatment options for adult patients. In most adult open-bite cases that show neither severe skeletal problems nor remarkable facial disharmony, nonsurgical treatment has usually been indicated³.

Various therapeutic modalities have been proposed for the treatment of anterior openbite malocclusion. Conventional orthodontic treatment has been directed at inhibiting the vertical maxillary growth with headgear, retarding the mandibular growth with chin cups, or extruding anterior teeth with vertical elastics⁴. Some other methods that have been used for treatment and/or retention of anterior open-bite malocclusion include tongue crib therapy⁵, posterior bite blocks⁶, posterior magnets⁷, magnetic active vertical correctors⁸, and functional appliances⁹.

Because problems of excessive facial height are usually associated with severe anterior open-bite or apertognathia, a combination of orthognathic surgery and orthodontic treatment has been proposed^{10, 11}. The successful treatment of apertognathia represents one of the most challenging areas of orthognathic surgery. Patients with skeletal open-bite are treated with either maxillary or mandibular surgery or a combination of the two. Potential complications include lip

*Corresponding author:

Assit.Prof.Dr. Nihal HAMAMCI
Dicle University Faculty of Dentistry Department of Orthodontics
21280 Diyarbakır/TURKEY

Phone: 00 90 412 2488101/3410 Fax: 00 90 412 2488100
e-mail: nhamamci@dicle.edu.tr

dysesthesia, paresis, hemorrhage, infection, and postoperative joint symptoms. In order to balance the risk versus the benefit, the stability of surgical correction should be carefully scrutinized¹²⁻¹⁴. Even though some studies have reported favorable results^{12, 13}, Denison et al.¹⁴ reported that the open-bite relapsed in 42.9 % of subjects who were treated with LeFort I osteotomy.

Our study is intended to describe successful treatment outcomes using orthodontic mechanics alone in a patient with, open-bite anomaly a high mandibular angle and Class III malocclusion.

CASE REPORT

Our patient was a 18-year-old Turkish female who complained of dissatisfaction with her appearance and particular difficulty when eating and speaking on presentation to our clinic (Figure 1-3).

Intraoral examination revealed maxillary and mandibular crowding, the midline had deviated 3 mm to the left in the maxilla as well as a total open-bite (anterior openbite 5 mm). In addition there was a crossbite in the posterior region and maxillary narrowing. Hypoplasticity was also present in the maxillary central incisors and first molars and the second upper incisors had migrated lingually. There was a fracture in the left upper central incisor. Moreover, the patient's left mandibular first molar teeth had previously been extracted because of caries, and extraction spaces were present (Figure 4-8).

Lateral cephalometric analysis revealed a skeletal Class III and total open-bite anomaly with an ANB angle of -1° and a SN-GoGn angle of 43° . At soft tissue analysis, the distance from the upper lip to the S line was -6 mm and that of the lower lip was -6 mm. The BaPtmGn angle was 82° , showing that the mandible was rotated toward the posterior. Total anterior facial height (Na-Me) was 127 mm, posterior facial height (SGo) was 75 mm, and the S-Go/N-Me ratio was 59 %, showing a skeletal open-bite inclination (Figure 9.10) (Table 1). The aim was to rectify these anomalies at the end of orthodontic treatment. In short, our objective was to provide the patient with an acceptable occlusal relationship and an esthetic facial appearance.

Treatment Objectives

Our treatment objectives were:¹ correction of the total open-bite and maxillary narrowing and the provision of an ideal overjet and overbite relationship,² correction of crowding and occlusal relationships,³ closure of the first mandibular molar extraction spaces and to avoid any prosthetics restoration being required in the lower jaw,⁴ correction of the midline, and⁵ to restore to proper

size and function teeth with hypoplastic anomalies at the end of orthodontic treatment. In short, our objective was to provide the patient with an acceptable occlusal relationship and an esthetic facial appearance.

Treatment Alternatives

Based on the objectives, two treatment options were considered. To attain the overall objectives, combined surgical and orthodontic treatment was proposed. However, the risks and treatment costs would be high. The second option consisted of orthopedic and orthodontic treatment, including rapid palatal expansion to expand the maxilla in a transverse direction. The patient chose the second option, because she thought that the esthetic improvement possible with surgery would not be worth the increased cost and risk. Therefore, nonsurgical orthodontic treatment was performed to correct the occlusal malrelationship and to improve her facial esthetics.

Treatment Progress

In order to widen our patient's maxilla, which was particularly narrow transversally, a bonded RME apparatus was applied and she was asked to rotate this twice a day (at the same times, morning and evening) over two weeks. Our selection of bonded RME was to establish control over the open-bite. In order to resolve the narrowness in the maxilla the right and left first maxillary premolars and the lower right first molar in the mandible were subsequently extracted. The reason why we extracted the mandible right lower first molar was that this tooth had major restoration; it could not remain in a healthy condition in the long term and the fact that its counterpart on the left had previously been extracted.

Fixed Roth Edgewise apparatuses measuring 0.016" x 0.022" were subsequently attached to our patient's upper and lower teeth. The extraction spaces in the upper jaw were used to rectify the narrowness. The extraction spaces in the lower jaw were used for the mesialization of the second molars once the irregularities in the teeth had been made good. Once the teeth in the mandible had been leveled, all teeth apart from the second molars were attached using lase back eight ligatures. We then moved on to the mesialization of the second molars in the mandible. In mesializing the the second molars a supplementary TMA wire arch 0.017 x 0.025- inch dimension was formed in such a way as to pass through the occlusory tube of the lower second molar teeth to prevent their collapsing, the mesial end of the arc was curved into a "C" shape and attached from the mesial (Figure 11) of the second premolars to our continuous arch, thus mesializing the lower teeth

without their collapsing. In this way, mandibular tooth mesialization to help open-bite closed. In order to correct our patient's open-bite box elastics were worn in the anterior and posterior regions. After some 20 months, our patient's orthodontic treatment was complete. After the completion of orthodontic treatment, composite laminate restorations were applied to the maxillary central incisors and first molars.



Fig. 1 Pretreatment facial photographs.



Fig. 2 Pretreatment facial photographs.

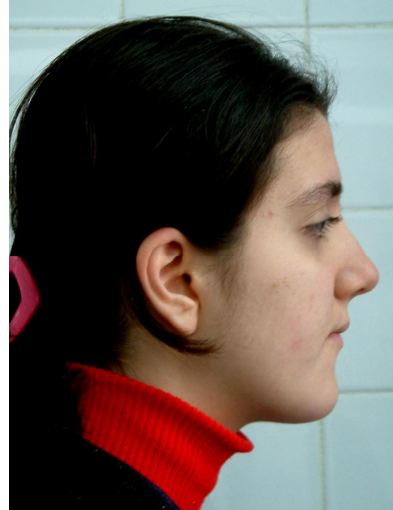


Fig. 3 Pretreatment facial photographs.

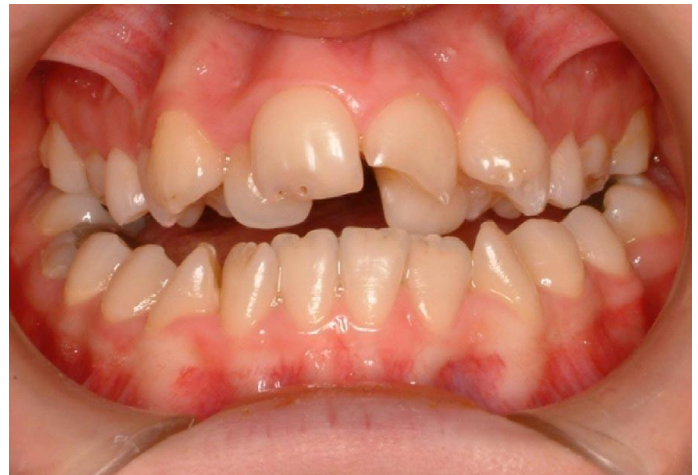

Fig. 4 Pretreatment intraoral photographs.

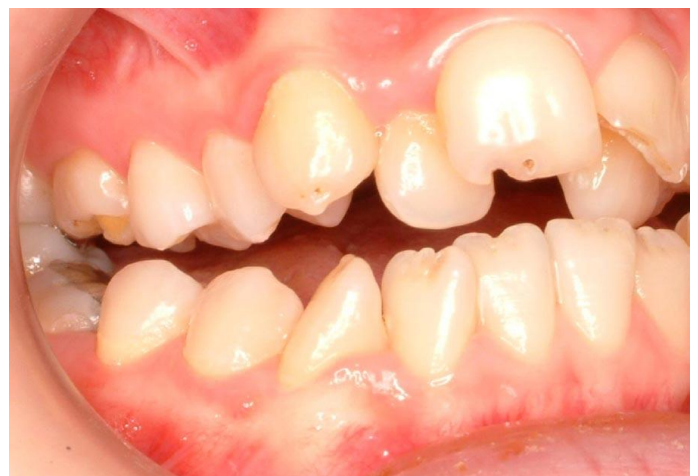

Fig. 5 Pretreatment intraoral photographs.

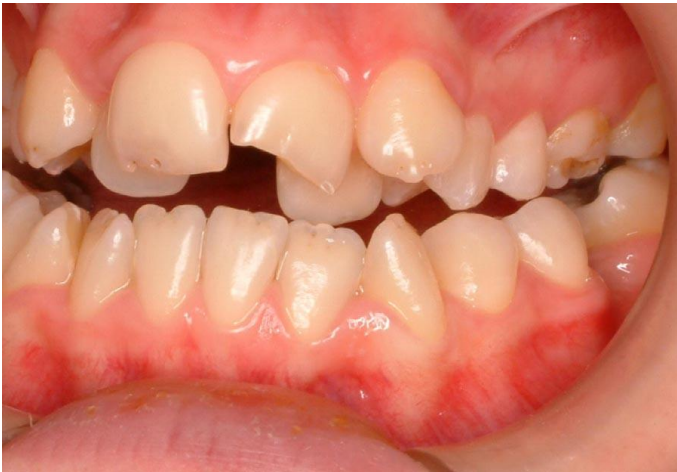

Fig. 6 Pretreatment intraoral photographs.

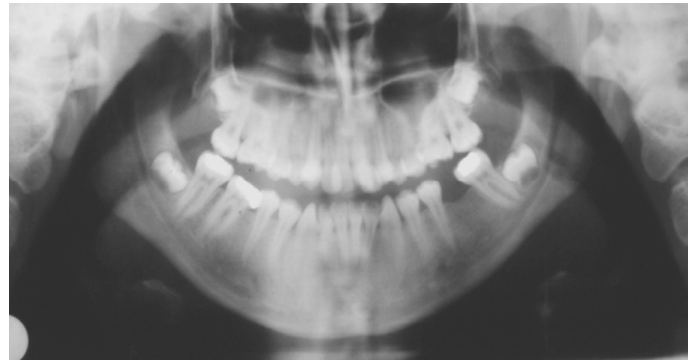

Fig. 9 Pretreatment panoramic radiographs.

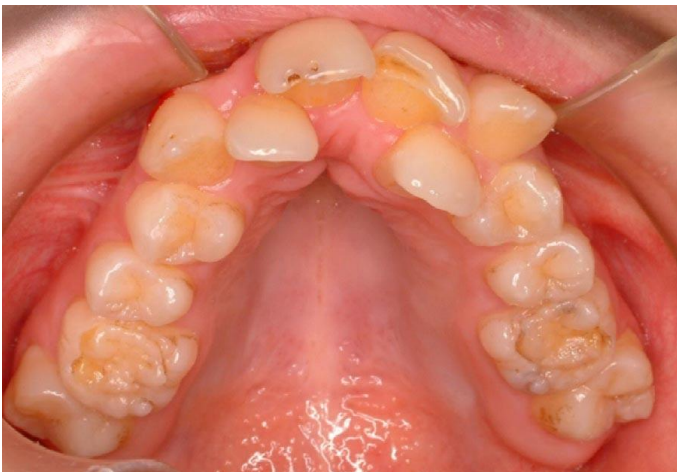

Fig. 7 Pretreatment intraoral photographs.

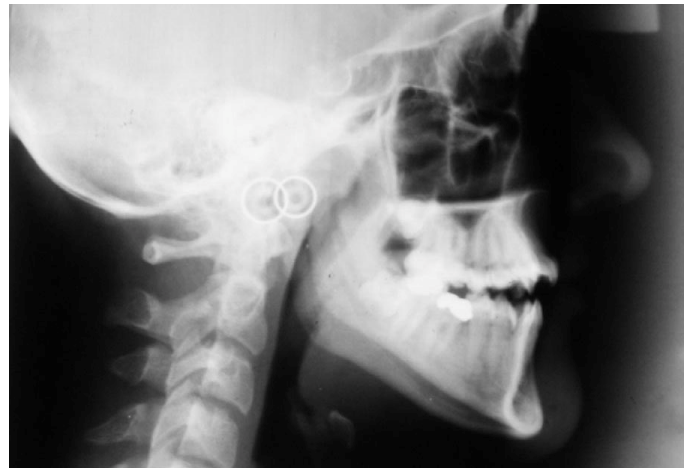

Fig. 10 Pretreatment cephalometric radiographs.

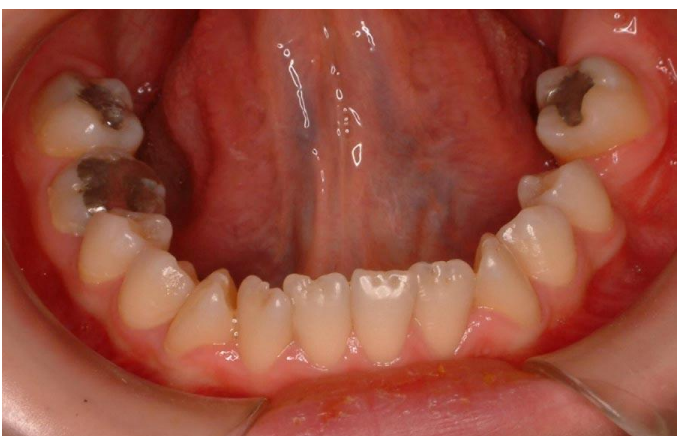

Fig. 8 Pretreatment intraoral photographs.

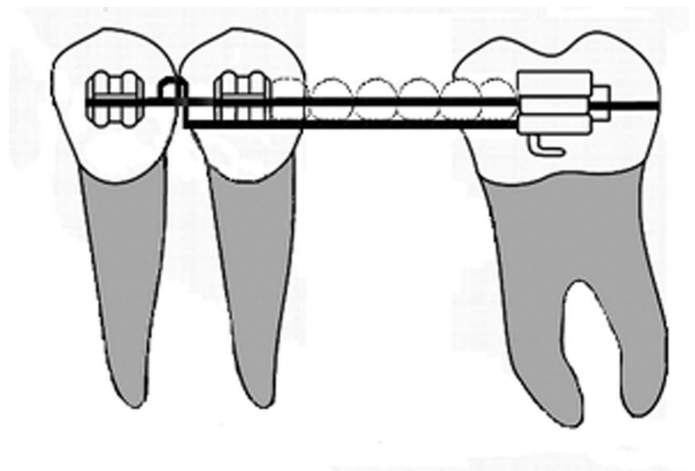


Fig. 11 Mesial molar movement mechanics.

Results

By the end of treatment, we had achieved all our objectives. The total open-bite, maxillary narrowness, crowding, overjet and overbite relations were all rectified. The mandibular first molar extraction spaces were mesialized parallel to the second molars and there was no need for prosthetic restoration (Figure 12-16). In addition, ANB angle had increased from -1° to 2° with mandibular rotation (Figure 17-19) (Table 1).

At the end of treatment, in addition to a functional occlusion, the patient also attained an esthetic facial appearance and a good smile (Figure 20-22). After the end of active treatment, Hawley retainers began being used for retention treatment.

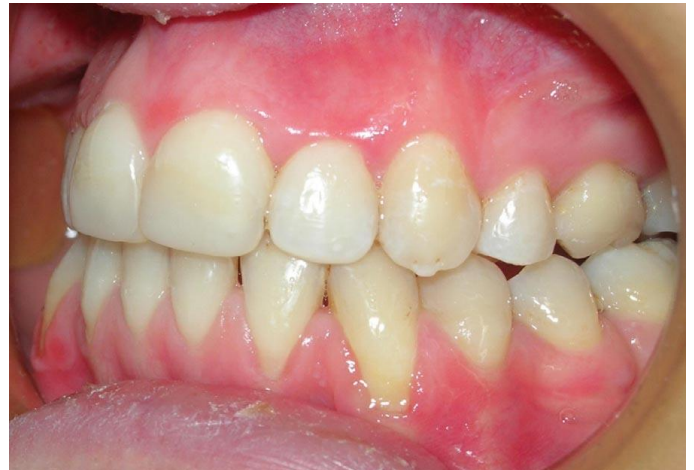

Fig. 14 Posttreatment intraoral photographs.

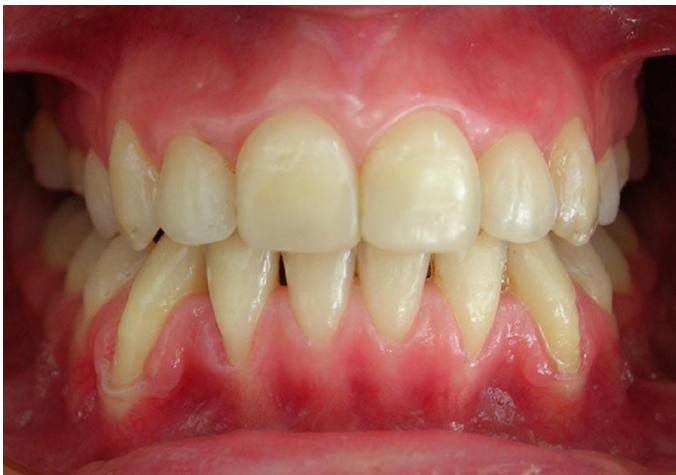

Fig. 12 Posttreatment intraoral photographs.

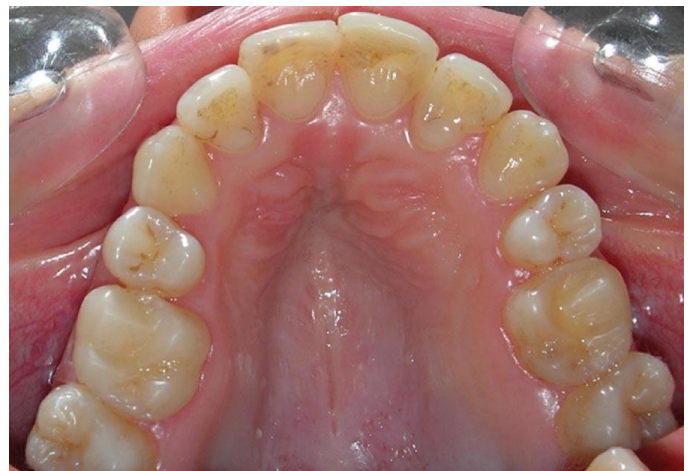

Fig. 15 Posttreatment intraoral photographs.

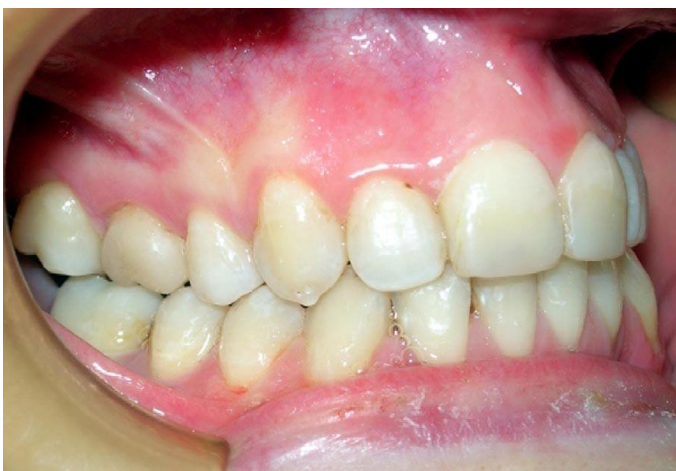

Fig. 13 Posttreatment intraoral photographs.

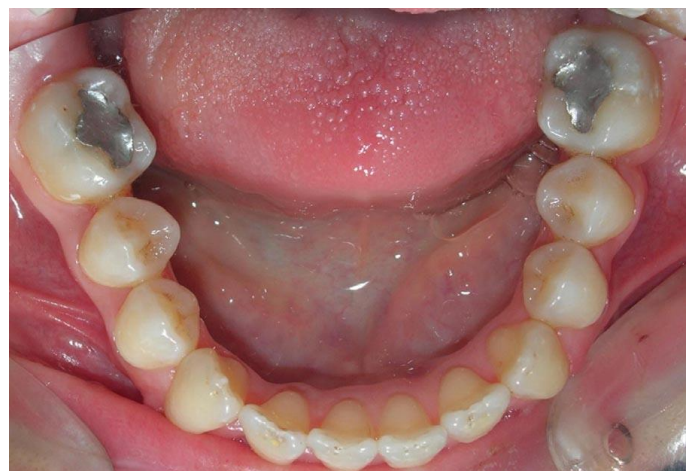

Fig. 16 Posttreatment intraoral photographs.

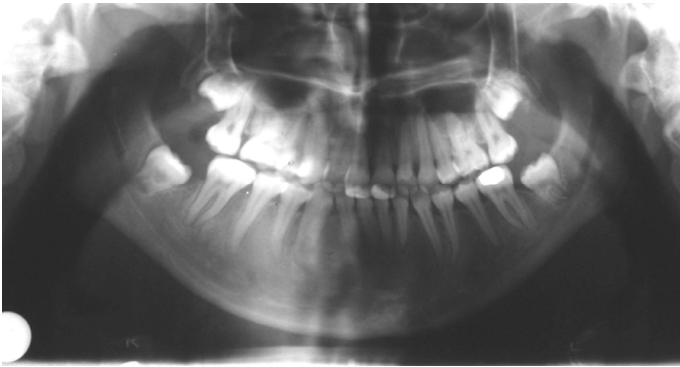

Fig. 17 Posttreatment panoramic radiographs.

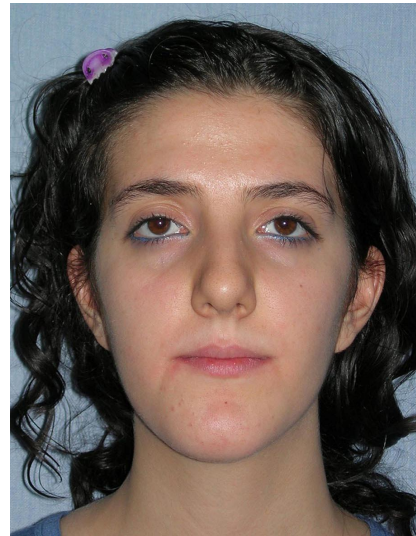


Fig. 20 Posttreatment facial photographs.

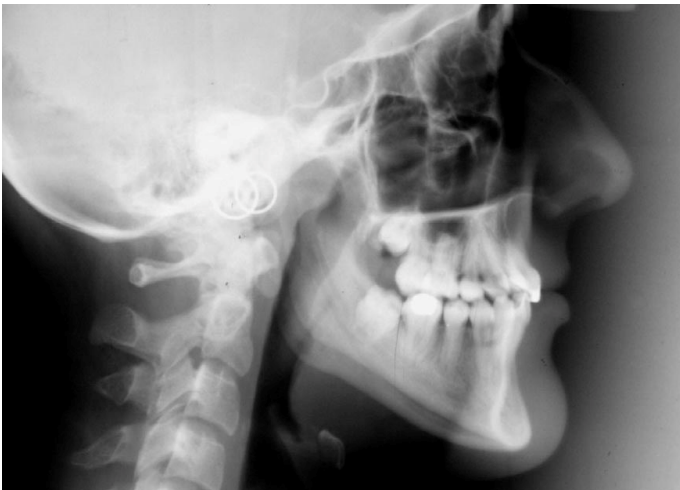

Fig. 18 Posttreatment cephalometric radiographs.

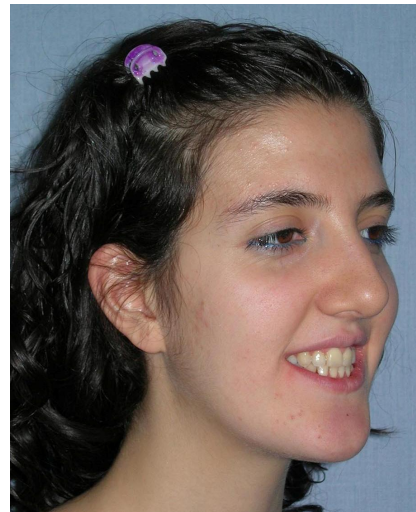

Fig. 21 Posttreatment facial photographs.

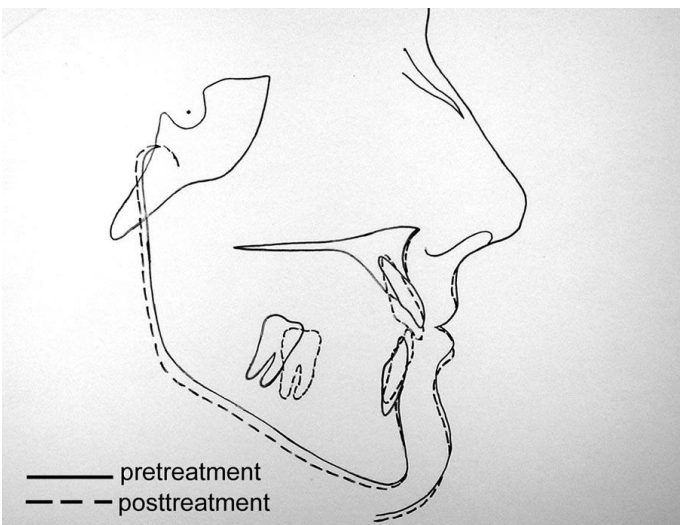


Fig. 19 Cephalometric superimposition

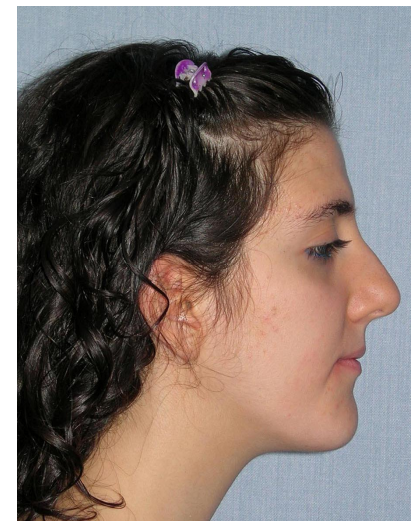


Fig. 22 Posttreatment facial photographs.

Cephalometric Parameter	Pretreatment	Posttreatment
SNA	73°	74°
SNB	74°	72°
ANB	-1°	2°
SND	72°	71°
Co-A	83. mm	84. mm
Co-Gn	125. mm	125. mm
Na-Me	127. mm	130. mm
ANS-Me	72. mm	74. mm
SN-GoGn	43°	42°
Oc. Plane.-SN	21°	21°
Y Axis	68°	65°
Upper Go. Angle	45°	45°
Lower Go. Angle	82°	83°
Total Go. Angle	127°	128°
ANS-PNS	52. mm	52. mm
SD-UL	16. mm	13. mm
LI-LL	15. mm	13. mm
Pog.-Pogs	11. mm	13. mm
Soft Tissue/S Line(Max./Mand.)	-6. mm / -6. mm	-6. mm / -5. mm
Nasolabial Angle	114°	114°
1-NA	29° / 7. mm	25° / 5. mm
1-NB	11° / 2. mm	19° / 4. mm
1/1	138°	135°
S-Go	75. mm	77. mm
BaPtmGn	82°	80°

Tab. 1 Cephalometric measurements pretreatment and posttreatment.

Discussion

Orthodontic correction of the functional and morphological problems that affect the patient's psychology at an early stage could help eliminate a potential inferiority complex and also have a beneficial effect on general personality development¹⁵. Faced with the limitations that orthodontic treatment alternatives present, most orthodontists would agree that this type of case is ideally corrected with a combination of orthodontics and orthognathic surgery¹⁶. The advantages of orthognathic surgical treatment are that the overbite can be over-corrected and relapse is lower than with a nonsurgical option¹⁴. Bell¹⁷ realized that a skeletal open-bite could be corrected with LeFort I osteotomy but some relapse of the open-bite after surgery may occur. In the light of our patient's wishes, we planned nonsurgical orthodontic treatment.

In a nonsurgical plan, the orthodontist will camouflage the skeletal discrepancies to an extent that satisfies as many of the patient's esthetic and functional concerns as possible. Nonsurgical options for open-bite malocclusions include anterior vertical elastics, posterior bite blocks, high-pull headgear, vertical-pull chin cup and the use of microimplants. The patient must be told that nonsurgical correction usually requires a longer treatment time and is more difficult, especially in terms of stability and retention¹⁵. In this case, the nonsurgical correction of the anterior open-bite included dental extractions and anterior vertical elastics.

In most Class III cases, the maxilla is underdeveloped in the lateral, transversal and vertical directions. In such cases, after transversal widening of the maxilla the level of open-bite generally increases and the interdigitation between the upper and lower teeth is resolved¹⁸. The maxilla was also transversally underdeveloped in our case. The reason for our selection of bonded RME was to establish control over the open-bite in our patient.

Lopez-Gavito⁴ et al. reported that more than 35% of their orthodontically treated patients with pretreatment open-bites exhibited a postretention open-bite of 3 mm or more. Both studies seem to implicate some common factor as the cause of open-bite relapse. Although dental and skeletal malrelationships can be corrected, the role of orofacial musculature must also be addressed in orthodontic therapy. If tongue posture and hypotonic buccal musculature can cause a pretreatment open-bite, it is conceivable that recurrence of the open-bite after treatment could be due to the same etiology. The stability of open-bite correction may

increase if the etiology of the open-bite is eliminated during treatment. The initial open-bite severity and the amount of open-bite correction play important roles in open-bite relapse¹⁴. Huang et al.⁵ showed that crib therapy over a several-year period was helpful in achieving stability of the orthodontic correction of open-bite malocclusion. Therefore, if stable correction of the open-bite malocclusion is to be achieved, tongue posture and function must play a role.

The recurrence of anterior open-bite may be linked to the incisors being depressed and/or lengthening of the molars. Open-bite recurrence in individuals with no habit of placing any object between the anterior teeth depends on the lengthening of the rear teeth with no incisor intrusion. Vertical growth and eruption of posterior teeth may continue until the end of the teenage years, and this shows the difficulty in controlling overbite. For that reason, the retention period needs to be lengthy in patients with open-bite and must be of such a kind as to establish control of the posterior teeth¹.

Stability of open-bite malocclusion correction in the permanent dentition is the major concern in the orthodontic treatment of this problem^{4, 5, 14}. Several authors investigated the stability of open-bite malocclusion correction without differentiating between extraction and nonextraction treatment approaches^{4, 5}. More recently, we conducted 2 studies that separately investigated the stability of nonextraction¹⁹ and extraction²⁰ treatment, and the results pointed toward greater stability of extraction treatment.

Recurrence may also arise following surgical treatment in malocclusions of this kind¹⁴. For that reason, we aimed at an extended retention period in order to prevent recurrence in the treatment of our patient, and informed her on this matter.

In their study, Freitas et al.²⁰ determined statistical significance in terms of stability angle in 74.2% in patients administered open-bite treatment with extraction in permanent dentition.

Conclusion

This study demonstrates the treatment mechanism of nonsurgical treatment of an 18-year-old subject with severe skeletal Class III and total open-bite malocclusion in the permanent dentition. Successful outcomes can be obtained with nonsurgical treatment in such cases.

References

1. Proffit WR, Fields HW Jr. Contemporary Orthodontics. St Louis: Mosby-Year Book INC; 1993.
2. Kim YH. Anterior openbite malocclusion: nature,

- diagnosis and treatment by means of multiloop edgewise archwire technique. *Angle Orthod* 1987;57:290-321.
3. Nielsen IL. Vertical malocclusions: etiology, development, diagnosis and some aspects of treatment. *Angle Orthod*. 1991;61:247-60.
 4. Lopez-Gavito G, Wallen TR, Little RM, Joondeph DR. Anterior open-bite malocclusion: a longitudinal 10-year postretention evaluation of treated patients. *Am J Orthod* 1985;87:175-86.
 5. Huang GJ, Justus R, Kennedy DB, Kokich VG. Stability of anterior openbite treatment with crib therapy. *Angle Orthod* 1990;60:17-24.
 6. Woodside D, Aronsen S. Progressive increases in lower anterior face height and the use of posterior bite-block in its management: treatment and technique principles. In: Graber LW, ed. *Orthodontics, state of the art: essence of the science*. St Louis: CV Mosby Company; 1986. p. 200-21.
 7. Woods MG, Nanda RS. Intrusion of posterior teeth with magnets. *Angle Orthod* 1988;58:136-50.
 8. Barbre RE, Sinclair PM. A cephalometric evaluation of anterior openbite correction with the magnetic active vertical corrector. *Angle orthod* 1991;61:93-102.
 9. Frankel R, Frankel C. A functional approach to treatment of skeletal openbite. *Am J Orthod* 1983;83:54-68.
 10. Bell WH, Creekmore TD, Alexander RG. Surgical correction of the long-face syndrome. *Am J Orthod* 1977;71:40-67.
 11. Epker BN, Fish LC. Surgical-orthodontic correction of openbite deformity. *Am J Orthod* 1977;71:278-99.
 12. Frost DE, Fonseca RJ, Turvey TA, Hall TJ. Cephalometric diagnosis and surgical orthodontic correction of apertognathia. *Am J Orthod* 1980;78:657-69.
 13. Proffit WR, Phillips C, Turvey TA. Stability following superior repositioning of the maxilla by LeFort I osteotomy. *Am J Orthod Dentofacial Orthop* 1987;92:151-61.
 14. Denison TF, Kokich VG, Shapiro PA. Stability of maxillary surgery in openbite versus non-openbite malocclusions. *Angle Orthod* 1989;59:5-10.
 15. Kondo E, Aoba TJ. Nonsurgical and nonextraction treatment of skeletal Class III open bite: Its long term stability. *Am J Orthod Dentofacial Orthop*. 2000;117:267-87.
 16. Hiller ME. Nonsurgical correction of Class II open bite malocclusion in an adult patient. *Am J Orthod Dentofacial Orthop*. 2002;122:210-6.
 17. Bell WH. LeFort I osteotomy for correction of maxillary deformities. *J Oral Surg* 1975;33:412-26.
 18. Isaacson JR, Isaacson RJ, Speide TM, Worms FW. Extreme variation in vertical facial growth and associated variation in skeletal and dental relations. *Angle Orthod*. 1971;41:219-229
 19. Janson G, Valarelli FP, Henriques JF, de Freitas MR, Cancado RH. Stability of anterior open bite nonextraction treatment in the permanent dentition. *Am J Orthod Dentofacial Orthop* 2003;124:265-276.
 20. Freitas MR, Targino R, Beltrao S, Janson G. Long-term stability of anterior open bite extraction treatment in the permanent dentition. *Am J Orthod Dentofacial Orthop* 2004;125:78-87.