

# Is Tolvaptan in the Treatment of SIADH Following Pituitary Surgery a Right Choice?

Süleyman KARAKOSE    Ayşe Zeynep BAL    Selman UNVERDI    Murat DURANAY

Department of Nephrology, Ankara Training and Research Hospital, Ankara, Turkey

**Background:** Fluid and electrolyte disturbances, especially hyponatremia are common complications after pituitary surgeries. Syndrome of inappropriate antidiuretic hormone secretion (SIADH) is the leading cause of hyponatremia in hospitals. Fluid restriction is the first step in treatment of SIADH. In rare cases vasopressin receptor inhibitors might be useful for medical treatment.

**Case Presentation:** In this paper, we present a case of SIADH after a pituitary surgery with an unpredictable effect of tolvaptan.

**Conclusion:** Tolvaptan is the most preferred agent for the treatment of SIADH nowadays. However tolvaptan might cause unpredictable situations in the course of treatment that clinicians must be very careful and in close follow up the patient.

**Keywords:** Hypernatremia, hyponatremia, pituitary surgery, SIADH, tolvaptan

## Introduction

The state of serum sodium level less than 135 mEq/L is defined as hyponatremia. Hyponatremia generally results from the retention of undue water compared to sodium rather than sodium loss alone. The over secretion of antidiuretic hormone (ADH) impairs the water excretion and causes hyponatremia; this disorder is named as the syndrome of inappropriate antidiuretic hormone secretion (SIADH). SIADH is the leading cause of hyponatremia in hospital settings (1).

After pituitary surgeries fluid and electrolyte disturbances are common complications and

hyponatremia can occur in an isolated fashion or as part of a bi or triphasic pattern. Generally SIADH's due to the pituitary surgery has a self-limiting course and will recover within 2-5 days (2).

In case of SIADH, therapeutic options are treatment of the underlying disease, fluid restriction, in severe cases intravenous saline and vasopressin receptor antagonists like vaptans (3). Tolvaptan inhibits the V<sub>2</sub> receptors of ADH and causes to only water diuresis without sodium and potassium excretion (4). The serum sodium level will be on an upward trend by electrolyte-free water loss in SIADH

**Corresponding Author:** Suleyman Karakose; Department of Nephrology, Ankara Training and Research Hospital, 06340, Altindag, Ankara, Turkey

**E-mail:** suleymankarakose@yahoo.com

**Received:** May 21, 2016 **Accepted:** July 13, 2016

**Published:** July 25, 2016

This is an Open Access article distributed under the terms of the Creative Commons Attribution Non-Commercial License which permits unrestricted non-commercial use, distribution, and reproduction in any area, provided original work is properly cited.

The Ulutas Medical Journal © 2016



patients after tolvaptan and this will improve mental state of patients with hyponatremia. Herein we present a case of SIADH after pituitary surgery with an unpredictable effect of tolvaptan.

### Case Presentation

A 29-year-old female with past medical history of Hashimoto's disease admitted to the hospital with progressive headache and syncope. On admission the patient's all laboratory parameters were in normal range. Computed tomography (CT) of the head showed that a lobulated solid lesion which has dimension of 24x19x21 mm in the pineal region. The lesion had applied pressure on exit of third ventricle; aqua ductus cerebri and caused to dilatation of third and lateral ventricles.

She was operated on 19<sup>th</sup> August 2015. Two weeks after her operation she was consulted nephrology unit for acute hyponatremia (116 mmol/L). Her physical examination was unremarkable. There were no signs of volume depletion or edema. There were no obvious pulmonary disease, neoplasms, adrenal insufficiency, or vomiting. She was found to have low plasma osmolality (247 mOsm/kg H<sub>2</sub>O) and high urine osmolality (436 mOsm/kg H<sub>2</sub>O). The urinary sodium was 121 mmol/L.

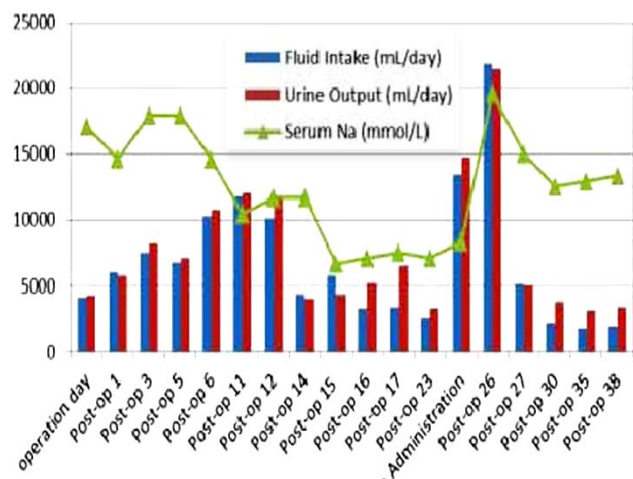


Figure-1. Post operative water balance and serum sodium levels of patient.

She reported compliance with levothyroxine and was clinically euthyroid (TSH=1.45 mIU/L). Her profound hyponatremia was attributed to SIADH. Fluid restriction, hypertonic saline (0.3 %) and aggressive diuresis with furosemide was done and rise in serum sodium levels were not satisfactory. Tolvaptan 15 mg was started on the 25th day after operation with serum level of sodium 120 mmol/L (Figure-1).

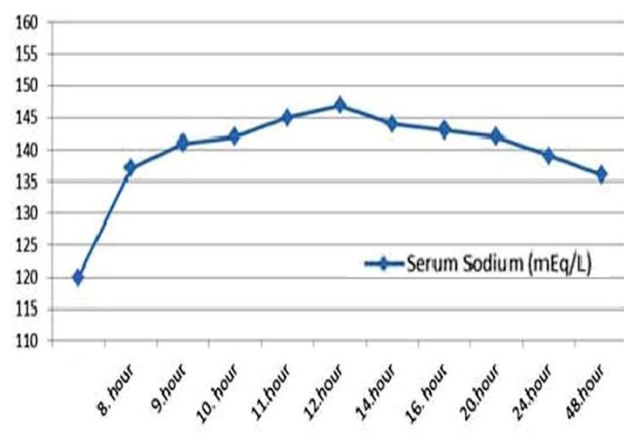


Figure-2. Serum sodium levels after tolvaptan

After 8 hours she had a rapid increase in his serum sodium level from 120 mmol/L to 137 mmol/L after she received the first dose of tolvaptan. Her serum sodium levels further increased from 137 mmol/L to 147 mmol/L within 12 hours. At this point, tolvaptan was stopped. The effects of tolvaptan on serum sodium levels have been shown in Figure-2. Rapid corrections with hypotonic fluids were started at 8th hour of the treatment and the patient did not develop signs of osmotic demyelination syndrome.

### Discussion

The most common complications after pituitary surgery are fluid and electrolyte imbalances. The incidence of hyponatremia due to transsphenoidal surgery is between 2-25% (5). Hyponatremia could be seen in an isolated fashion or as part of a bi or triphasic pattern after transsphenoidal surgery. The

triphasic pattern is rare and encountered in %3.4 of patients and the first two phases happened just in 1.1% of patients who had surgery (6). The first phase of diabetes insipidus generally has a duration of 5–7 days and the second phase is antidiuretic phase of SIADH (7).

In our patient, hyponatremia was observed after two week the surgery that remind us second phase of DI. Although there is no hypernatremia in the first polyuric period but in the following period low serum osmolality accompanied by high urine osmolality was observed that is compatible with SIADH. However our second phase is somewhat different from general triphasic DI because our second period occurred almost one week later than expected time. The isolated hyponatremia might be a subtype of classic triphasic DI that has also three phases; first one is a polyuric phase which is followed by a transient SIADH and after that third phase is recovery or persistent diabetes insipidus (8).

There was inadequate response despite the aggressive fluid restriction and force diuresis in the treatment of SIADH in our patient so that Tolvaptan has been added to the therapy. Unfortunately a rapid rise of serum sodium was occurred after Tolvaptan which is generally an unexpected respond during this kind of treatment and it's important because the risk of osmotic demyelination. Verbalis JG et al. reported that the second phase of Triphasic DI might last between 2-14 days so that it may be appropriate to use Tolvaptan if patients have symptoms of hyponatremia (9). However, the rapid increase in sodium levels in our patient after Tolvaptan may be due to personal factors, such as receptor hypersensitivity or may be a schedule dilemma because tolvaptan might be added to the treatment just before the third phase of DI so that this may be reason of rapid rise of serum sodium.

In conclusion, clinicians should not rush to Tolvaptan for the treatment of hyponatremia after pituitary surgery unless patient became symptomatic. However detailed protocols and algorithms for the management of hyponatremia following pituitary surgery are lacking and further researches are needed.

### Conflict of Interest

The authors declare that there is no conflict of interest among the authors.

### Reference

1. Borges I, Runkle I, Villabona C, Navarro A, Pose A, Formiga F, Tejedor A, et al. Treatment of hyponatremia induced by the syndrome of Inappropriate antidiuretic hormone secretion: a multidisciplinary algorithm. *Nefrologia* 2014;34(4):439-50.
2. Janneck M, Burkhardt T, Rotermund R, Sauer N, Flitsch J, Aberle J. Hyponatremia after trans-sphenoidal surgery. *Minerva Endocrinologica* 2014;39(1):27-31
3. Rose BD. New approach to disturbances in the plasma sodium concentration. *Am J Med* 1986; 81(6):1033.
4. Verbalis JG, Goldsmith SR, Greenberg A, Schrier RW, Sterns RH. Hyponatremia treatment guidelines 2007: expert panel recommendations. *Am J Med* 2007; 120:1.
5. Janneck M, Burkhardt T, Rotermund R, Sauer N, Flitsch J, Aberle J. Hyponatremia after trans-sphenoidal surgery. *Minerva Endocrinol* 2014; 39(1): 27-31.
6. Hensen J, Henig A, Fahlbusch R, Meyer M, Boehnert M, Buchfelder M. Prevalence, predictors and patterns of postoperative polyuria and hyponatraemia in the immediate course after transsphenoidal surgery for pituitary adenomas. *Clin Endocrinol (Oxf)* 1999;50:431-439.
7. Loh JA, Verbalis JG. Diabetes insipidus as a complication after pituitary surgery. *Nat Clin Pract Endocrinol Metab* 2007;3(6):489-94.
8. Ghirardello S, Hopper N, Albanese A, Maghnie M. Diabetes insipidus in craniopharyngioma: postoperative management of water and electrolyte disorders. *J Pediatr Endocrinol Metab* 2006; 19: 413-21.
9. Verbalis JG, Robinson AG, Moses AM. Postoperative and posttraumatic diabetes insipidus. In *Diabetes Insipidus in Man*, *Front Horm Res* 1984; 13: 247

### How to cite?

Karakose S, Bal AZ, Unverdi S, Duranay M. Is Tolvaptan in the Treatment of SIADH Following Pituitary Surgery a Right Choice? *Ulutas Med J*. 2016;2(3):154-156.

Doi:10.5455/umj.20160703095035

<http://www.ulutasmedicaljournal.com>