

FT39

Urofacial Syndrome (Ochoa Syndrome) : A Case Report

Ürofasiyal Sendrom (Ochoa Sendromu) : Olgu Sunumu

Gülüzar GÜRHAN¹, Bülent ATAŞ², Mesut PİŞKİN³

¹Necmettin Erbakan University Meram Medical Faculty Department of Pediatrics, Konya

²Necmettin Erbakan University Meram Medical Faculty Department of Pediatrics, Division of Pediatric Nephrology, Konya

³Necmettin Erbakan University Meram Medical Faculty Department of Urology, Konya

Abstract: Urofacial syndrome (US) or Ochoa syndrome is a syndrome characterized by presence of neurogenic bladder (NB) in absence of a neurological abnormality and mechanical obstruction, as well as by a characteristic facial appearance. As the micturition/urine storage center, laughing and crying centers and origin of the facial nerve are in close proximity in the reticular formation, crying facial expression when laughing and clinical presentation of NB are observed. In this manuscript a case who presented with incontinence, was noticed to have crying facial expression when laughing and, unfortunately, developed chronic renal failure (CRF) due to NB is reported.

Keywords: Incontinence, Urofacial syndrome, Neurogenic bladder, Renal failure

Özet: Ürofasiyal sendrom (ÜS) veya Ochoa sendromu, nörolojik anormallik ve mekanik obstruksiyon olmadan nörojenik mesane (NM) ve karakteristik yüz görünümü olan bir sendromdur. Retiküler formasyondaki işeme ve idrar depolamayla ilgili olan merkez, gülme ve ağlama merkezleri ve fasiyal sinirin çıkış noktası birbirine yakın olduğundan gülerken ağlayan yüz ifadesi ve NM tablosu görülür. Bu yazıda inkontinans şikayeti ile gelen ve gülerken ağlayan yüz ifadesi dikkati çeken ve maalesef NM'ye bağlı kronik böbrek yetmezliği (KBY) gelişmiş olan bir olgu sunulmuştur.

Anahtar Kelimeler : İnkontinans, Ürofasiyal sendrom, Nörojen mesane, Böbrek yetmezliği

Introduction

Urofacial syndrome (Ochoa syndrome) was defined by Bernardo Ochoa in children with neurogenic bladder in absence of a neurological abnormality and “crying facial expression when laughing”. Genetic studies have demonstrated that this syndrome is inherited in an autosomal recessive manner and the responsible gene is located on chromosome 10q23-q24 (1). Leucine-rich-repeats and immunoglobulin-likedomains 2 (LRIG2) and heparanase 2 (HPSE2) mutations have been shown to be associated with the disease (2). It increases the risk of bladder dysfunction, urinary incontinence, vesicoureteral reflux, hydroureteronephrosis, urosepsis and progressive renal insufficiency (3).

Case Report

A 9 year-old male patient presented with day-night urinary incontinence persisting for 4 years. His parents were distant relatives. He had been operated for umbilical hernia at 3 months of age and for inguinal hernia at 7 years of age. His background was nonspecific. The patient had a

crying facial expression when laughing (Figure 1B). His neurological examination was normal. His laboratory results at admission were as follows: hemoglobin:8.7 g/dl, serum creatinine: 2.4 mg/dl and urea:82 mg/dl. On renal ultrasonography; bilateral hydroureteronephrosis, thinning of renal cortex and thickening of bladder wall were present. Bilateral grade 5 vesicoureteral reflux (VUR) (Figure 2A) and increased bladder capacity (Figure 2B) were detected in voiding cystourethrography. In urodynamic examination, flask neuropathic bladder was determined. His lumbosacral magnetic resonance imaging was normal. In dynamic renal scintigraphy, functions of left kidney were decreased and the right kidney was nonfunctioning. During follow-ups, he had episodes of pyelonephritis. At 12 years of age, he underwent right nephrectomy and left ureteroneocystostomy. Episodes of pyelonephritis continued to occur despite of clean intermittent catheterization and prophylactic antibiotherapy. He was put on hemodialysis due to chronic renal failure at 15 years of age. At 16 years of age, renal transplantation was performed.

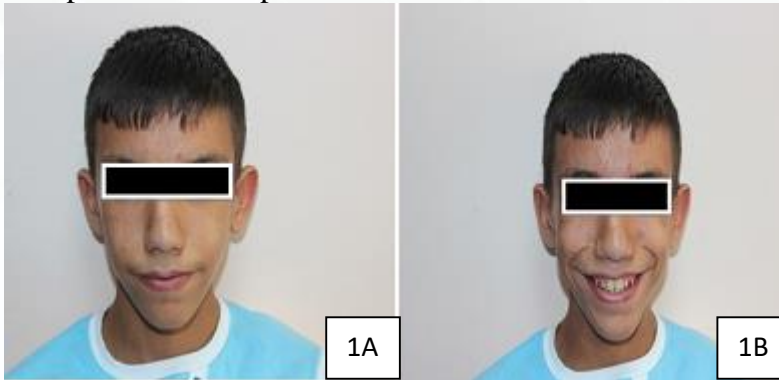

Figure 1A: Normal appearance Figure 1B: Crying facial expression when laughing

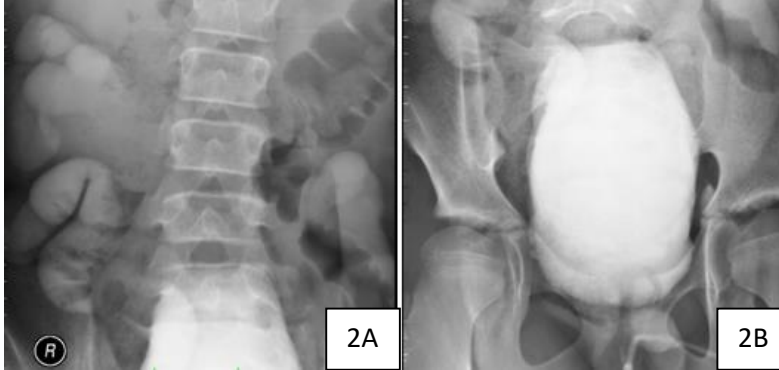


Figure 2A: Grade 5 VUR Figure 2B: Increased bladder capacity

Discussion

While lower urinary tract anomalies are common in children, urofacial syndrome is rare (4). Urofacial syndrome is composed of obstructive uropathy in absence of a neurological abnormality and mechanical obstruction, as well as a characteristic facial appearance. Laughing and crying centers, as well as origin of the facial nerve and the center responsible for micturition/urine storage are in close proximity in the brainstem (5).

Urofacial syndrome is characterized by lower urinary tract injury and a high-grade VUR causing renal failure. One third of the patients have constipation (6). Our patient had non-neurogenic neurogenic bladder, evidence indicating lower urinary tract dysfunction, abnormal smiling and renal failure. He did not have constipation. These findings were consistent with diagnosis of urofacial syndrome.

In conclusion, early diagnosis is important in urofacial syndrome, as there may be NB that leads to renal injury. It can be very important for patients with incontinence to be comprehensively

examined, including smiling, as NB may lead to CRF when its early diagnosis and treatment are delayed and it is not followed-up.

References

1. Ochoa B (2004) Can a congenital dysfunctional bladder be diagnosed from a smile? The Ochoa syndrome updated. *PediatrNephrol* 19(1):6–12 2
2. Neil A. Roberts; *Lrig2 and Hpse2, mutated in urofacial syndrome, pattern nerves in the urinary bladder*, *Kidney International* (2019) 95, 1138–1152
3. Newman WG, Woolf AS, *Urofacial syndrome*; *GeneReviews*[®] [Internet]. Seattle (WA): University of Washington, Seattle; 1993-2019. 2013 Aug 22
4. Farhat W, Bagli D, Capolicchio G, et al. The dysfunctional voiding scoring system: qualitative standardization of dysfunctional voiding symptoms in children. *J Urol* 2000;164:1011.
5. Akl KF, Al Momany HM, *Urofacial Syndrome*; *Saudi J Kidney Dis Transpl* 2012;23(2):346-348
6. Daly SB, Urquhart JE, Hilton E, et al. Mutations in HPSE2 cause urofacial syndrome. *Am J Med Genet* 2010;86(6):963-9.