

PERIPHERAL OSTEOMA OF THE MANDIBLE: A CASE REPORT*

Mandibulada Periferik Osteom: Olgu Sunumu

Mustafa GÜMÜŞOK¹, Şerife DEĞERLİ¹, Mehmet Emin TOPRAK², Anıl SEÇKİN², Elif KAYA¹,
 Burcu ŞENGÜVEN³

Received: 29/11/2013

Accepted: 04/07/2014

ABSTRACT

Osteomas are benign tumors which are composed of mature compact or cancellous bone. They can be either peripheral, central or extraskeletal. The peripheral osteoma arises from surface of the bone (periosteal) whereas the central osteoma arises from the bone medullary (endosteal) and the extra-skeletal soft tissue osteoma usually develops within the muscle. Osteomas are most commonly found in the skull and facial bones. Multiple osteomas may be associated with Gardner's Syndrome. These lesions are usually painless and recurrence is uncommon after local excision. In this case report clinical, radiographic findings and treatment of a 24-year-old male patient with peripheral osteoma in the anterior mandible are presented.

Keywords: Peripheral osteoma, mandible, cone beam computed tomography, excision

ÖZ

Osteomlar olgun kompakt veya spongiöz kemikten oluşan selim tümörlerdir. Osteom periferik, santral veya iskelet dışı olabilir. Periferik osteom kemik yüzeyinden (periosteal), santral osteom spongiöz kemikten (endosteal) gelişir. İskelet dışındaki yumuşak doku osteomu ise genellikle kas dokusunda oluşur. Osteomlar en sık kafa kemiklerinde görülürler. Multipl osteomlar Gardner Sendromu ile ilişkili olabilirler. Osteomlar genellikle ağrısızdırlar ve cerrahi olarak çıkartıldıktan sonra nüks etmezler. Bu olgu bildirisinde 24 yaşında erkek hastanın mandibula anterior bölgesinde teşhis edilen periferik osteomun klinik, radyografik bulguları ve tedavisi sunulmuştur.

Anahtar kelimeler: Periferik osteom, mandibula, konik ışınli bilgisayarlı tomografi, eksizyon

¹ Department of Dentomaxillofacial Radiology Faculty of Dentistry Gazi University

² Department of Oral and Maxillofacial Surgery Faculty of Dentistry Gazi University

³ Department of Oral Pathology Faculty of Dentistry Gazi University

* This case report was presented as a poster at the 6th International Scientific Congress of Istanbul University Faculty of Dentistry in Istanbul, Turkey



Introduction

Osteomas are benign osteogenic tumors which consist of compact and spongy bone (1). They are classified as central, peripheral, and extraskeletal, according to their origins (2). The central type arises from the endosteum, the peripheral osteomas from the periosteum while the extraskeletal soft tissue osteomas often develop within the muscles (3). Osteomas are more common in the craniofacial bones when compared to other skeletal sites (4).

The present case report describes the clinical, radiological, and histopathological features of a patient presenting with a peripheral osteoma located in the anterior surface of the mandible.

Case report

A 24-year-old male patient presented to our clinic with swelling in the anterior surface of lower jaw. It has been two years after the onset of his initial symptoms. The patient did not report pain, but he was suffering from cosmetic problems associated with the swelling. His medical history did not reveal any systemic disease or regular use of medication. During intra-oral examination, a round and immobile nodule was observed on the right anterior surface of the mandible adjacent to teeth number 41 and 42 (FDI two-digit tooth numbering system) (Figure 1).

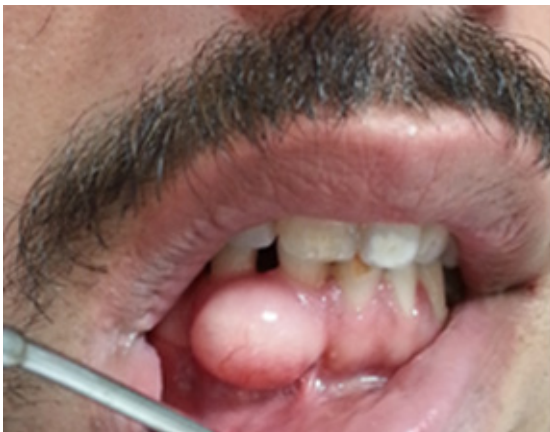

Figure 1. Intra-oral appearance of the lesion.

Extra-oral examination showed unilateral asymmetry of the right lip due to the lesion mass (Figure 2).

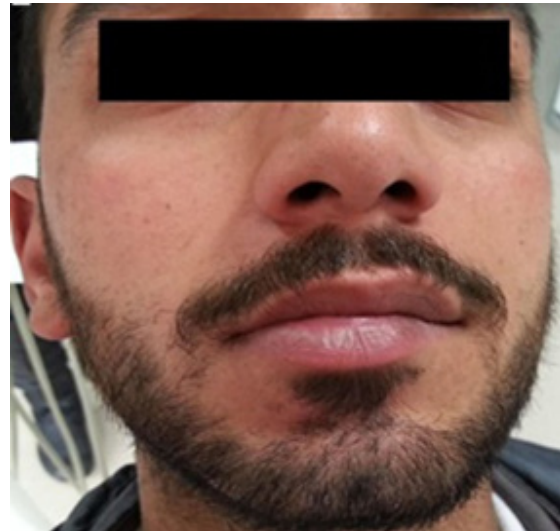

Figure 2. Extra-oral appearance of the lesion and asymmetry in the right lower lip.

Panoramic radiography showed a radioopaque lesion in the region that corresponds to the swollen area (Figure 3).

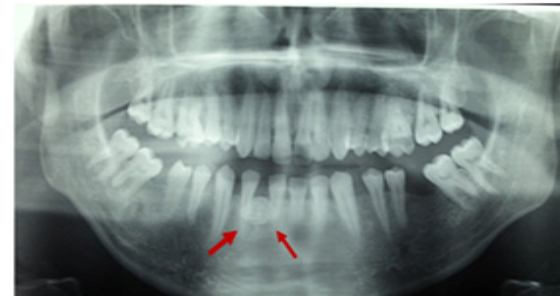

Figure 3. Panoramic radiograph revealing the radioopaque lesion.

The axial images obtained from cone beam computed tomography showed an oval-shaped and dense radioopaque lesion with well-defined margins, measuring 10x8x10 mm in size and located in the alveolar bone adjacent to mandibular crest (Figure 4).

The patient underwent an operation in the Department of Oral and Maxillofacial Surgery and the lesion was excised under local anesthesia.

A histopathological examination was performed in the Department of Oral Pathology with the protocol number of 1426 (Figure 5).

The diagnosis of peripheral osteoma was established based on the clinical, radiological, and histological findings.

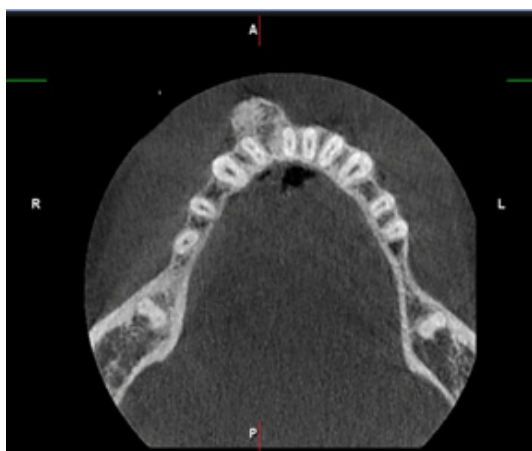

Figure 4. The axial images obtained from the cone beam computed tomography shows the dense appearance of the lesion.

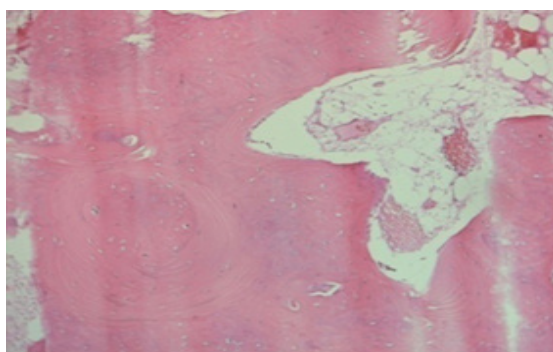


Figure 5. The histopathological examination of the lesion that shows mature lamellar bone and minimal fatty bone marrow (HE stain, x100).

Discussion

Osteomas are benign, slow-growing, well-defined osteogenic lesions developing from mature bone. They are characterized by the proliferation of compact or cancellous bone (5). The etiology of osteomas remains unknown. Some authors consider such lesions as true neoplasms, while others classify them as developmental anomalies (6, 7, 8). The continuation of growth after adulthood is the most characteristic feature that distinguishes these lesions from other bony exostoses, and this pattern signifies the neoplastic nature of the lesion (9, 10). Traumas and infections are considered to trigger excessive bone activity (7, 10). However, present case did not have any history of trauma or infection. Osteomas can occur at any age. However, they are most commonly diagnosed in the third and fifth decades of life and

are more frequent in males than in females (11). The present case was also a male patient in the second decade of his life. These lesions occur in the paranasal sinuses and most commonly involve the frontal and ethmoid sinuses (5). External auditory tract, orbita, temporal bone, and pterygoid processes are other sites of involvement (12). The peripheral osteomas rarely occur in the mandible (13). The mandibular peripheral osteomas are often located in the mandibular condyle and angulus, and less commonly involve the ramus or molar area (13). In the present case, the lesion was located in the anterior surface and buccal aspect of the mandible, which is a rare site of involvement.

Clinically, these lesions are characterized by slow and continuous growth patterns (8), unilateral involvement, well-defined margins, and mushroom-shaped masses with or without a stalk, and with a diameter between 1.5 and 4 cm (14). Clinical characteristics of our case were consistent with these findings. Osteomas are usually asymptomatic, and they are detected during routine radiographic examinations, unless they enlarge enough to cause facial asymmetry or functional impairment (4, 15). In the present case, the enlargement of the lesion caused lip asymmetry. On radiological examination, peripheral osteomas appear as an oval-shaped radioopaque mass with well-defined margins and growing on a broad base or a stalk on the cortex. These lesions usually do not cause destruction of the adjacent bone tissue (16). In the present case, the lesion was limited to the cortex and did not cause destruction in the neighboring tissues. The differential diagnosis of peripheral osteoma includes neoplastic lesions such as exostoses and peripheral ossified fibroma, periosteal osteoblastoma, osteoid osteoma, periosteal osteosarcoma, and focal sclerosing osteomyelitis (4, 6). The presence of compact bone formation and the absence of proliferative fibrous components were taken into account in the histological differential diagnosis. The sarcoma diagnosis was not considered due to the benign nature of the lesion. Differential diagnosis of a central osteoma located within the bone should include fibrous dysplasia, central ossified fibroma, odontoma, osteoblastoma, chondroma, cementoblastoma, Paget's disease, and central osteosarcoma (4, 6, 8). In addition, the presence of pain in up to 30% of cases with central osteoma is an important finding in the differential diagnosis (8).

Histologically, compact osteomas are made of normal dense bone with minimal bone marrow tissue. The cancellous osteomas are made of trabecular bone

and fatty bone marrow. There is marked osteoblastic activity (17). The histopathological findings in the present case were consistent with those in compact type. Multiple osteomas were associated with Gardner's syndrome characterized by colorectal polyposis, cutaneous sebaceous cysts, and multiple supernumerary teeth (8, 18). The present case did not have any gastrointestinal complaints or dental anomaly. Clinical examination did not show any finding suggestive of Gardner's syndrome.

Surgical excision is the ideal treatment for osteomas. The lesions rarely show recurrence, and malignant transformation has not been reported (4). In the present case, the lesion was totally excised and the patient was placed on follow-up.

Conclusion

Mandibular peripheral osteomas are rare, benign, and radioopaque bone lesions. Other hyperplastic and neoplastic bone lesions must be included in the differential diagnosis, and the association of such lesions with Gardner's syndrome should always be taken into consideration.

Source of funding

None declared

Conflict of interest

None declared

References

- de França TR, Gueiros LA, de Castro JF, Catunda I, Leão JC, da Cruz Perez DE. Solitary peripheral osteomas of the jaws. *Imaging Sci Dent* 2012;42(2):99-103.
- Han SH, Kwon H, Jung SN. Peripheral osteoma on the buccal aspect of mandible angle: a review of radiopaque masses and differential diagnosis. *J Craniofac Surg* 2013;24(3):1842-1844.
- Shekya H. Peripheral osteoma of the mandible. *J Clin Imaging Sci* 2011;1:56. Available from: <http://www.clinicalimagingscience.org/text.asp?2011/1/1/56/90483>
- Longo F, Califano L, De Maria G, Ciccarelli R. Solitary osteoma of the mandibular ramus: report of a case. *J Oral Maxillofac Surg* 2001;59(6):698-700.
- Shanavas M, Chatra L, Shenai P, Veena K, Rao P, Prabhu R. Multiple peripheral osteomas of forehead: Report of a rare case. *Ann Med Health Sci Res* 2013;3(1):105-107.
- Sayan NB, Uçok C, Karasu HA, Günhan O. Peripheral osteoma of the oral and maxillofacial region: a study of 35 new cases. *J Oral Maxillofac Surg* 2002;60(11):1299-1301.
- Cutilli BJ, Quinn PD. Traumatically induced peripheral osteoma. Report of a case. *Oral Surg Oral Med Oral Pathol* 1992;73(6):667-669.
- Kaplan I, Nicolaou Z, Hatuel D, Calderon S. Solitary central osteoma of the jaws: a diagnostic dilemma. *Oral Surg Oral Med Oral Pathol Oral Radiol Endod* 2008;106(3):22-29.
- Durighetto AF Jr, de Moraes Ramos FM, da Rocha MA, da Cruz Perez DE. Peripheral osteoma of the maxilla: report of a case. *Dentomaxillofac Radiol* 2007;36(5):308-310.
- Kaplan I, Calderon S, Buchner A. Peripheral osteoma of the mandible: a study of 10 new cases and analysis of the literature. *J Oral Maxillofac Surg* 1994;52(5):467-470.
- Wanyura H, Kamiński A, Stopa Z. Treatment of osteomas located between the anterior cranial base and the face. *J Craniomaxillofac Surg* 2005;33(4):267-275.
- Johann AC, de Freitas JB, de Aguiar MC, de Araújo NS, Mesquita RA. Peripheral osteoma of the mandible: case report and review of the literature. *J Craniomaxillofac Surg* 2005;33(4):276-281.
- Kashima K, Rahman OI, Sakoda S, Shiba R. Unusual peripheral osteoma of the mandible: report of 2 cases. *J Oral Maxillofac Surg* 2000;58(8):911-913.
- Kerckhaert A, Wolvius E, van der Wal K, Oosterhuis JW. Giant osteoma of the mandible: case report. *J Craniomaxillofac Surg* 2005;33(4):282-285.
- Aghabeigi B, Evans AW, Crean SJ, Hopper C. Simultaneous repair of an orbital floor fracture and removal of an ethmoid osteoma: case report and review of the literature. *Int J Oral Maxillofac Surg* 2003;32(1):94-96.
- Chandra J, Prasad BR, Veena KM. Osteoma of the frontal bone: a case report. *J Clin Diagn Res* 2009;3:1426-1430.
- Neville BW, Damm DD, Allen CM, Bouquot JE. *Oral & maxillofacial pathology*. 2nd ed., Philadelphia: W. B. Saunders Co, 2002, p.567
- Payne M, Anderson JA, Cook J. Gardner's syndrome - a case report. *Br Dent J* 2002;193(7): 383-384.

Corresponding Author:

Mustafa GÜMÜŞOK

Department of Dentomaxillofacial Radiology

Faculty of Dentistry Gazi University

Ankara/Turkey

Phone: 0532 595 51 57

e-mail: mustafagumusok@hotmail.com