

GLANDULAR ODONTOGENIC CYST MIMICKING DENTIGEROUS CYST: A CASE REPORT

Dentijeröz Kisti Taklit Eden Glandüler Odontojenik Kist: Olgu Sunumu

Fatih ASUTAY¹, Ahmet H. ACAR¹, Ümit YOLCU¹, Neşe KARADAĞ², Orhan GEÇÖR¹

Makale Gönderilme Tarihi: 01/11/2013

Makale Kabul Tarihi: 20/01/2014

ABSTRACT

Glandular odontogenic cyst is a rarely seen lesion and because of non-specific clinical and radiologic image, differential diagnosis is difficult. Therefore, it requires careful treatment and follow-up due to the aggressive nature. This type of unusual cyst's diagnosis, treatment, and one case report was presented.

Keywords: *Glandular odontogenic cyst, dentigerous cyst*

ÖZ

Glandüler odontojenik kistler, ender görülen ve karakteristik olmayan klinik ve radyolojik görüntüsü nedeniyle ayırıcı tanısı zor olan lezyonlardır. Bu sebeple, dikkatli tedavi edilmesi ve agresif doğasından dolayı uzun dönemli takibi gerekmektedir. Nadir görülen bu kistin teşhis ve tedavi yaklaşımları ile bir olgu raporu sunulmuştur.

Anahtar kelimeler: *Glandüler odontojenik kist, dentijeröz kist*

¹ İnönü University Faculty of Dentistry Department of Oral and Maxillofacial Surgery

² İnönü University, Faculty of Medicine, Department of Pathology

Introduction

Glandular odontogenic cyst (GOC) is a rare developmental cyst of the jaw that is suggested to originate from the remnants of the dental lamina. This cyst was reported for the first time in 1987 by Padayachee and Van Wyk as a sialo-odontogenic cyst, and was described as a glandular odontogenic cyst by Gardner et al in 1988 (1, 2). In 1992, the World Health Organization classified the lesion as a developmental odontogenic epithelial cyst and adopted GOC as the preferred term (3).

Although GOCs may be asymptomatic, they may also lead to pain, swelling, and tooth displacement (4, 5). Radiographically, the lesions appear as well-circumscribed unilocular or multilocular areas causing expansion, erosion, thinning and perforation (3).

Histological examinations support a dental lamina remnant origin for this lesion, with microscopic examinations showing a cystic cavity lined by non-keratinized, stratified, squamous epithelium, localized plaque-like thickenings of the epithelium and numerous mucous-secreting cells in the surface layer of the epithelium. Histopathologically, the superficial layer of the GOC resembles the botryoid odontogenic cyst and low-grade central mucoepidermoid carcinoma. Moreover, ameloblastoma, central giant-cell granuloma, odontogenic myxoma, BOC, and odontogenic keratocyst are radiographically similar to GOC, differential diagnosis more difficult for these lesions (3). Thus, the diagnosis of GOCs can be challenging because of their rare occurrence and the lack of distinctive diagnostic criteria (3, 5).

The treatment options for GOC vary and include marsupialization, cryotherapy,

curettage and enucleation. Some authors recommend radical solutions like marginal resection because the recurrence rates are high (6, 7).

In this article, we report a rare case of this cyst with clinical, radiological, histological and treatment aspects.

Clinical Report

A 38-years-old Caucasian woman was referred to the Oral and Maxillofacial Surgery Department of İnönü University Faculty of Dentistry with swelling at the palate mucosa last months. She experienced mild pain at the first clinical examination. Palatal expansion extending from the upper right central to the upper left first premolar was observed. The labial and palatal overlying mucosae were normal. She had no notable medical history.

The right central and left first premolar teeth responded to the vitality test with the electric pulp tester but the right central and right lateral teeth did not respond; thus, endodontic treatment was performed on the right central and right lateral teeth before surgery.

Panoramic and periapical radiographs were taken after the oral examination (Figure 1, Figure 2D). She had already undergone computed tomography (CT) radiograph. The radiological examinations revealed that a unilocular radiolucency of approximately as 12.3 × 18 mm in size surrounded the crown of the impacted left canine. The roots of the right central and right lateral teeth exhibited resorption. The lesion had caused destruction of the alveolar bone from both the palatal and labial aspects (Figure 2A, 2B, 2C).

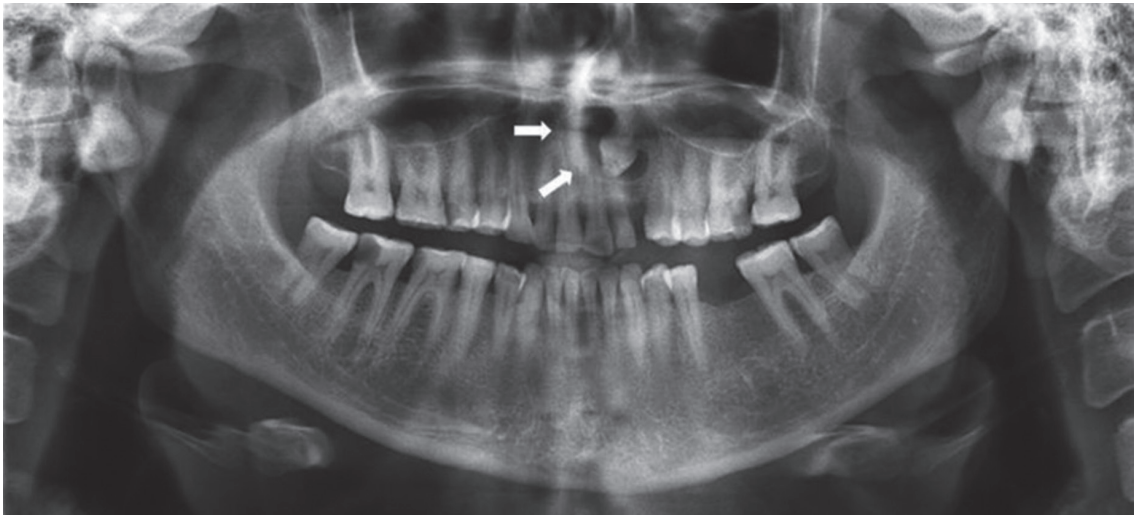


Figure 1. Panoramic radiograph before surgery.

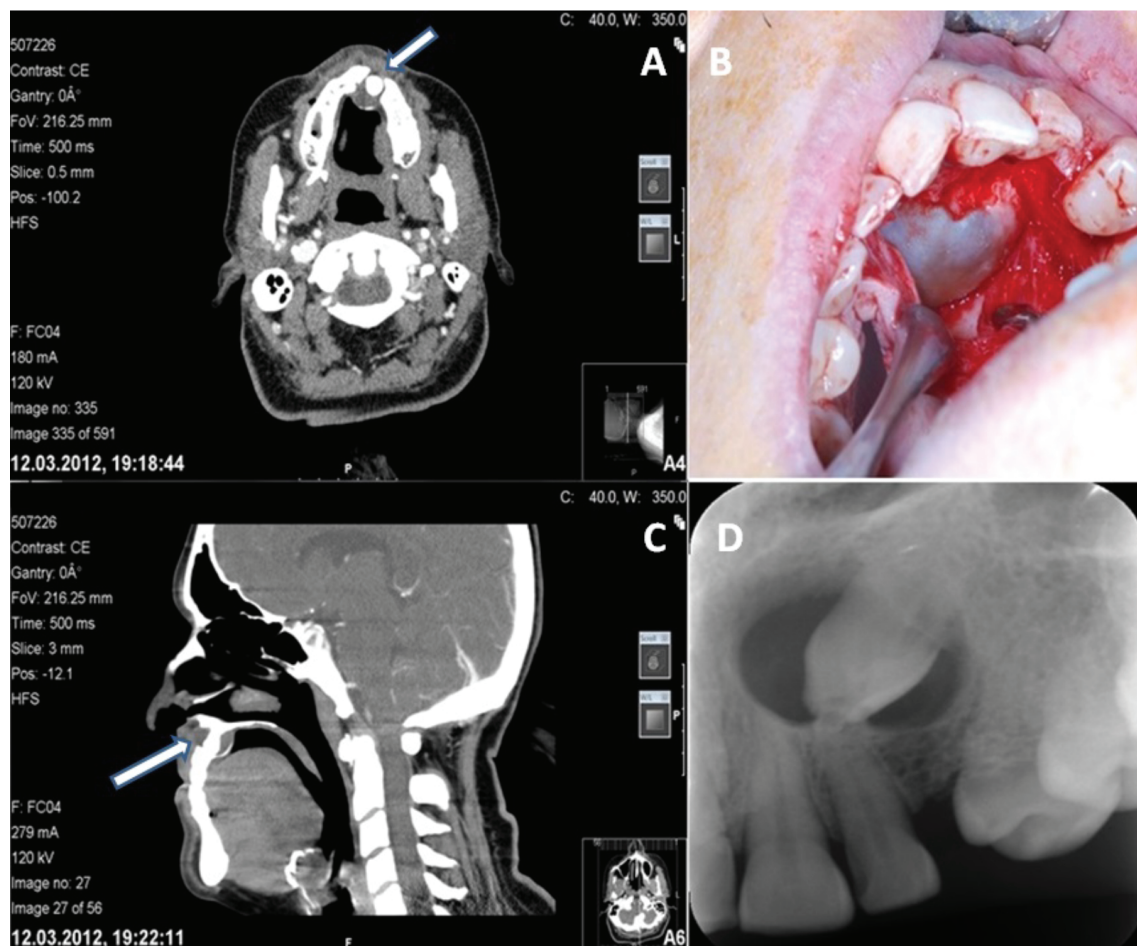


Figure 2. A: Transversal view of CT before surgery, B: Sagittal view of CT before surgery, C: Intraoperative view, D: Periapical radiograph before surgery.

A mucoperiosteal flap was raised between the right first premolar and left first molar with a palatal approach. The lesion was enucleated and the impacted canine was extracted under local anesthesia. The cystic material was sent to the Pathology Department of Inonu School of Medicine for pathological examination. During the 17 months follow-up period, there is no sign of recurrence at the surgery area (Figure 3).

Histopathological examination revealed a cystic lesion lined with stratified squamous epithelium that exhibited pseudoglandular spaces. Histochemical staining with periodic acid-Schiff (PAS) + Alcianblue (pH2.5) revealed mucinous material in the glandular spaces and the cytoplasmic areas of single cells. The histopathological diagnosis was reported as GOC (Figure 4A, 4B, 4C).

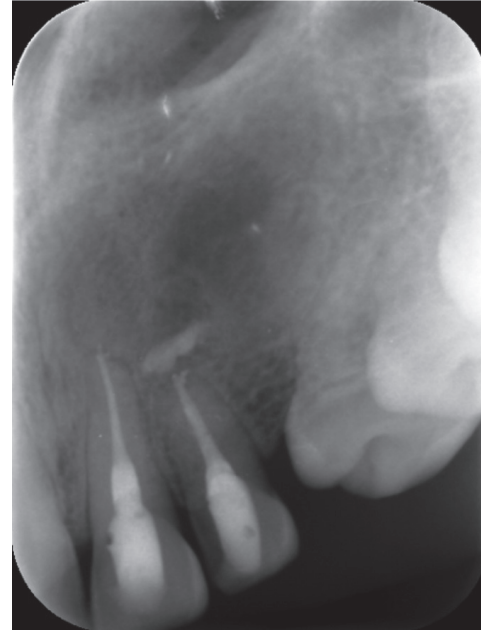


Figure 3. Periapical radiograph 17 months after surgery.

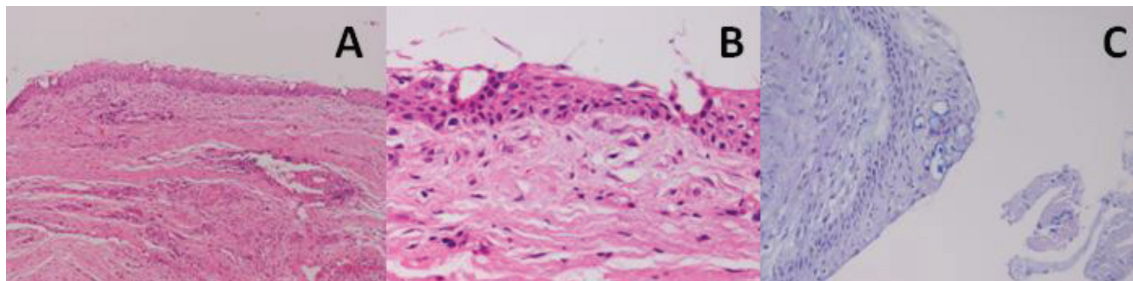


Figure 4. Cystic lesion lined with stratified squamous epithelium (A; HEx100, B; HEx200). Histochemical staining with PAS+Alcian Blue showed mucinous material (C; PAS+ABx200).

Discussion

Previously, the cyst described here in was called “sialo-odontogenic cyst.” However, Gardner et al. (2) called the lesion a “glandular odontogenic cyst” because the cyst wall epithelium contained only elements with no evidence of salivary tissue involvement. This term was later adopted by the World Health Organization (4).

To the best of our knowledge, only 114

cases of GOC have been reported in the literature (8). Further, Magnusson et al. (9) observed that this type of cyst accounts for only 0.012% of the cysts that are observed in the oral cavity among the odontogenic cysts. Although the cyst was located in the at the maxilla anterior region in this case, several papers have indicated that the anterior mandible is the most common site of occurrence. GOC has a clear preference for the mandible, with 70% of cases located in the mandible

and 30% in the maxilla (7). GOC is slightly more common in males and occurs primarily in middle-aged patients (10).

Although the origin of GOC remains unclear, various cases of hybrid lesions of GOC and other odontogenic tumors appear to indicate an odontogenic origin. The minimal expression of markers such as epithelial membrane antigen and mammary serine protease inhibitor do not support a sialogenic origin (3, 5).

While the respective occurrences of resorption and tooth displacement are 22% and 24.4%, multilocularity (48%) and cortical expansion (87%) features are higher in these cysts compared to other odontogenic cysts. Further, GOC has a 50% perforation rate (4). Despite these aggressive properties, the cysts are usually asymptomatic.

GOC has no known radiographic pathognomonic features, although a smooth border (95%) that is unilocular (53.8%) or multilocular (46.2%) is commonly observed (4, 5, 7). The lesion size varies from 0.5 to 12 cm in length and 0.5 to 6 cm in width (4). These lesions can become very large; thus, a three-dimensional evaluation is important. CT can be used to determine the localization of the lesion and the features of multilocularity and to provide evidence of perforation.

A diagnosis may be difficult because these lesions lack specific clinical and radiological properties; therefore, the differential diagnosis should be considered carefully.

GOC is radiographically similar to the dentigerous cyst, ameloblastoma, central-giant-cell granuloma, odontogenic myxoma, botryoid odontogenic cyst, and odontogenic keratocyst (3, 4, 7). Especially, even in present case, GOC can be misdiagnosed as a dentigerous cyst because of the clinical features and radiographic view (11).

The treatment of these cysts is a contro-

versial issue. Most of the cases reported in the literature were treated with enucleation and curettage (83.5%). In addition, marsupialization and curettage in conjunction with Carnoy's solution and cryotherapy have been used (7, 12). However, some authors suggest marginal or segmental resection because of the potential for relapse and the aggressive nature of these lesions (7, 13-15).

Many studies have shown that GOC is relatively aggressive and has a high potential for recurrence (16, 17). Some authors have postulated that the cell kinetics in the cyst epithelium is responsible for the tendency of these cysts to recur (18, 19). Increased positivity and decreased hold account for proliferation index and an immunohistochemical evaluation is recommended (3, 5). A post-operative follow-up period is crucial in these cases because the recurrence rate is high (20).

Conclusion

In conclusion, the rarely observed GOC may be missed because its pathology is similar to that of many other conditions. Long-term follow-up is crucial because of the potential for recurrence (21%).

REFERENCES

1. Padayachee A, Van Wyk CW. Two cystic lesions with features of both the botryoidodontogenic cyst and the central mucoepidermoid tumour: sialo-odontogenic cyst? *J Oral Pathol* 1987;16(10):499-504.
2. Gardner DG, Kessler HP, Morency R, Schaffner DL. The glandular odontogenic cyst: an apparent entity. *J Oral Pathol* 1988;17(8):359-66.
3. Boffano P, Cassarino E, Zavattero E, Campisi P, Garzino-Demo P. Surgical

- treatment of glandular odontogenic cysts. *J Craniofac Surg* 2010;21(3):776-80.
4. Stoelinga PJ. The management of aggressive cysts of the jaws. *J Maxillofac Oral Surg* 2012;11(1):2-12.
 5. Manor R, Anavi Y, Kaplan I, Calderon S. Radiological features of glandular odontogenic cyst. *Dentomaxillofac Radiol* 2003;32(2):73-9.
 6. Krishnamurthy A, Sherlin HJ, Ramalingam K, Natesan A, Premkumar P, Ramani P, Chandrasekar T. Glandular odontogenic cyst: report of two cases and review of literature. *Head Neck Pathol* 2009;3(2):153-8.
 7. Kaplan I, Anavi Y, Manor R, Sulkes J, Calderon S. The use of molecular markers as an aid in the diagnosis of glandular odontogenic cyst. *Oral Oncol* 2005;41(9):895-902.
 8. Kasaboglu O, Basal Z, Usubütün A. Glandular odontogenic cyst presenting as a dentigerous cyst: a case report. *J Oral Maxillofac Surg* 2006;64(4):731-3.
 9. Magnusson B, Göransson L, Odesjö B, Gröndahl K, Hirsch JM. Glandular odontogenic cyst. Report of seven cases. *Dentomaxillofac Radiol* 1997;26(1):26-31.
 10. Kaplan I, Anavi Y, Hirshberg A. Glandular odontogenic cyst: a challenge in diagnosis and treatment. *Oral Dis* 2008;14(7):578-81.
 11. Araújo de Moraes HH, José de Holanda Vasconcellos R, de Santana Santos T, Guedes Queiroz LM, Dantas da Silveira ÉJ. Glandular odontogenic cyst: case report and review of diagnostic criteria. *J Craniomaxillofac Surg* 2012;40(2):e46-50.
 12. Prabhat MP, Deshpande P, Gummadapu S, Babburi S, Chintamaneni RL, Sujanamulk B. Dual lesions: a diagnostic dilemma. *Case Rep Dent* 2013;2013:539234. doi: 10.1155/2013/539234
 13. Sittitavornwong S, Koehler JR, Said-Al-Naief N. Glandular odontogenic cyst of the anterior maxilla: case report and review of the literature. *J Oral Maxillofac Surg* 2006;64(4):740-5.
 14. Velez I. Glandular odontogenic cyst. Report of two cases and review of the literature. *N Y State Dent J* 2006;72(1):44-5.
 15. Osny FJ, Azevedo LR, Sant'Ana E, Lara VS. Glandular odontogenic cyst: case report and review of the literature. *Quintessence Int* 2004;35(5):385-9.
 16. Thor A, Warfvinge G, Fernandes R. The course of long-standing glandular odontogenic cyst: marginal resection and reconstruction with particulated bone-graft, platelet-rich plasma, and additional vertical alveolar distraction. *J Oral Maxillofac Surg* 2006;64(7):1121-8.
 17. Shen J, Fan M, Chen X, Wang S, Wang L, Li Y. Glandular odontogenic cyst in China: report of 12 cases and immunohistochemical study. *J Oral Pathol Med* 2006;35(3):175-82.
 18. Tosios KI, Kakarantza-Angelopoulou E, Kapranos N. Immunohistochemical study of bcl-2 protein, Ki-67 antigen and p53 protein in epithelium of glandular odontogenic cysts and dentigerous cysts. *J Oral Pathol Med* 2000;29(3):139-44.
 19. Toida M, Nakashima E, Okumura Y, Tatematsu N. Glandular odontogenic cyst: a case report and literature review. *J Oral Maxillofac Surg* 1994;52(12):1312-6.
 20. Bhatt V, Monaghan A, Brown AM, Rippin JW. Does the glandular odontogenic cyst require aggressive management? *Oral Surg Oral Med Oral Pathol Oral Radiol Endod* 2001;92(3):249-51.

Corresponding Author:**Fatih ASUTAY**

İnönü University

Faculty of Dentistry

Department of Oral and Maxillofacial Surgery

44280 Malatya/Türkiye

e-mail: dt_asutay@hotmail.com